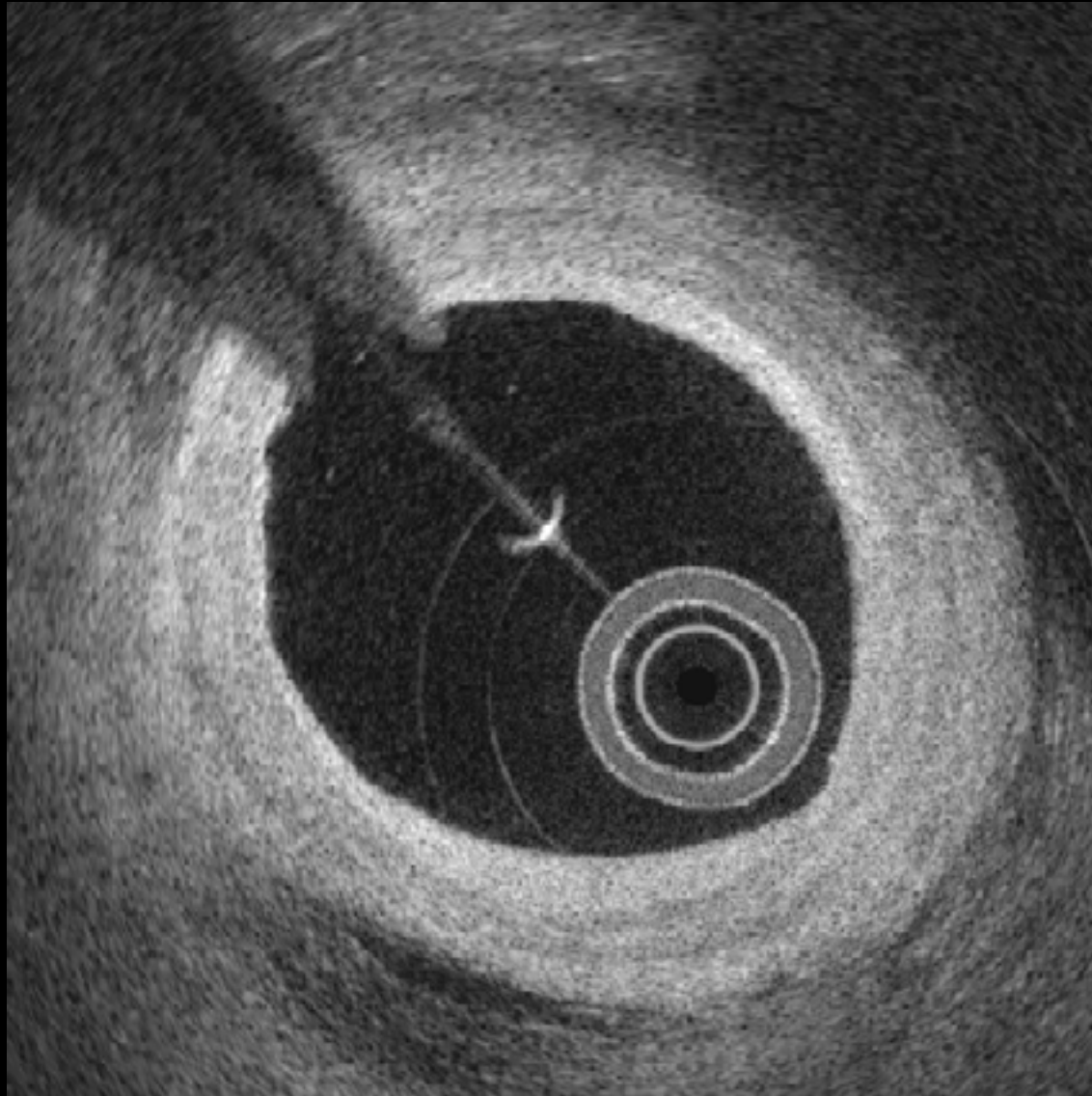
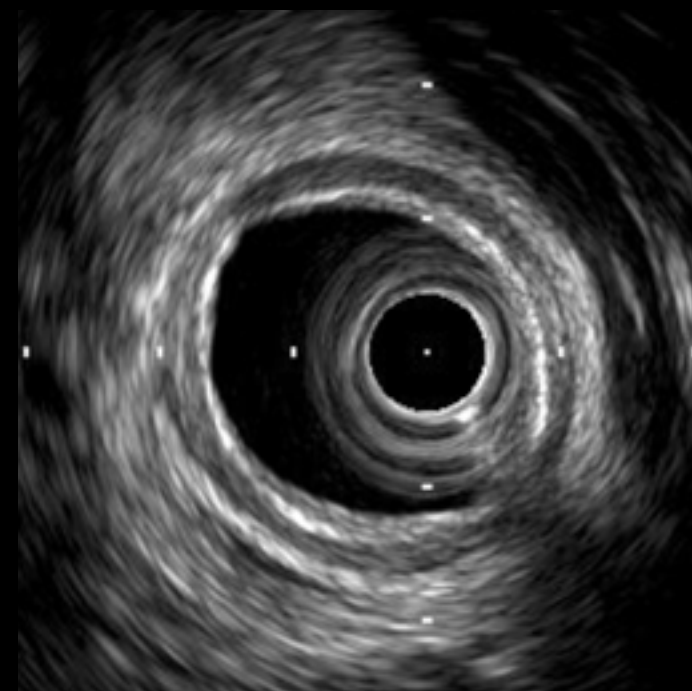
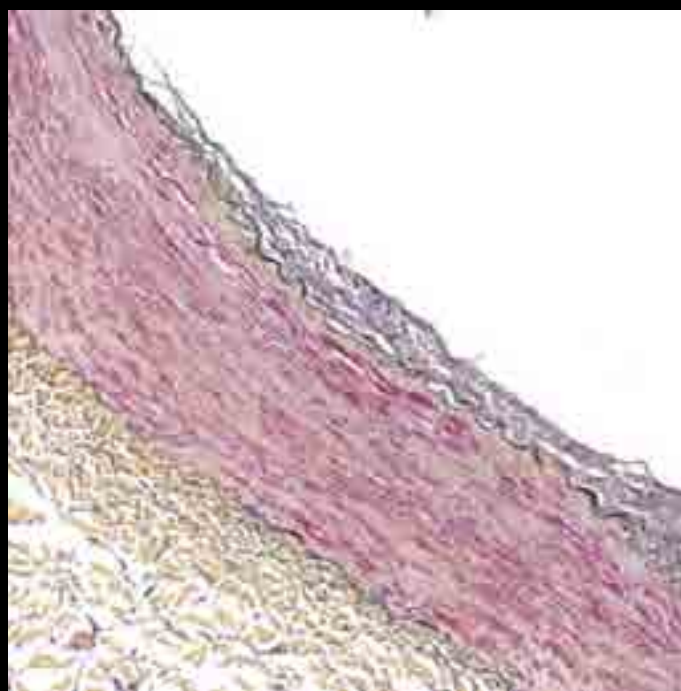
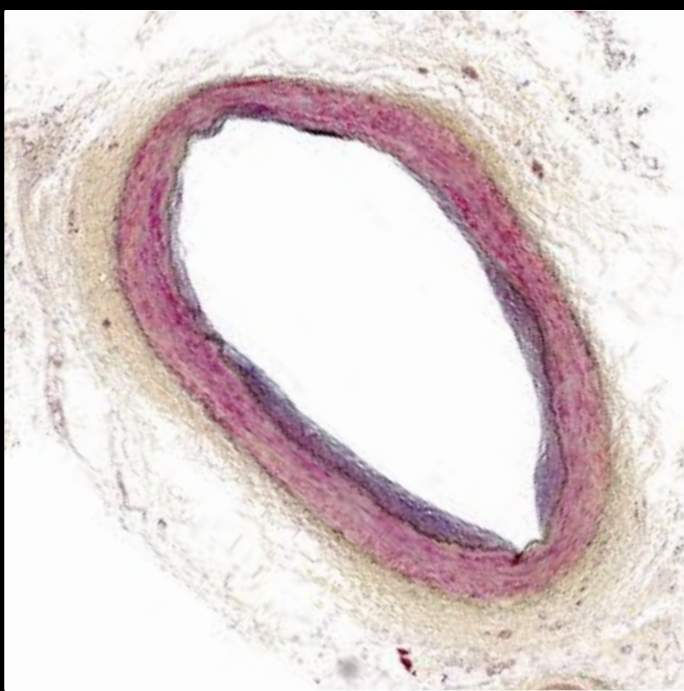
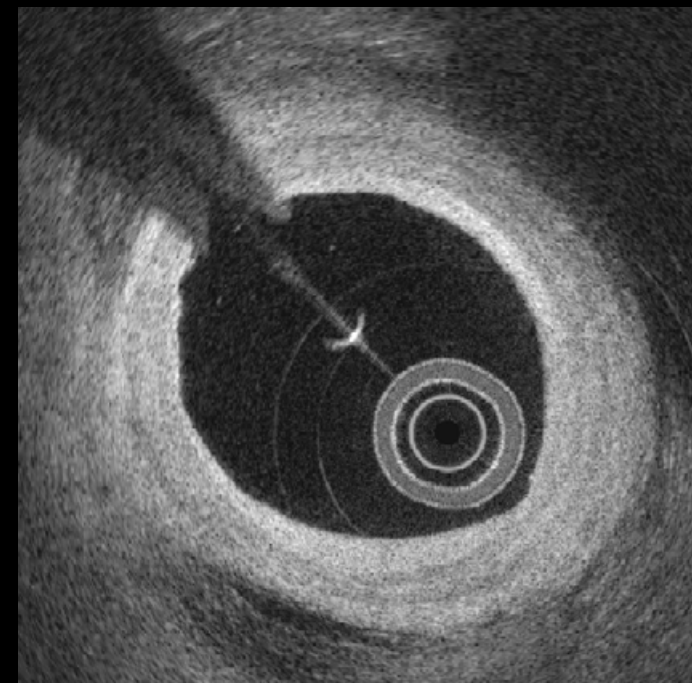
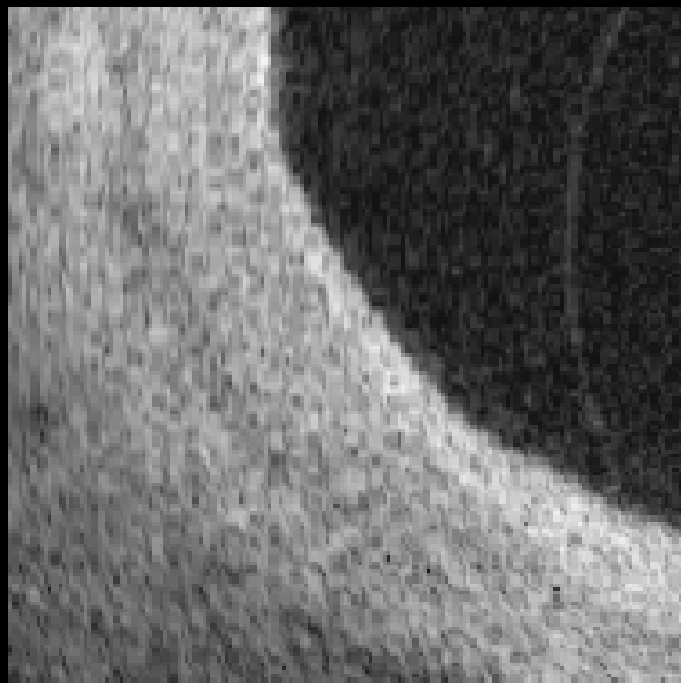
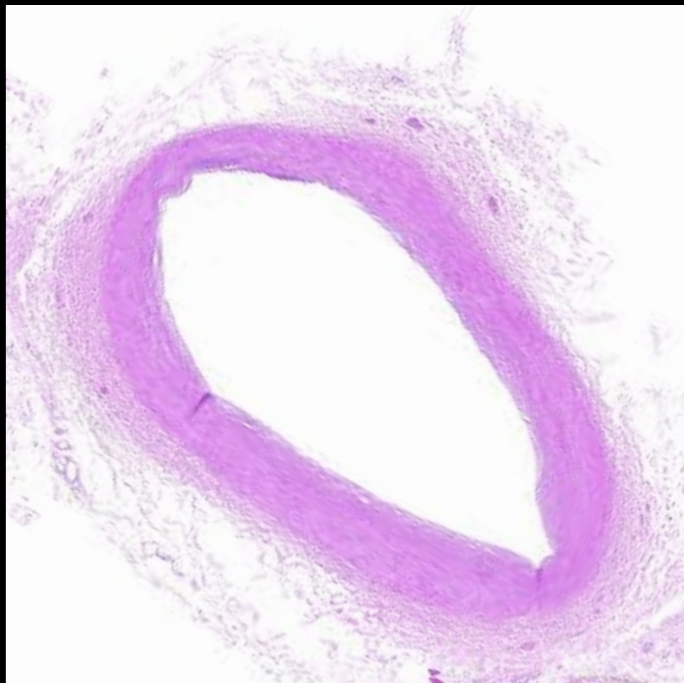


Normal
vessel

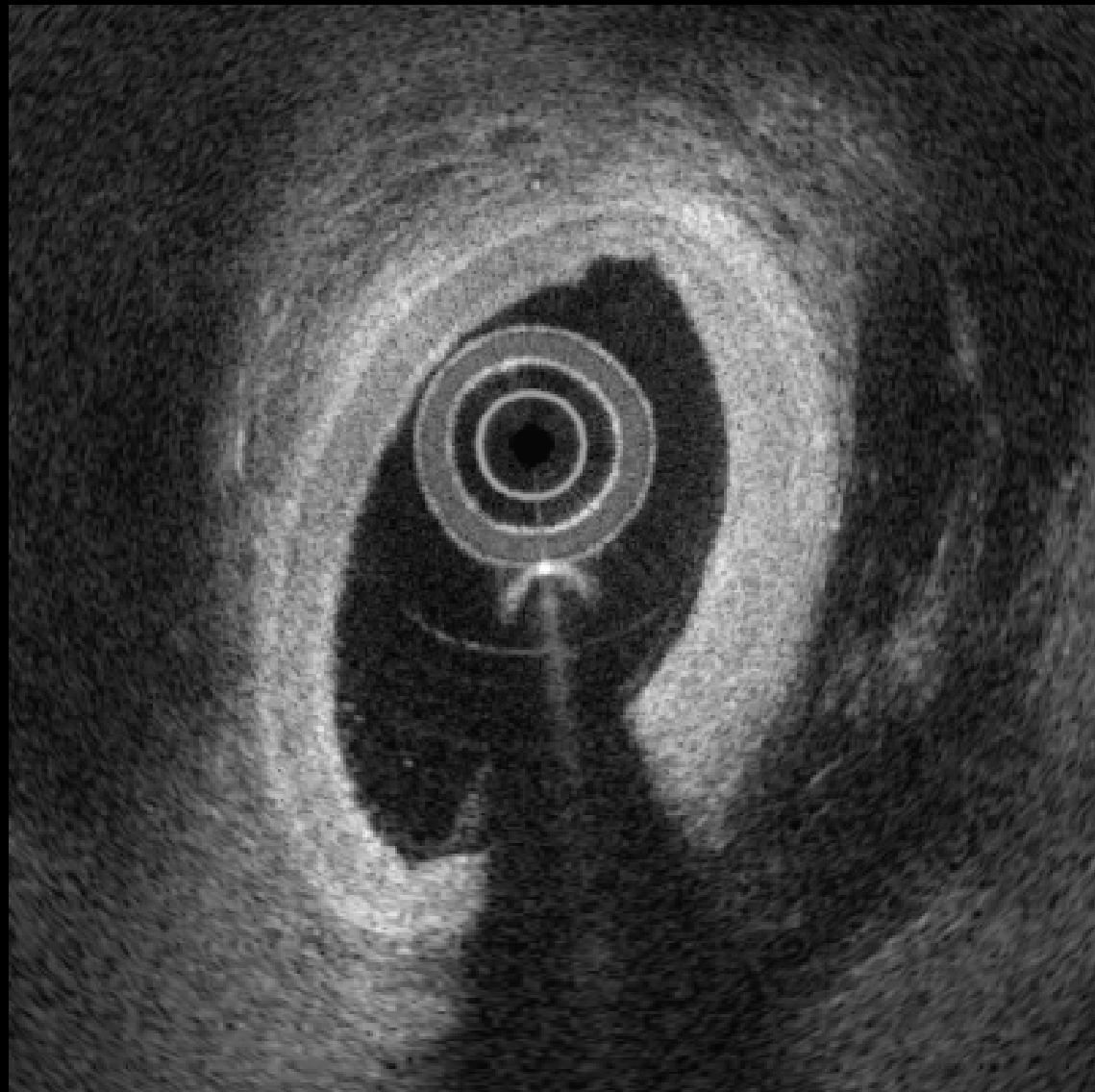
1



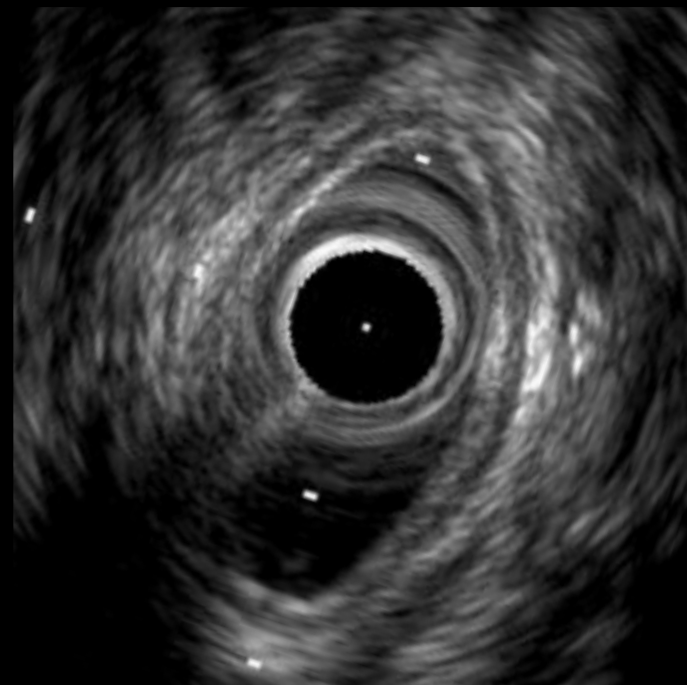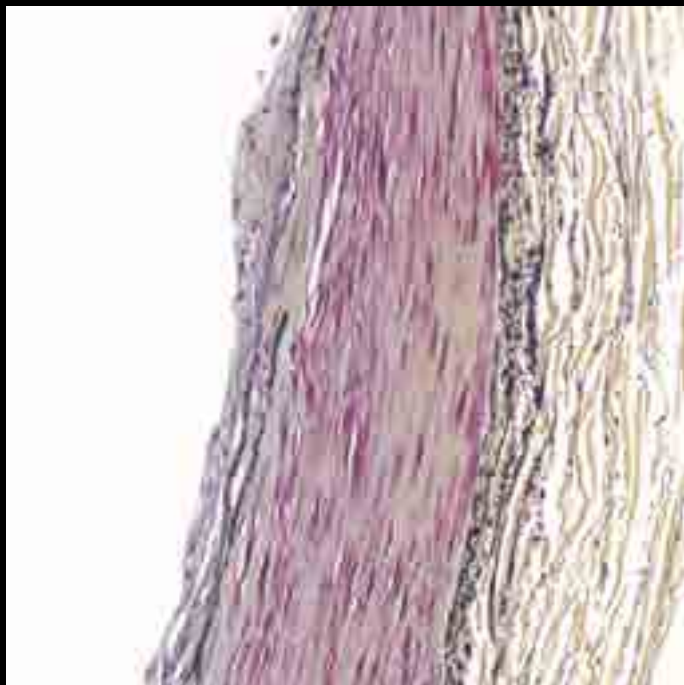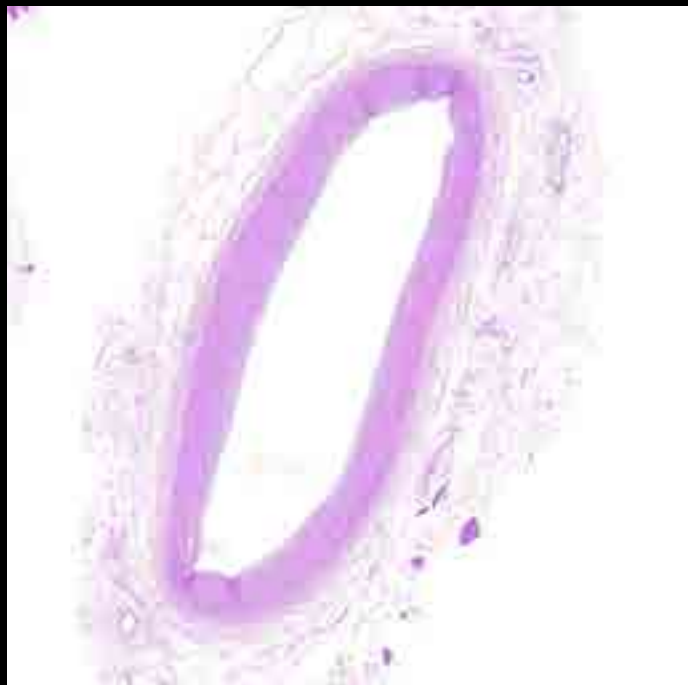
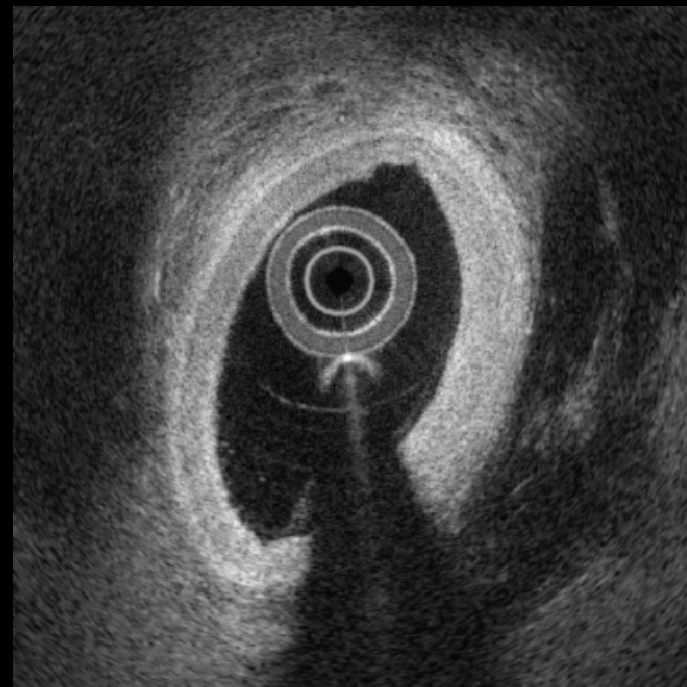
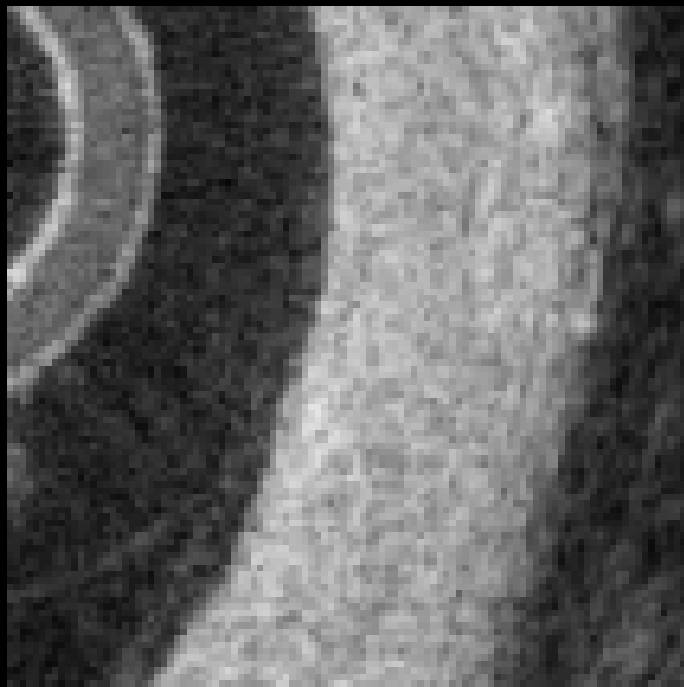
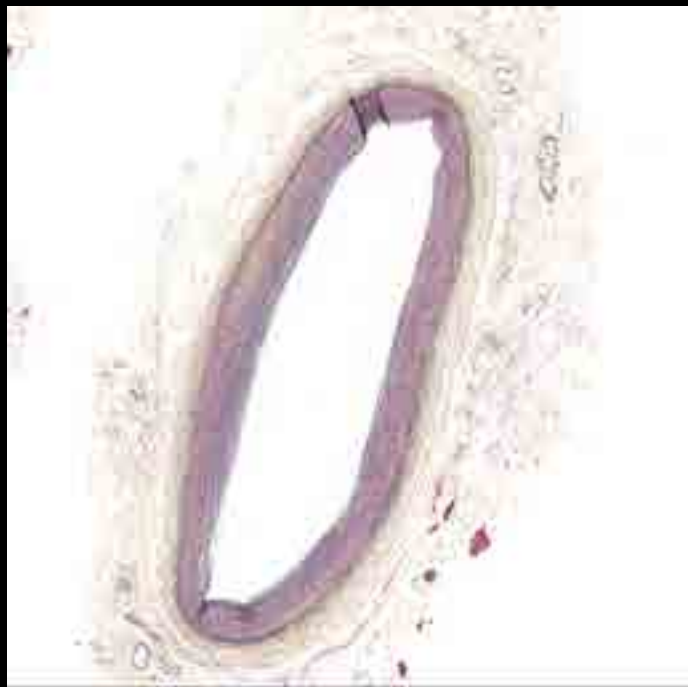
1



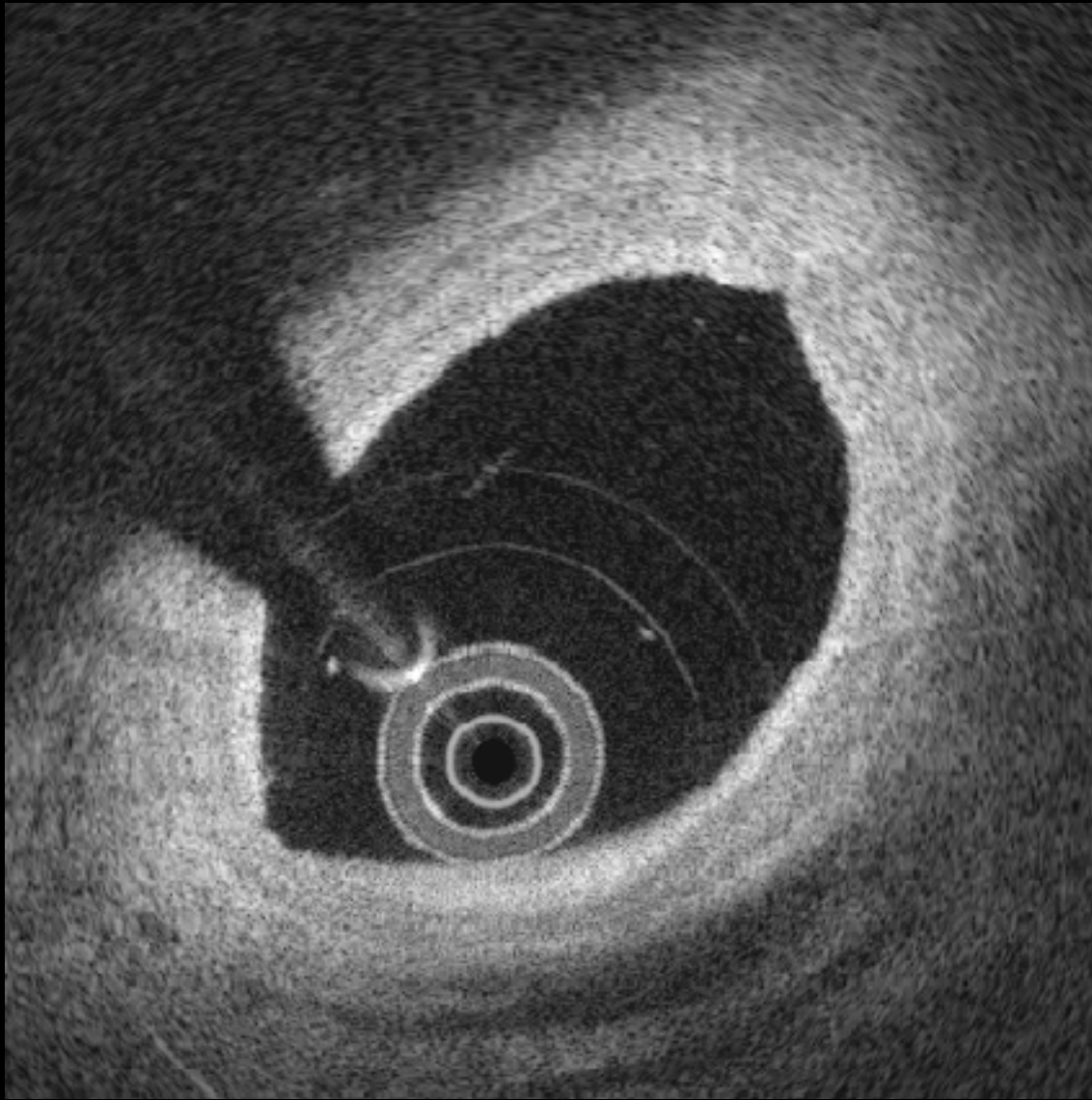
2



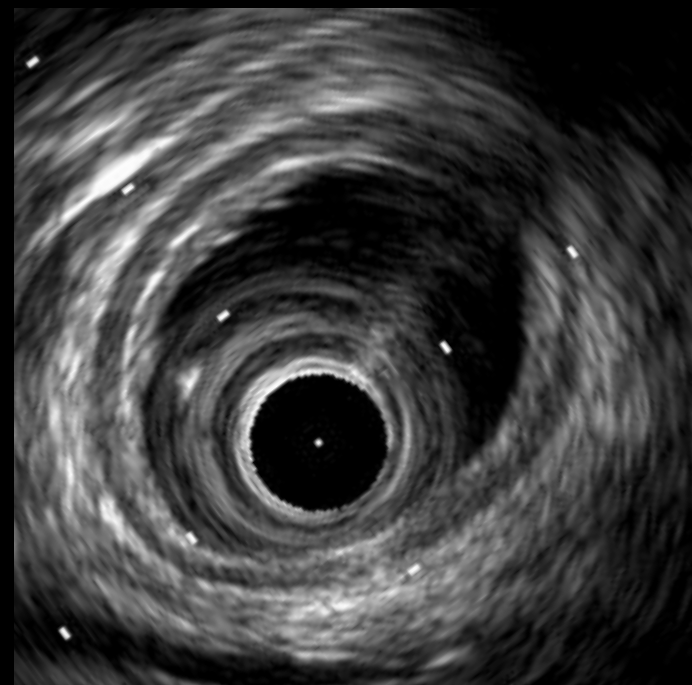
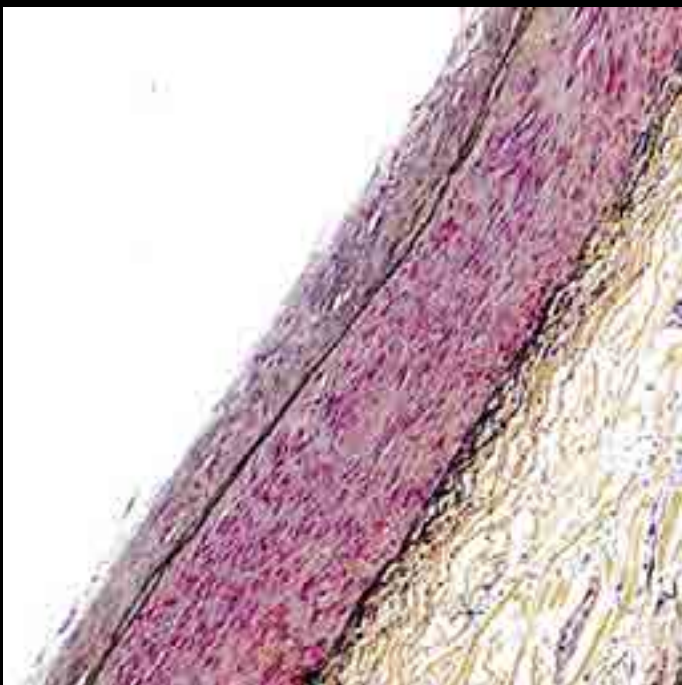
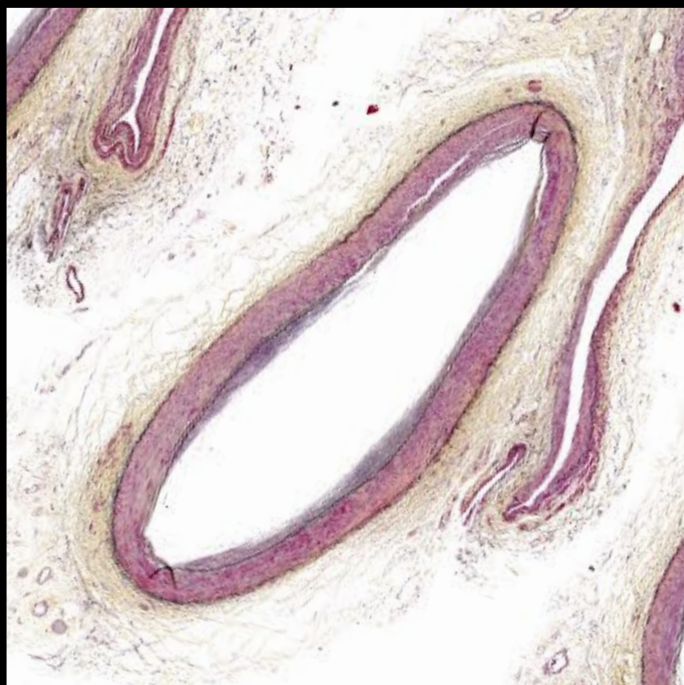
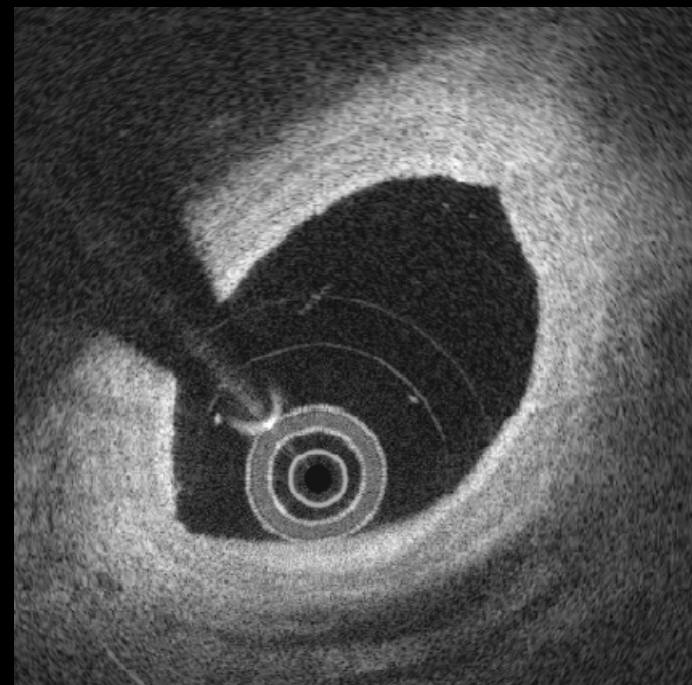
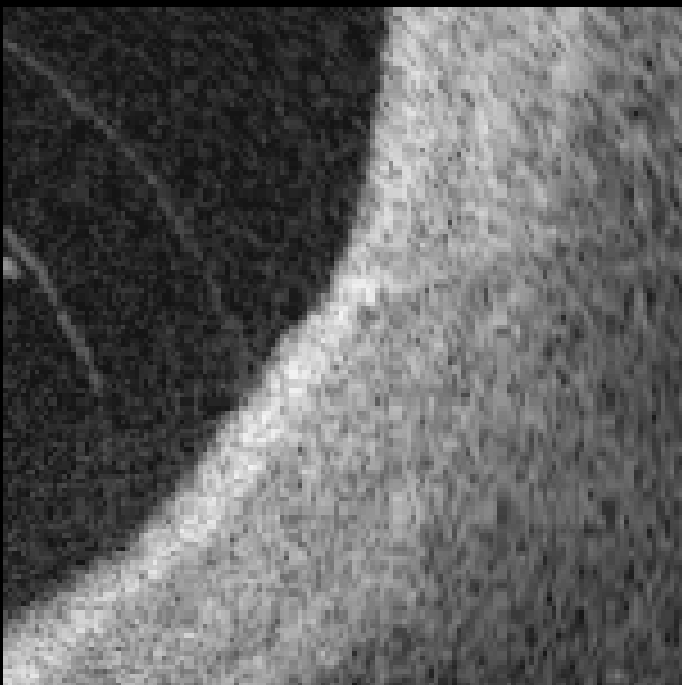
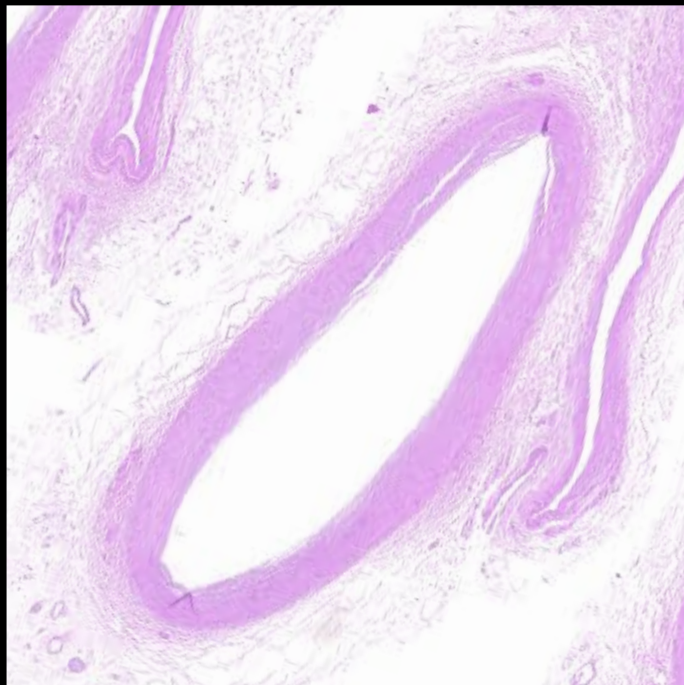
2



3

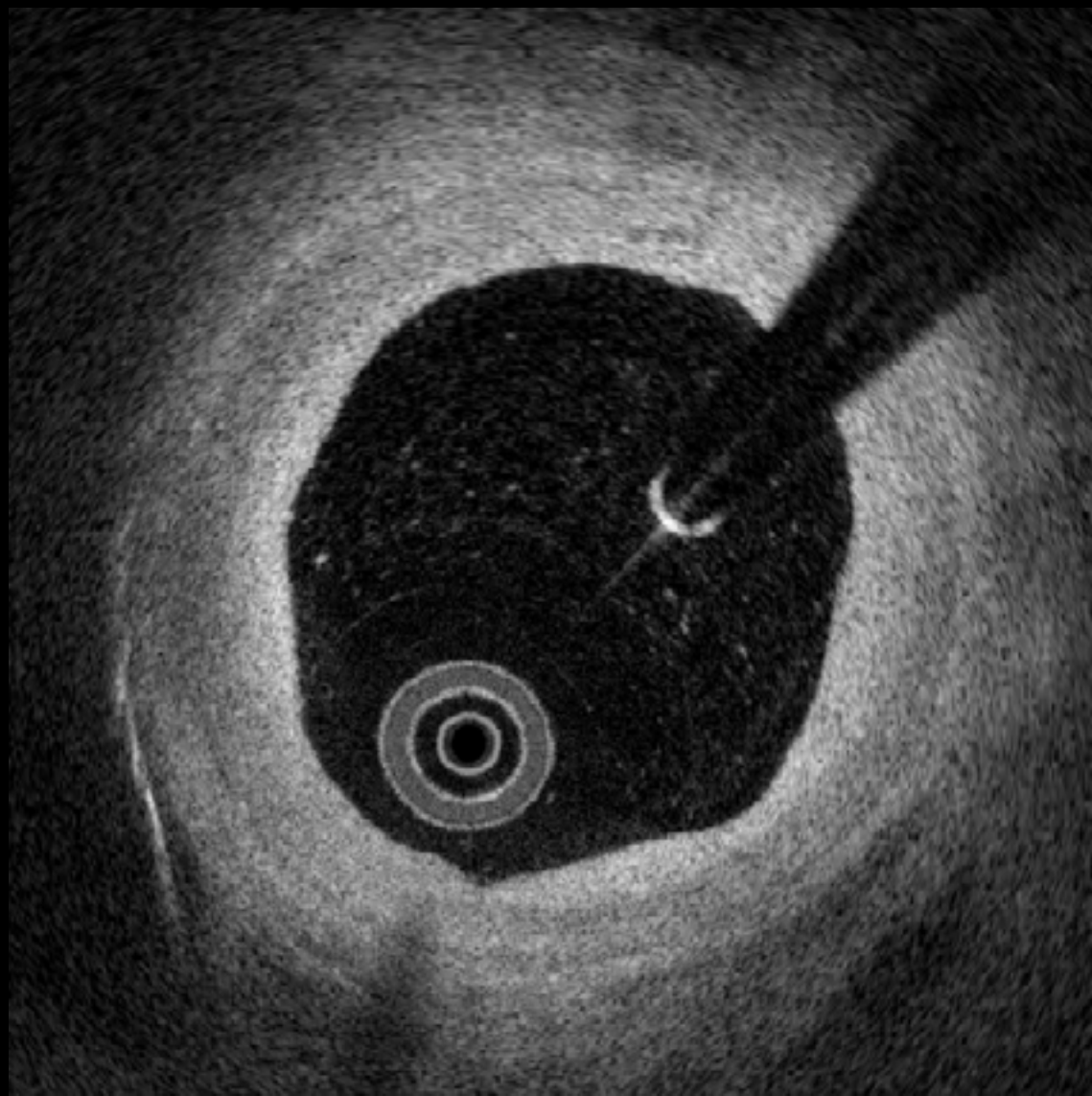


3

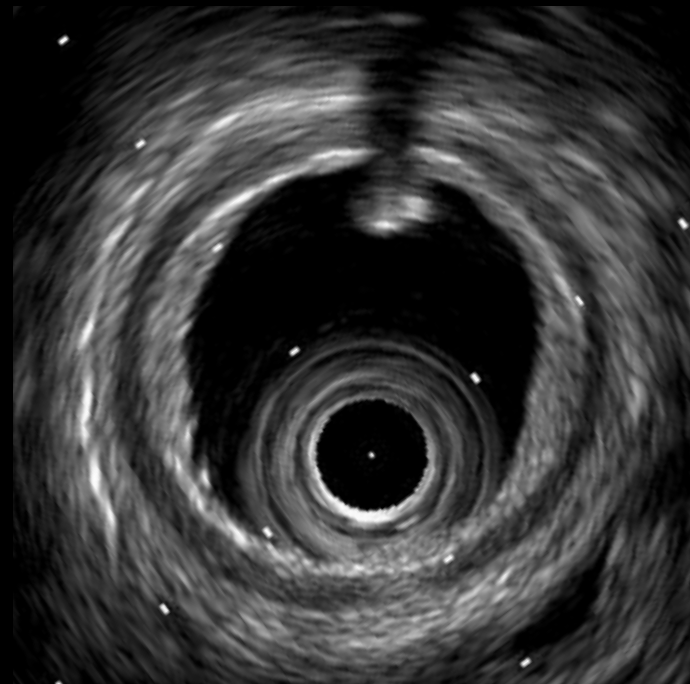
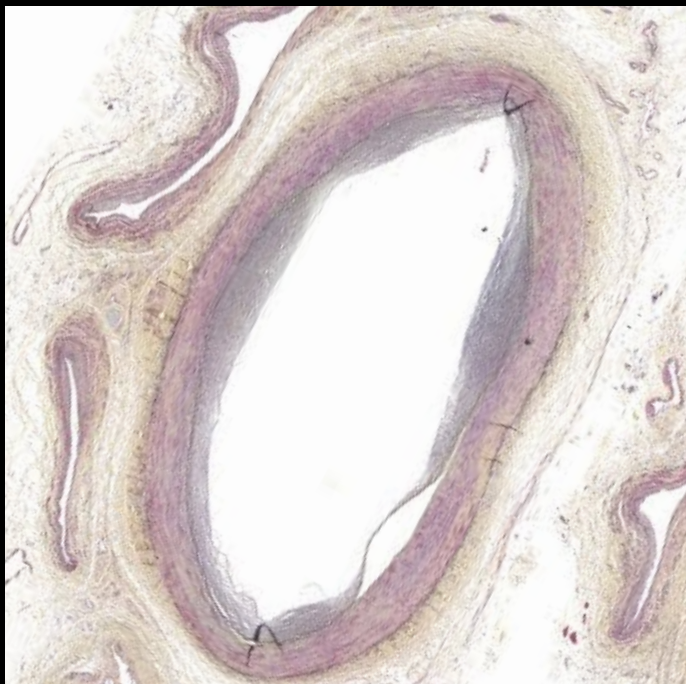
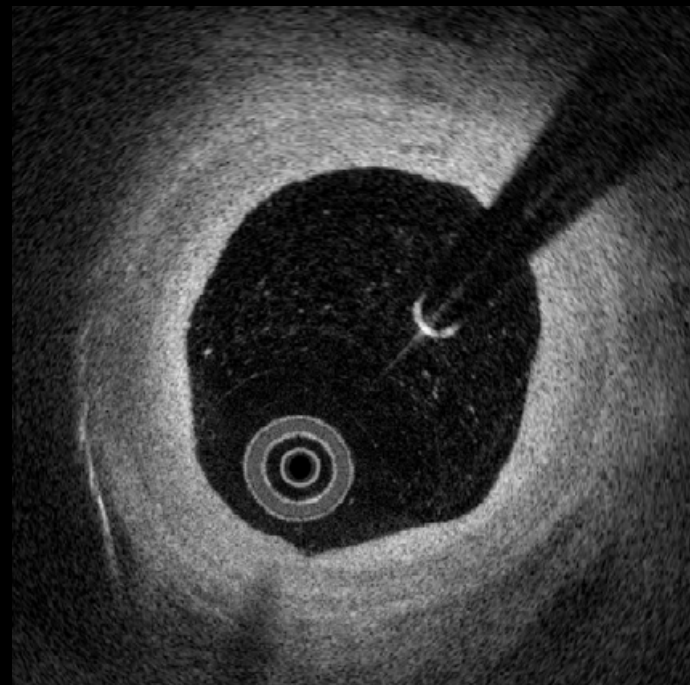
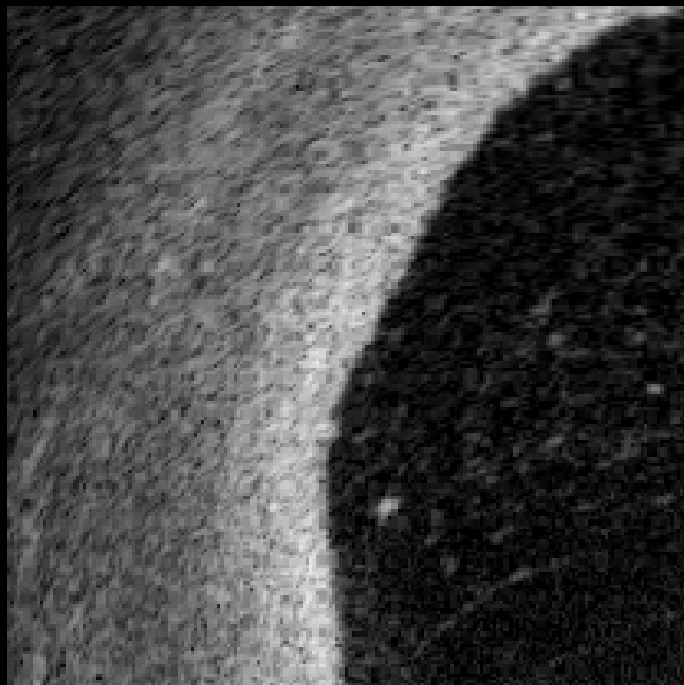
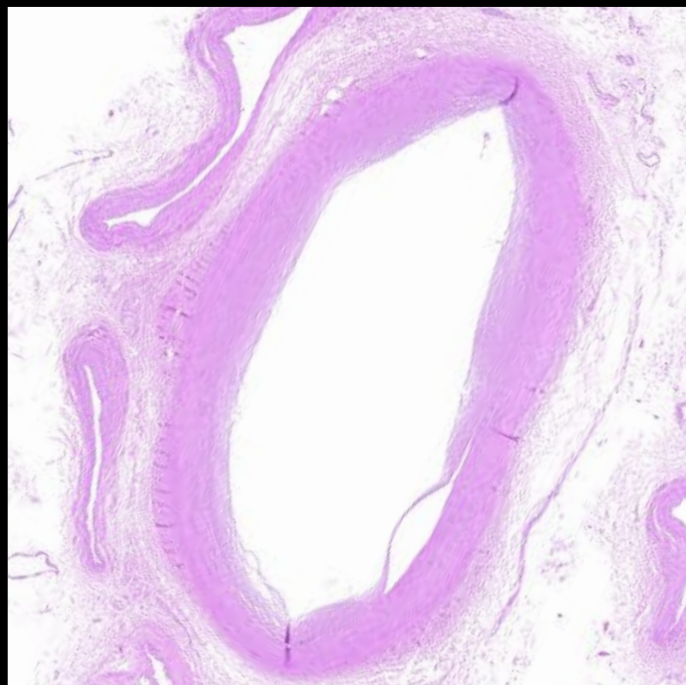


Adaptive
Intimal
Thickening

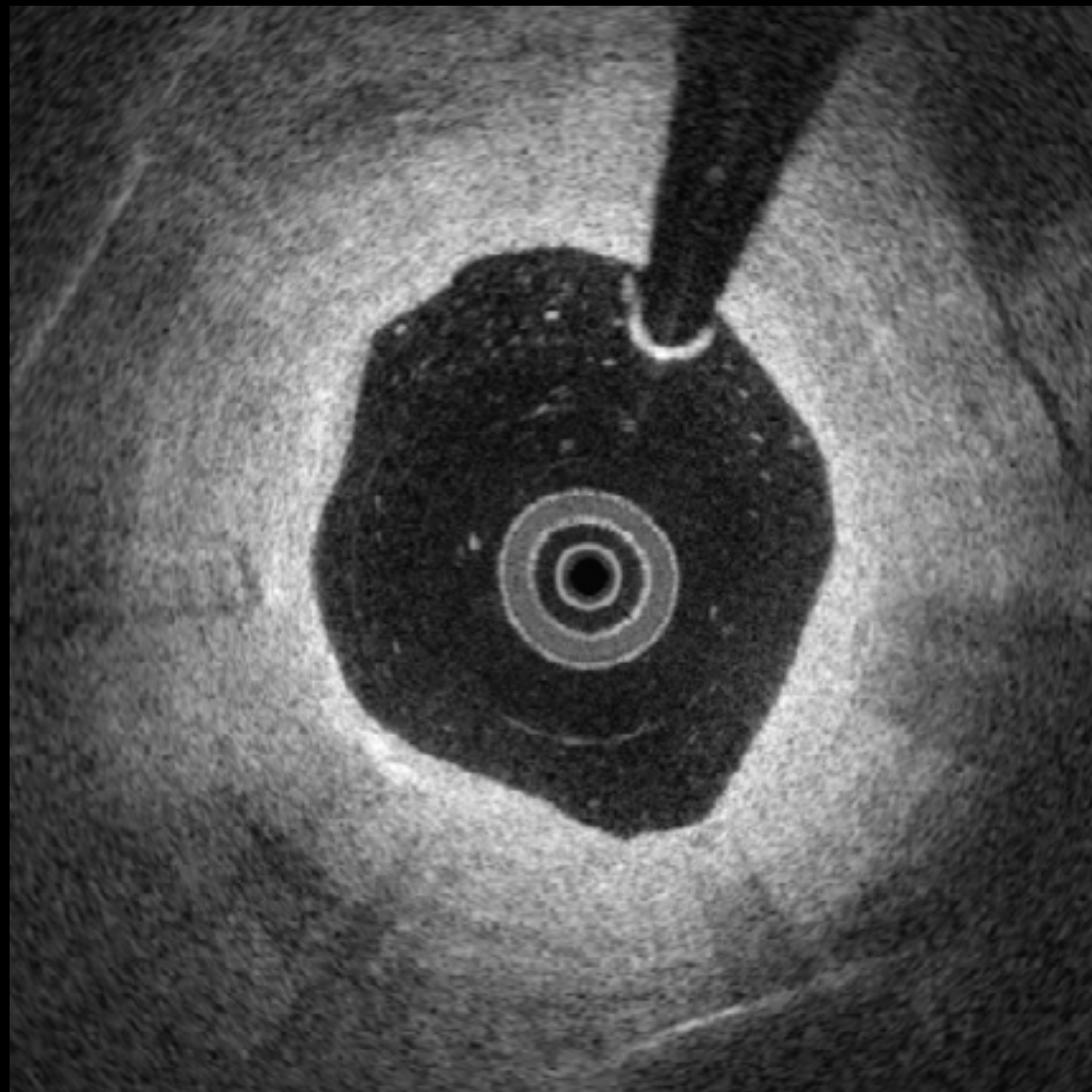
4



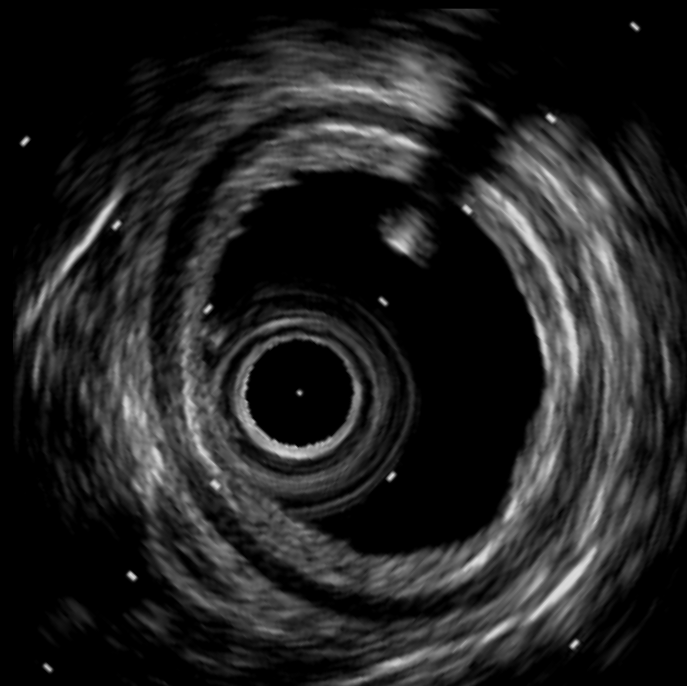
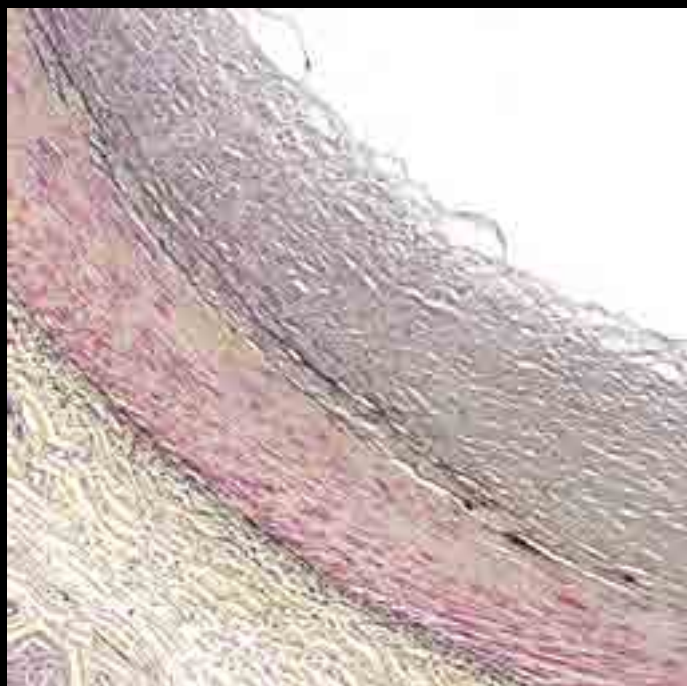
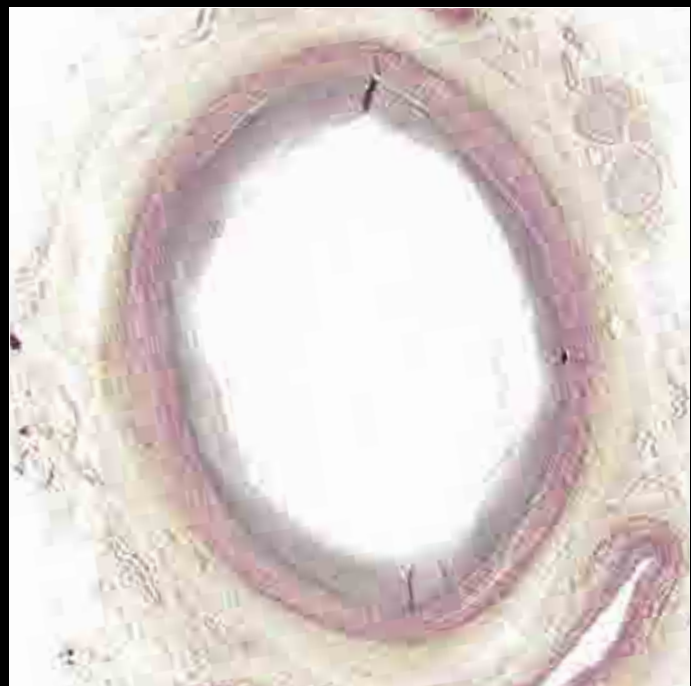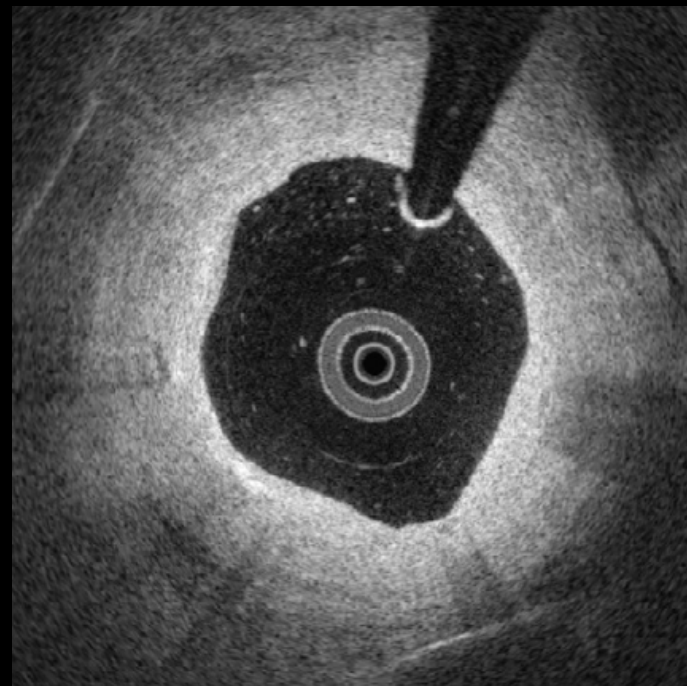
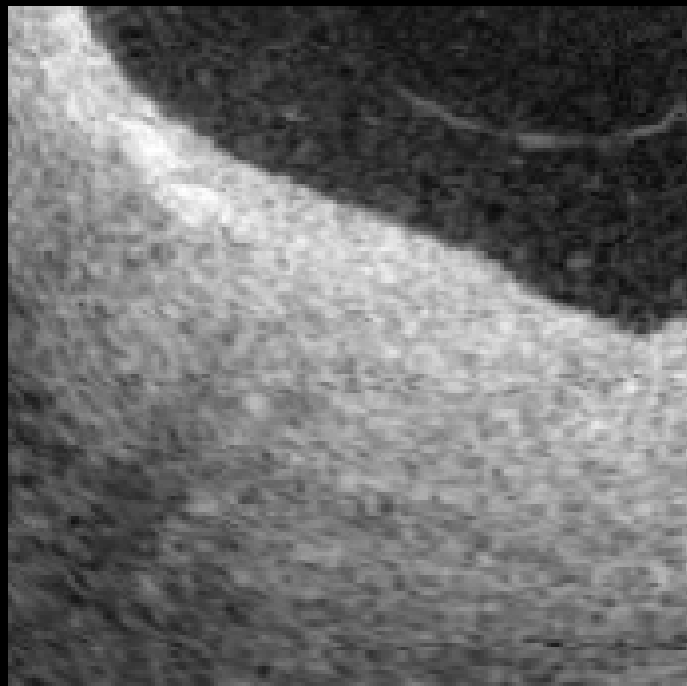
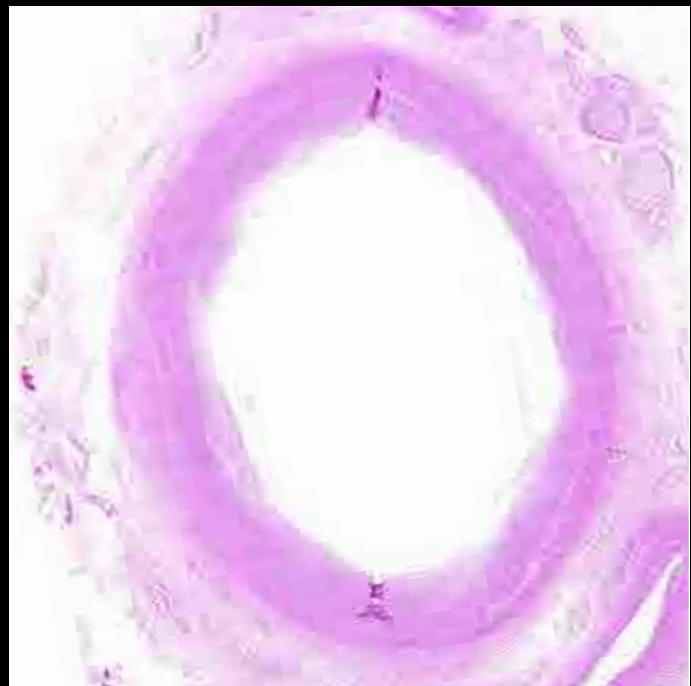4



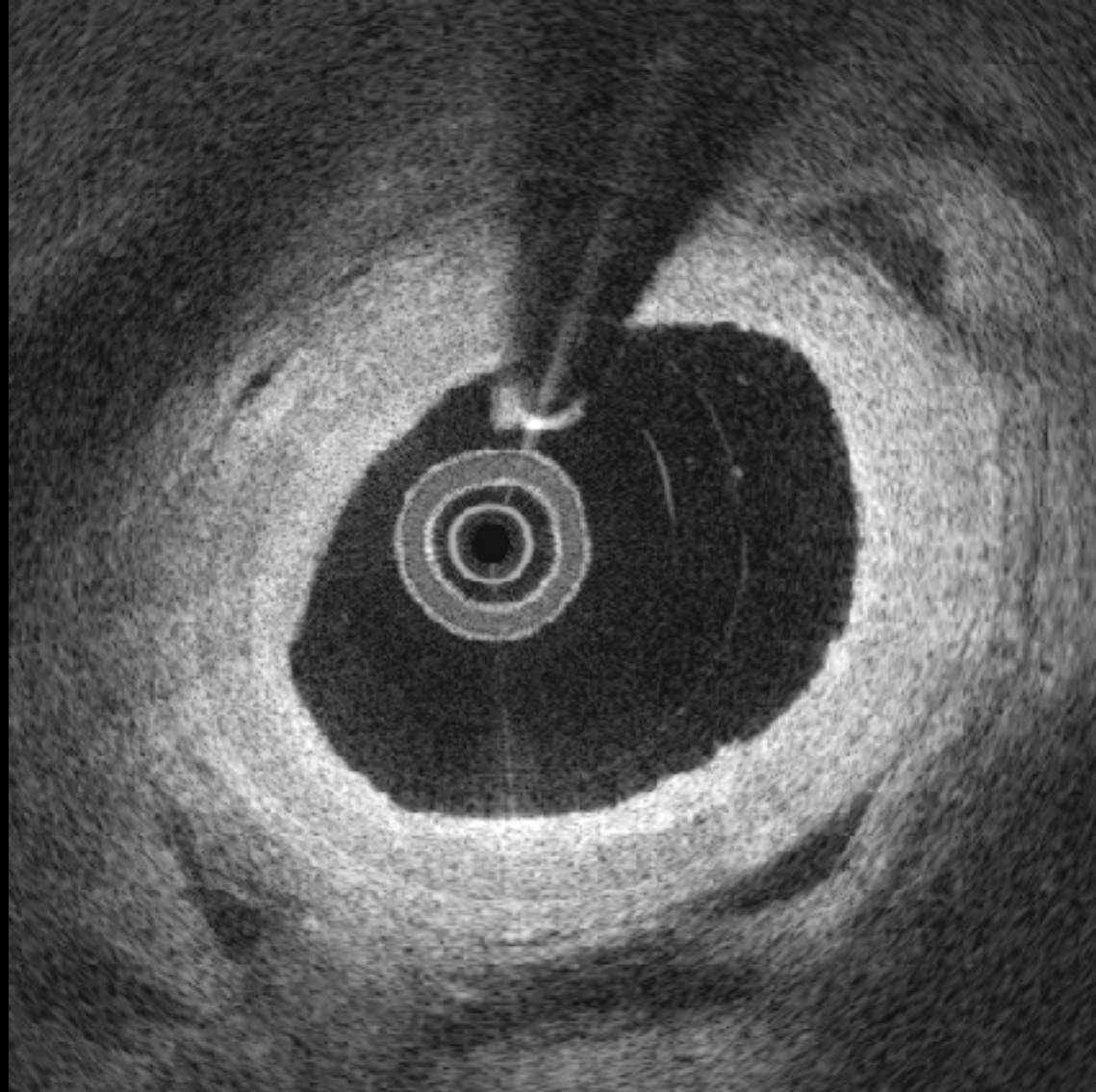
5



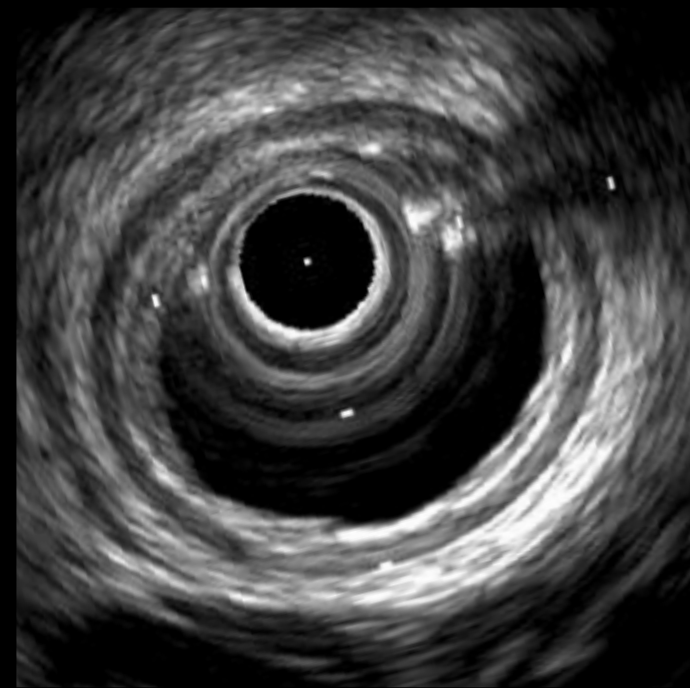
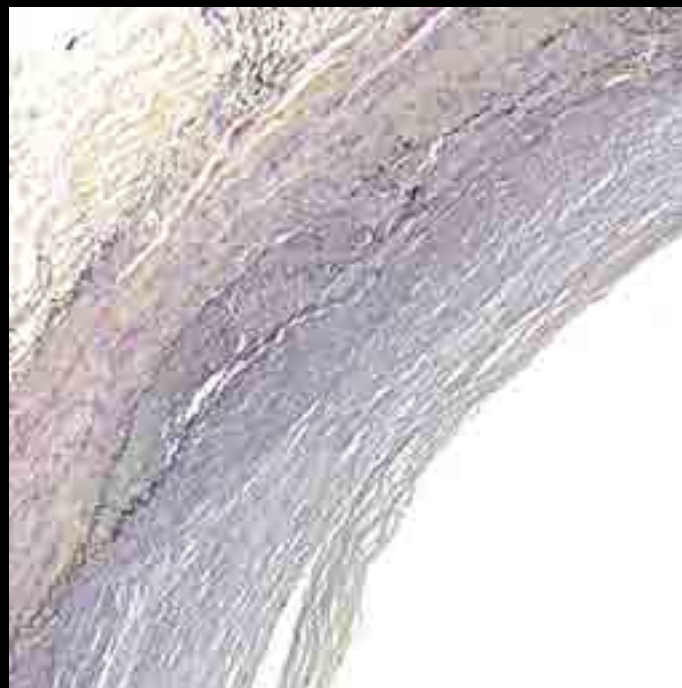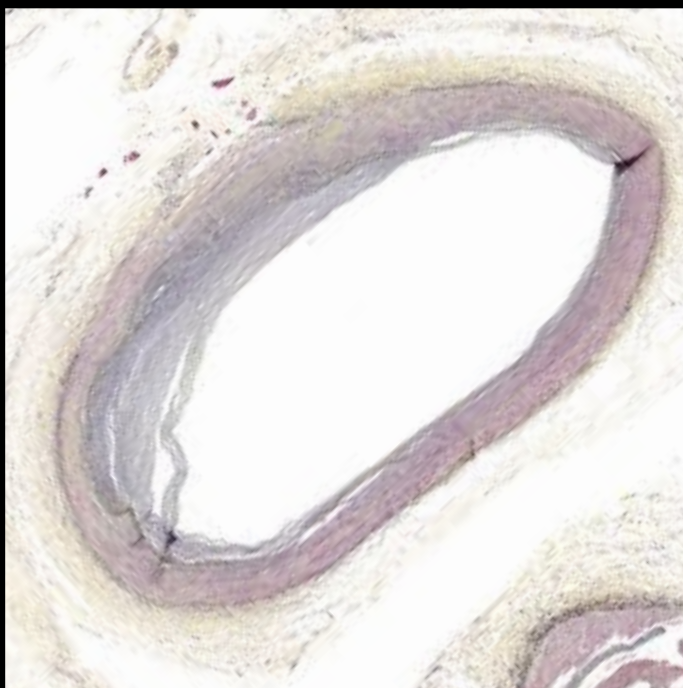
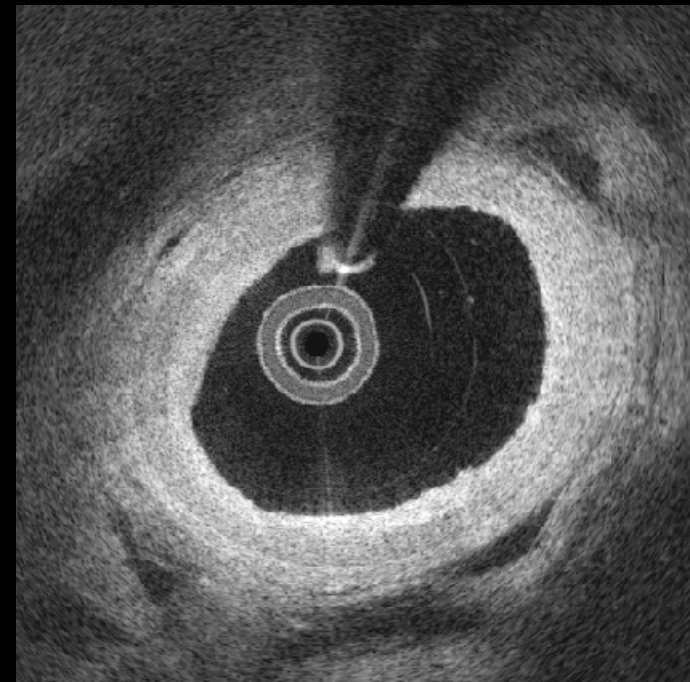
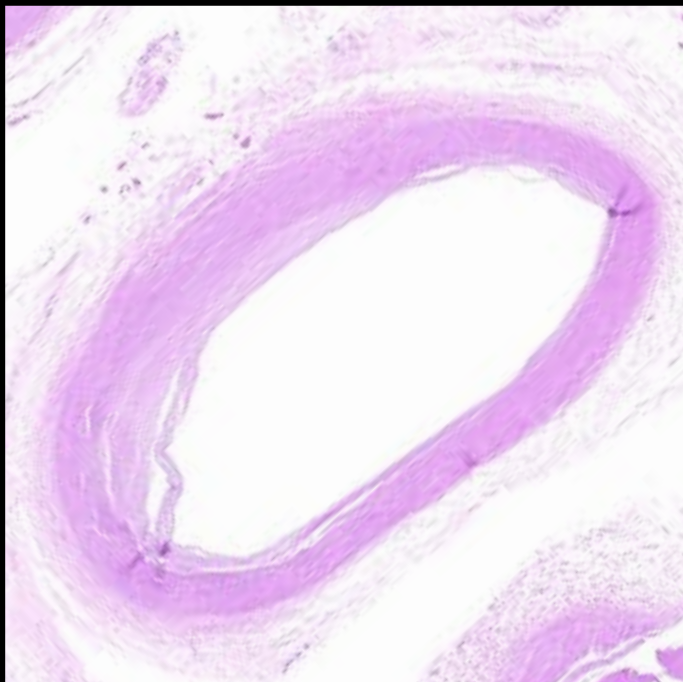
5



6

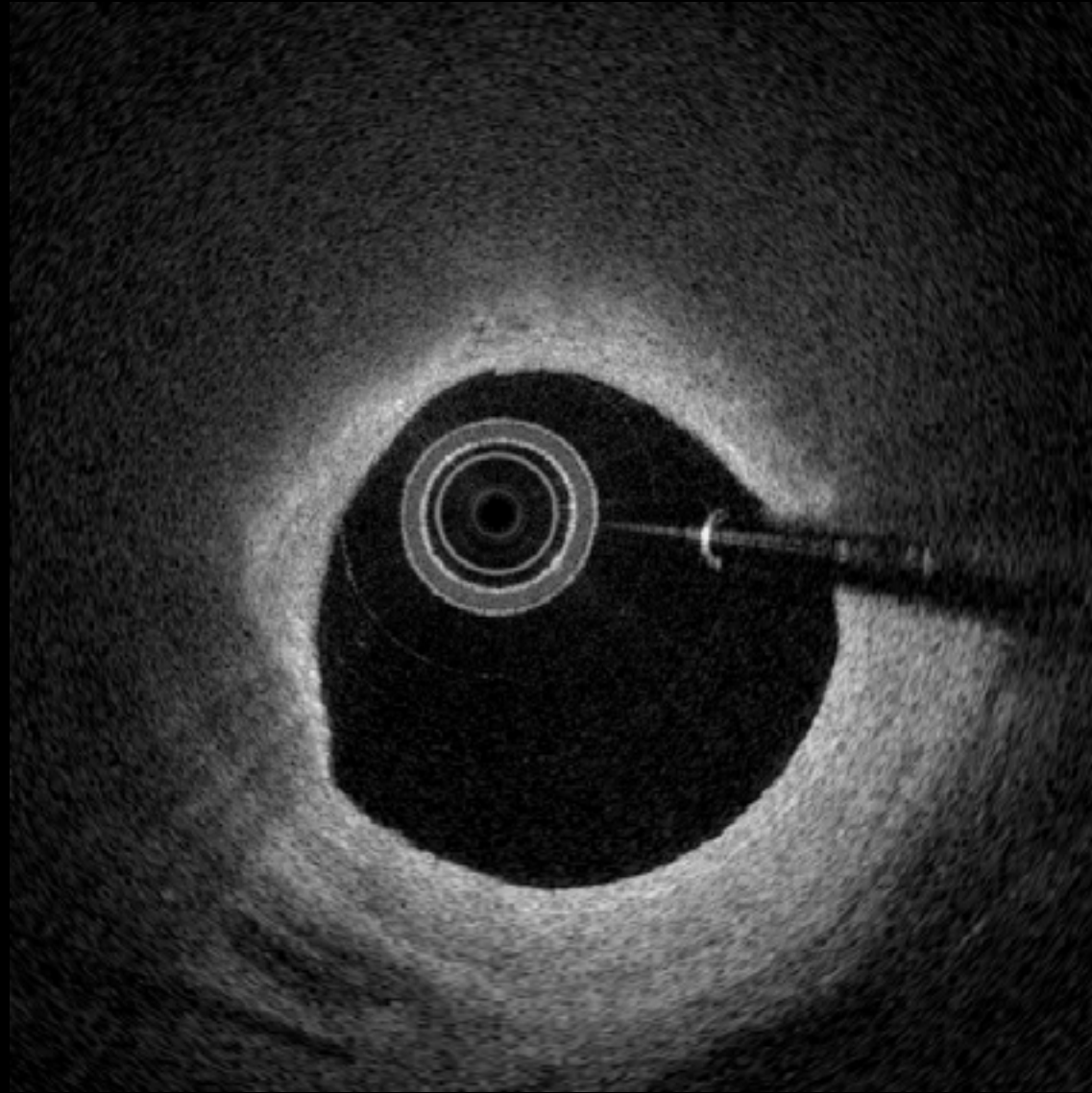


6

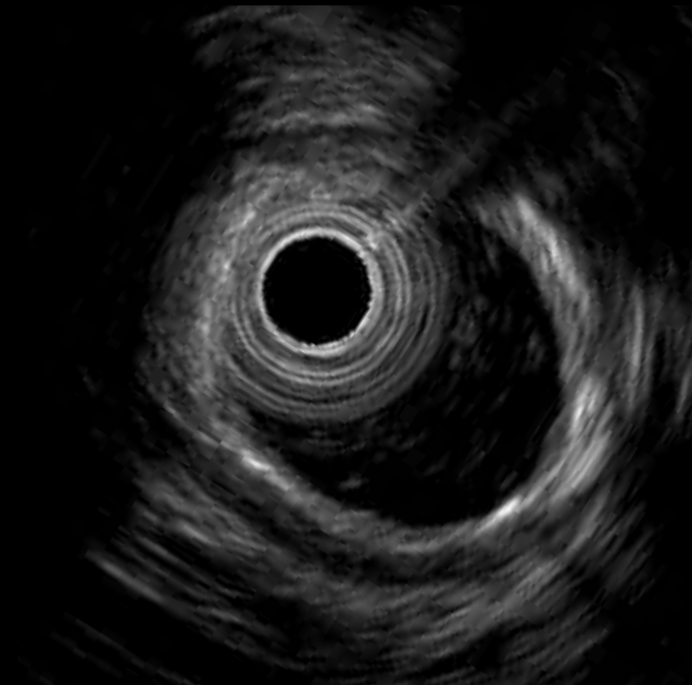
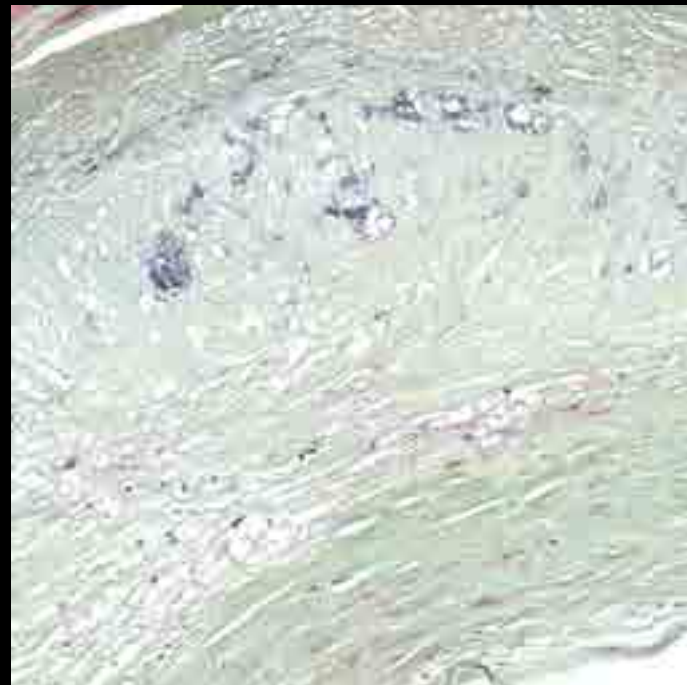
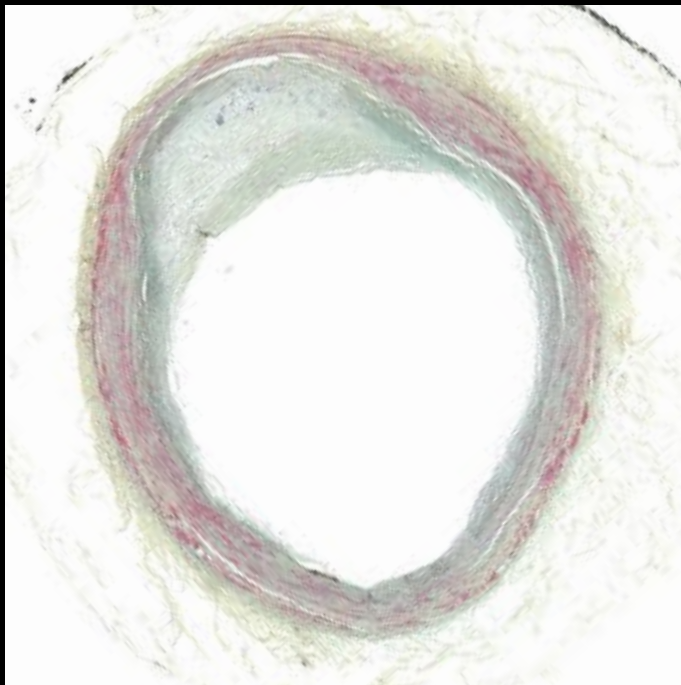
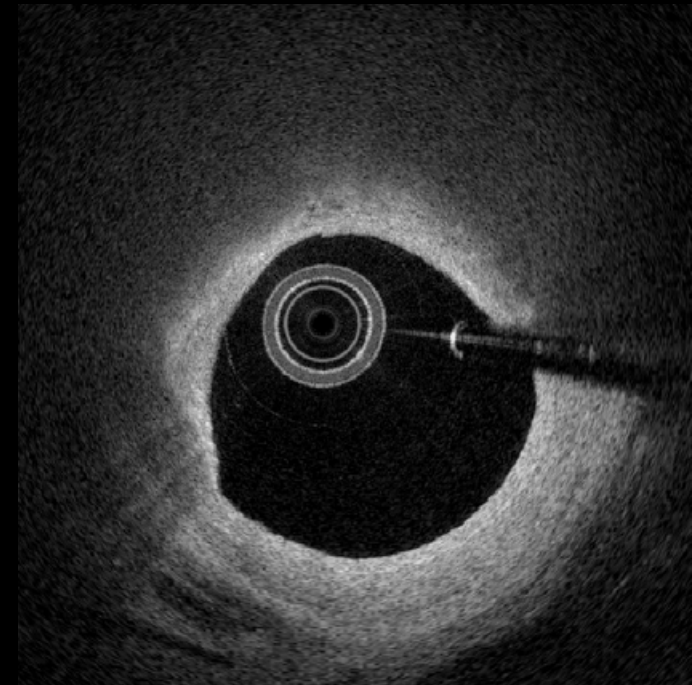
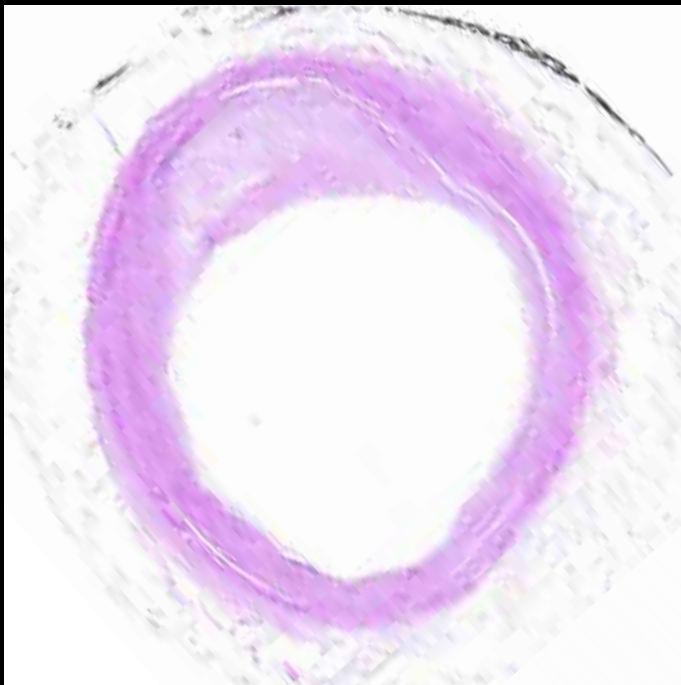


Pathological
Intimal
Thickening

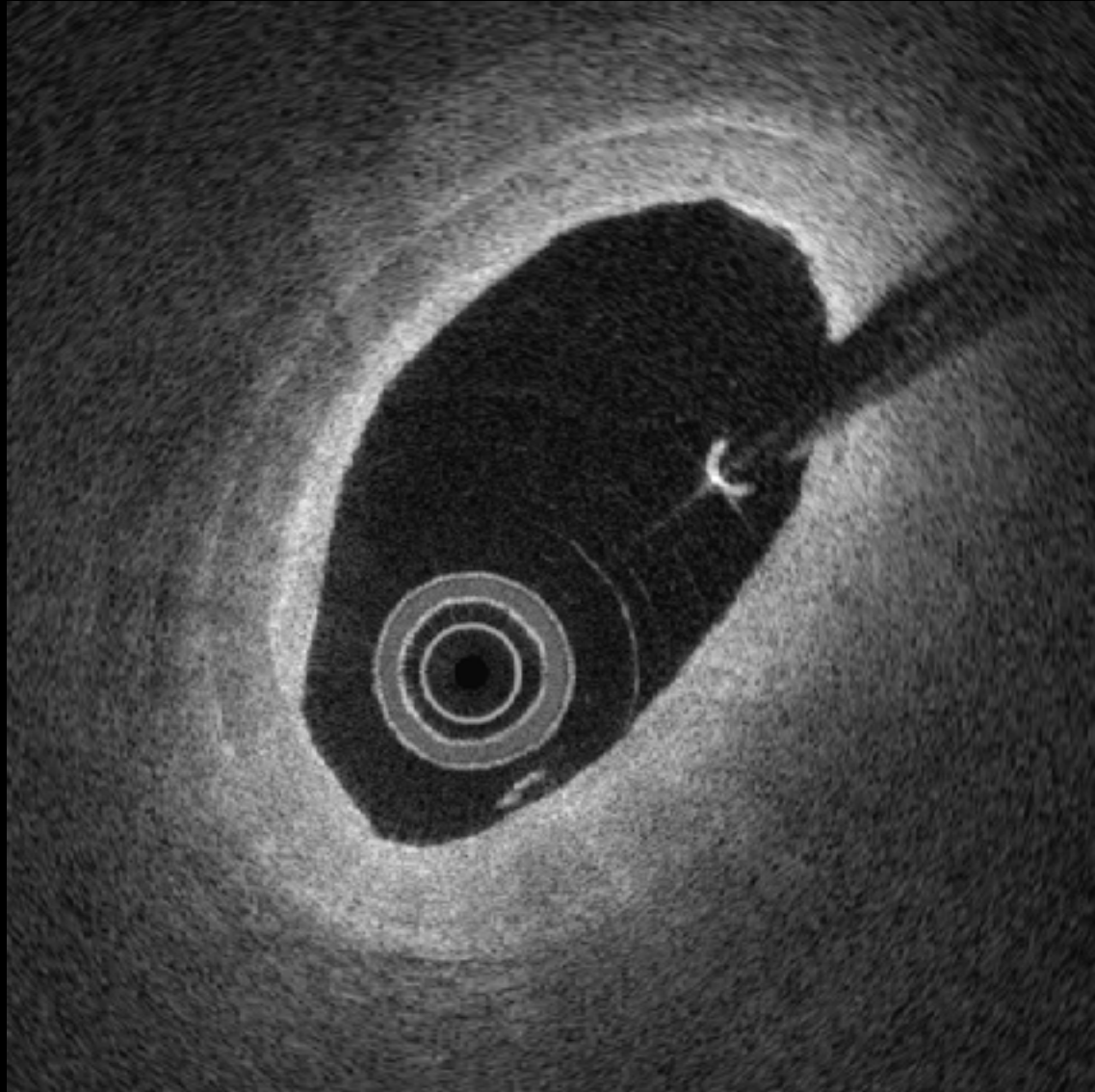
7



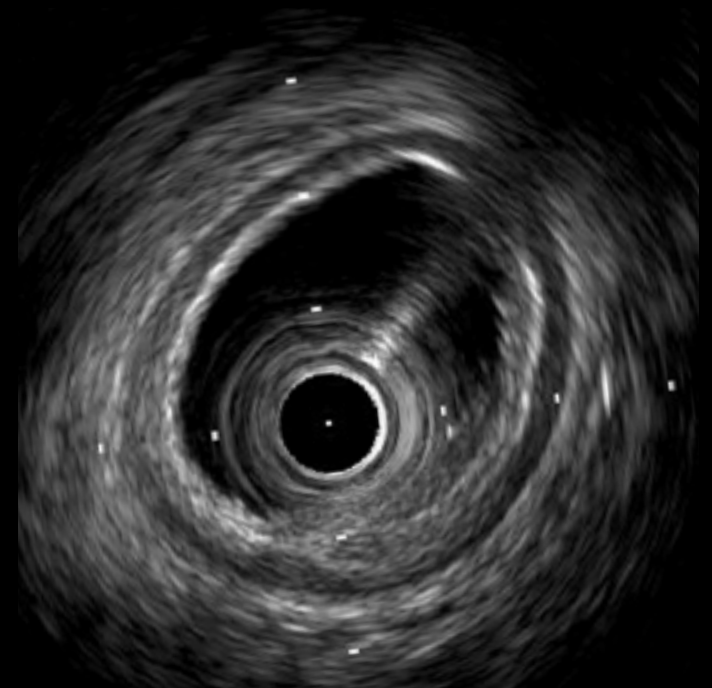
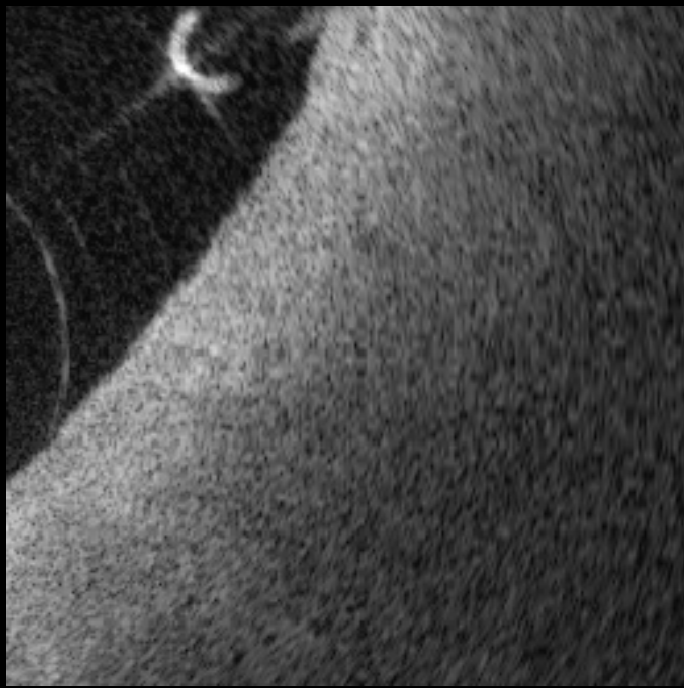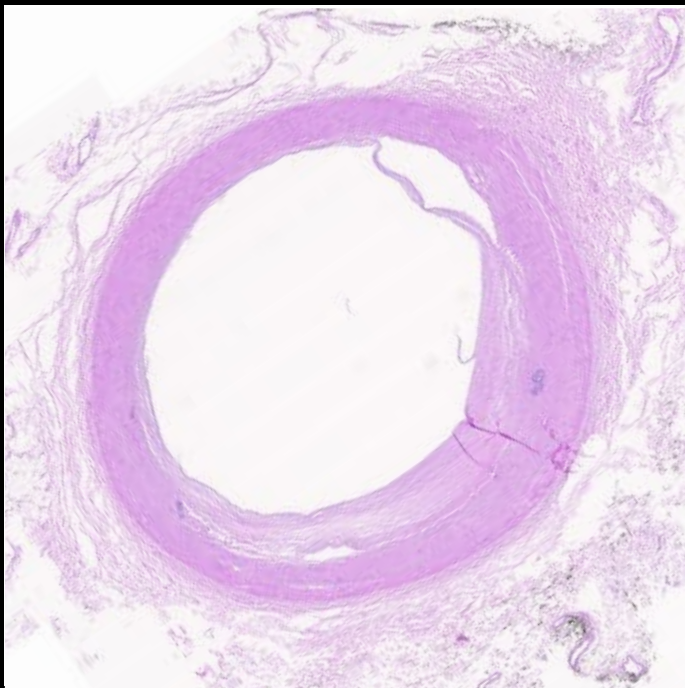
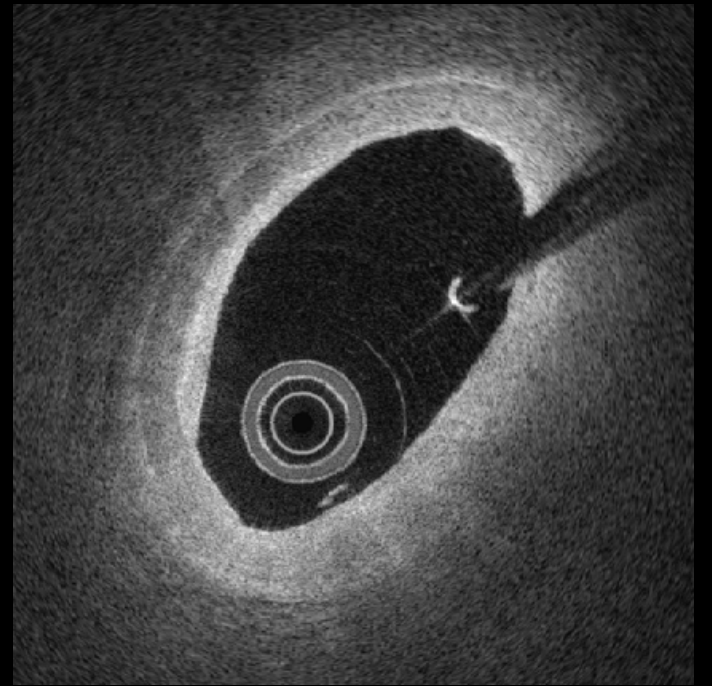
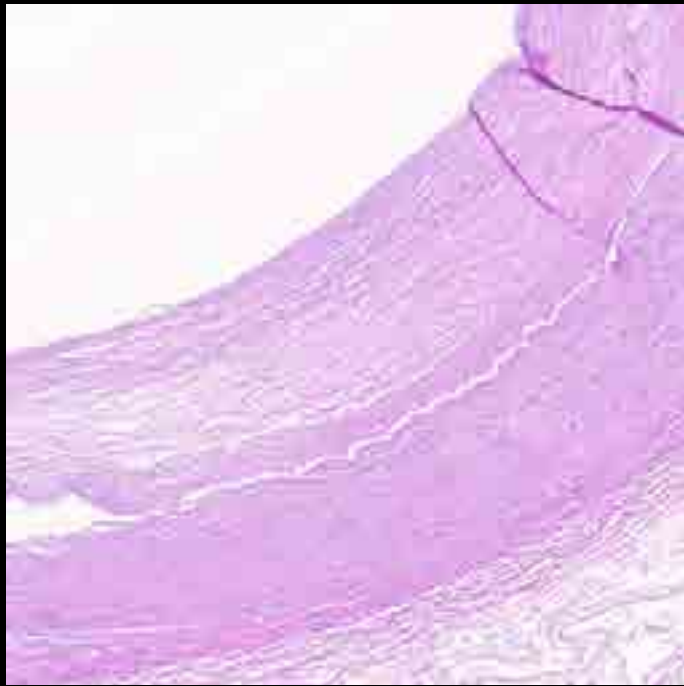
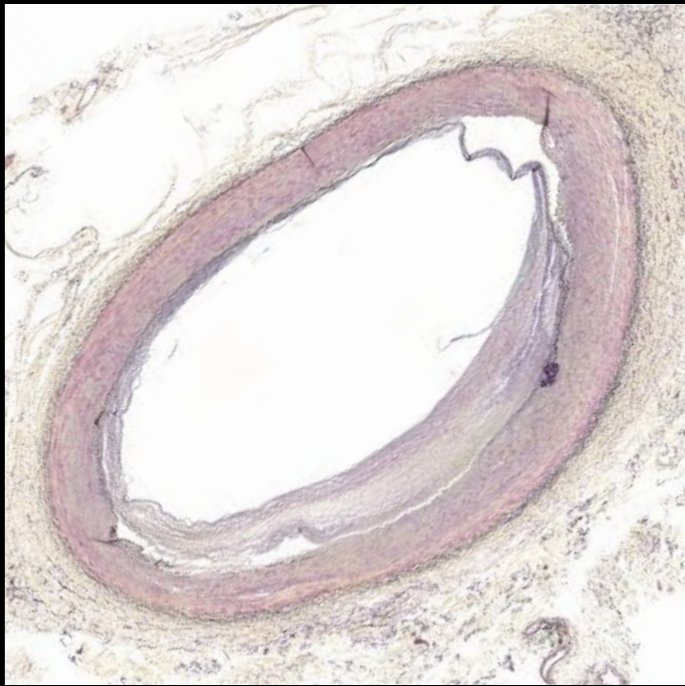
7



#8

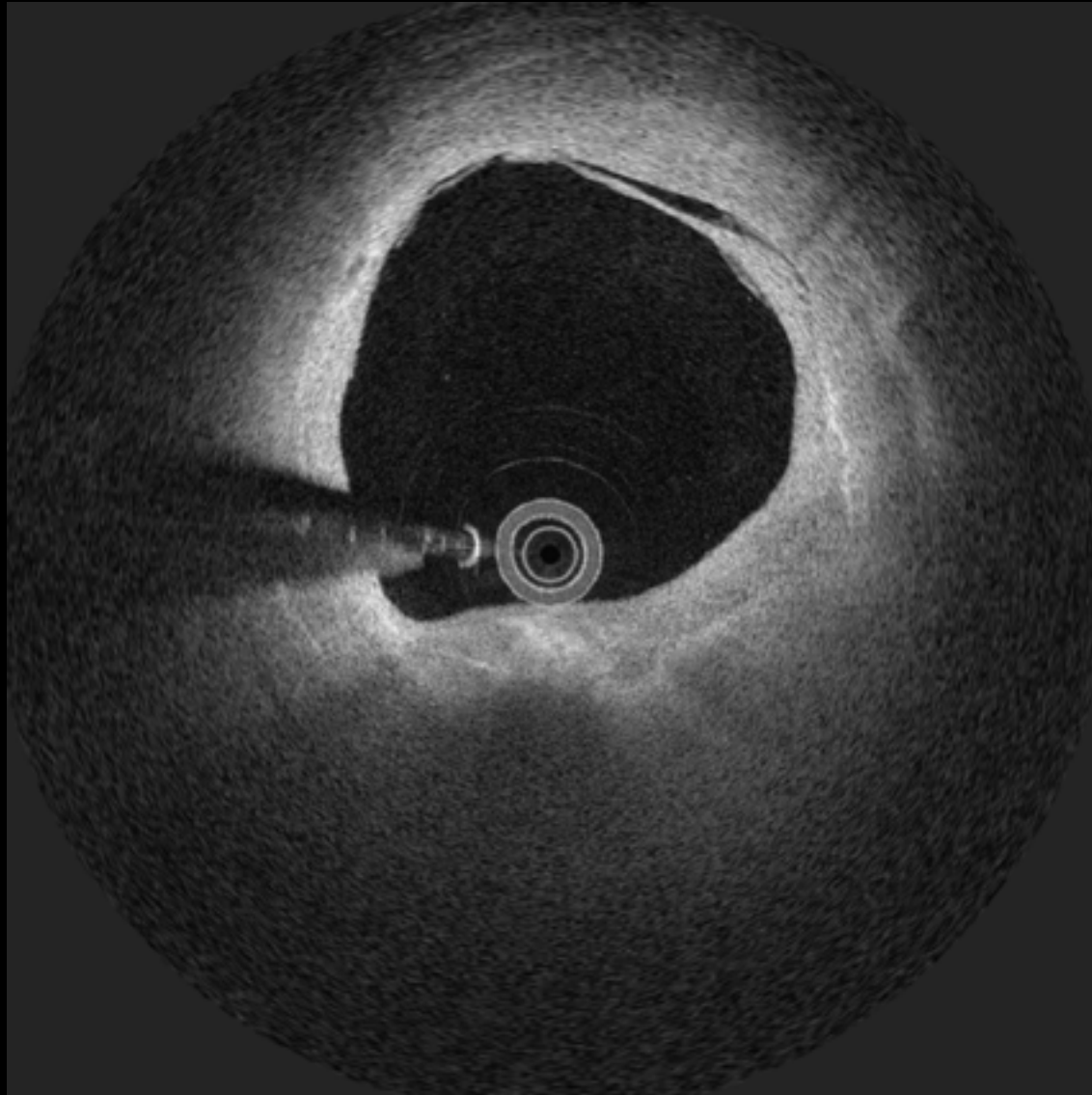


#8

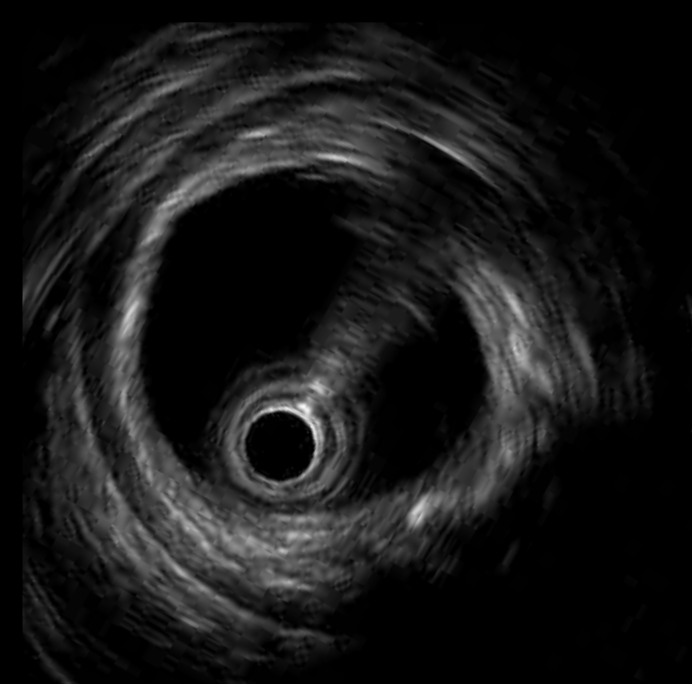
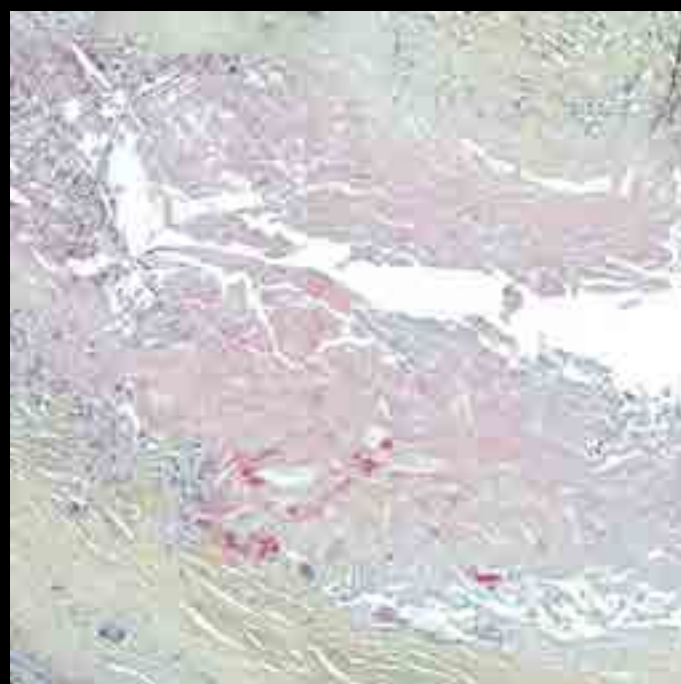
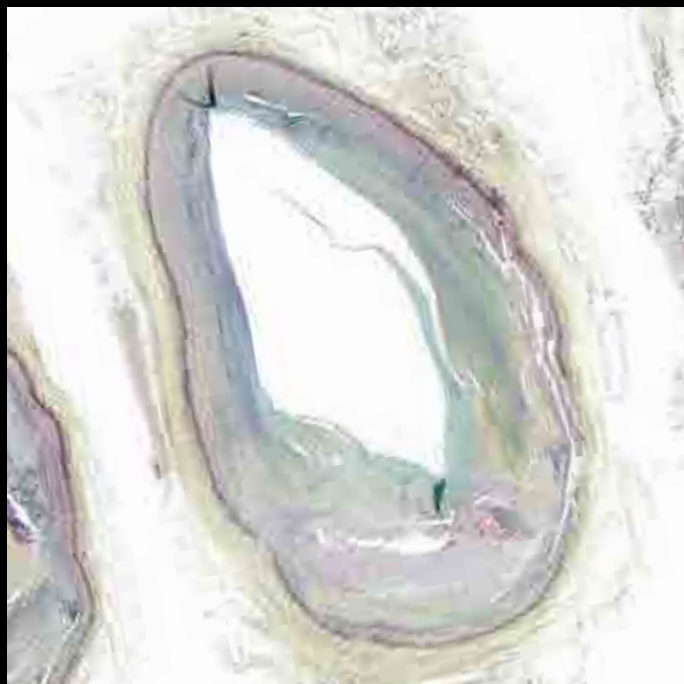
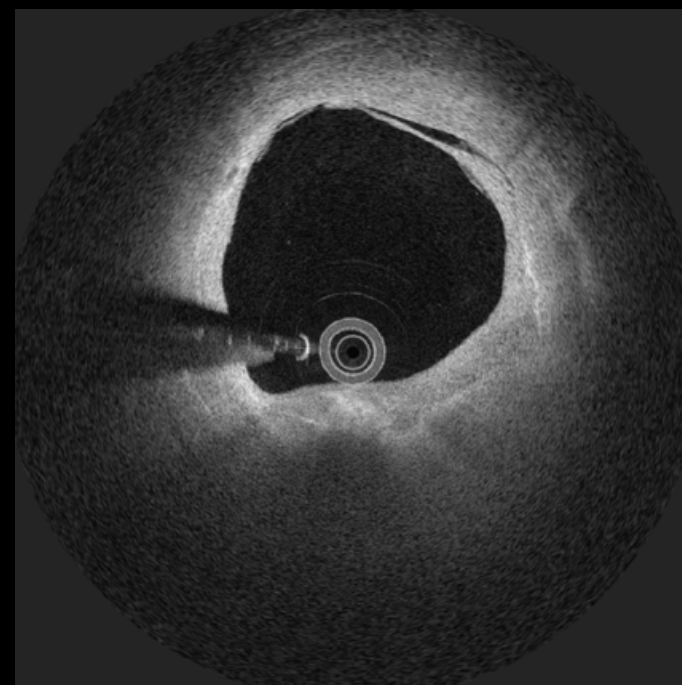
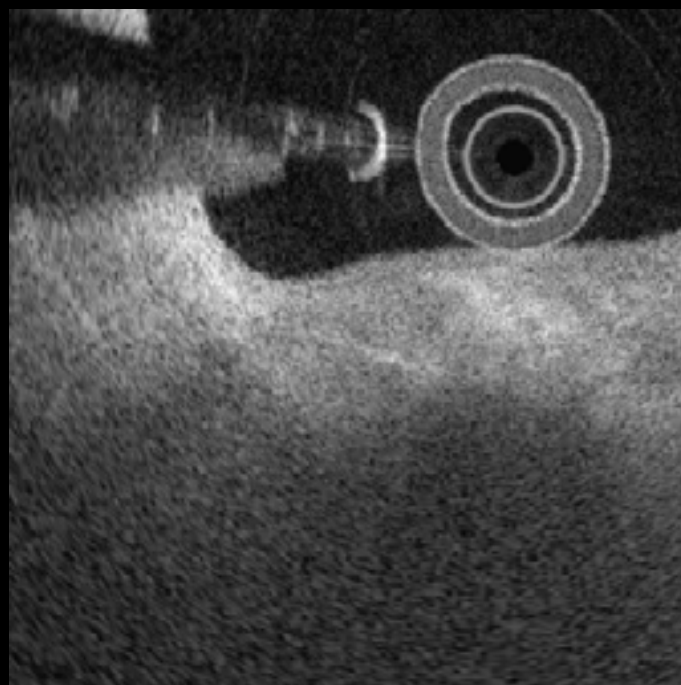
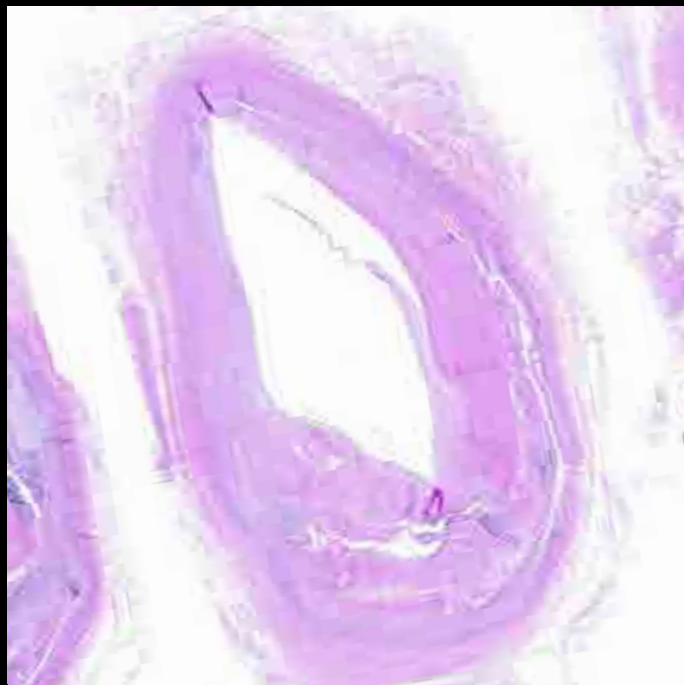


Fibroatheroma

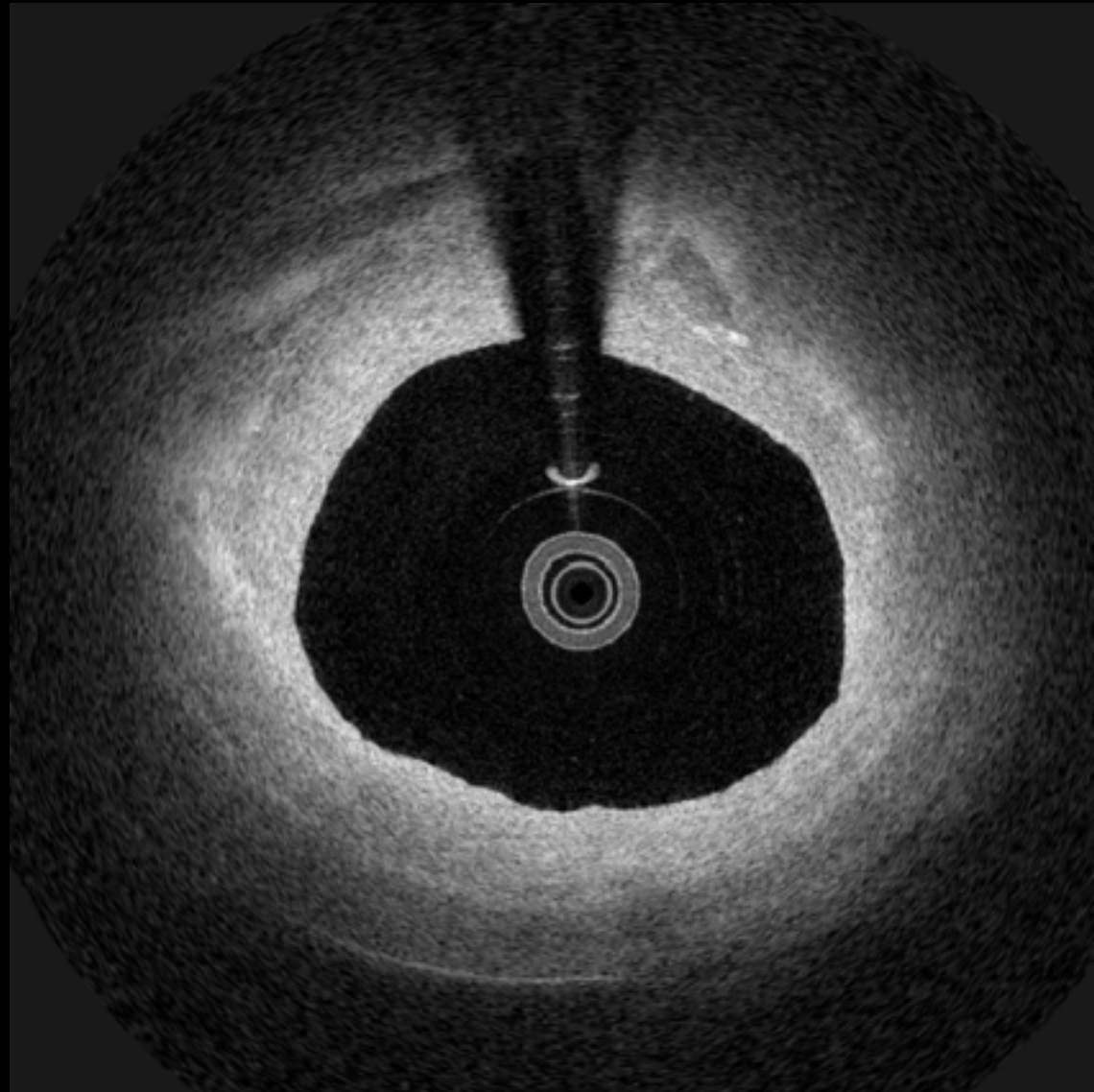
9



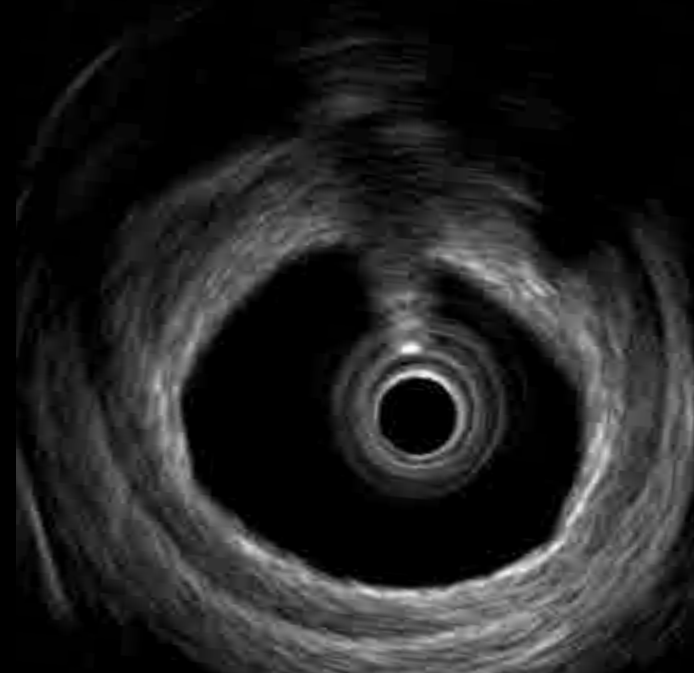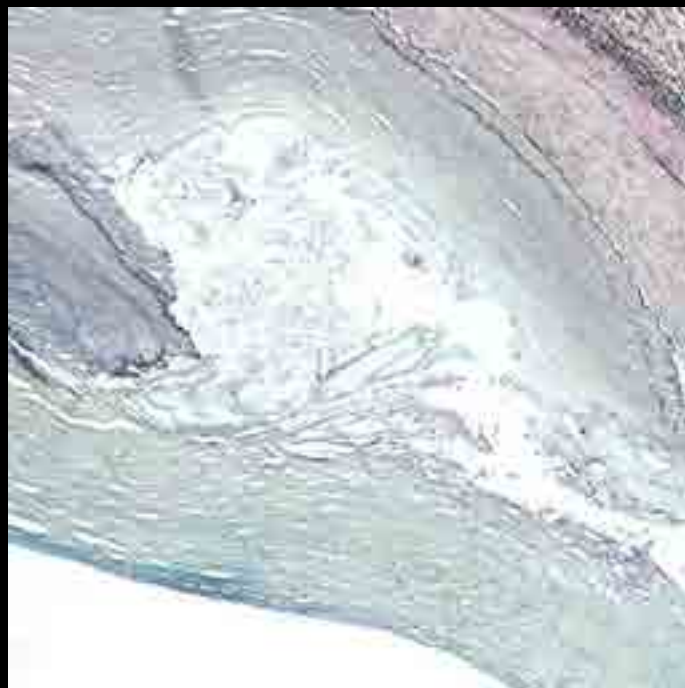
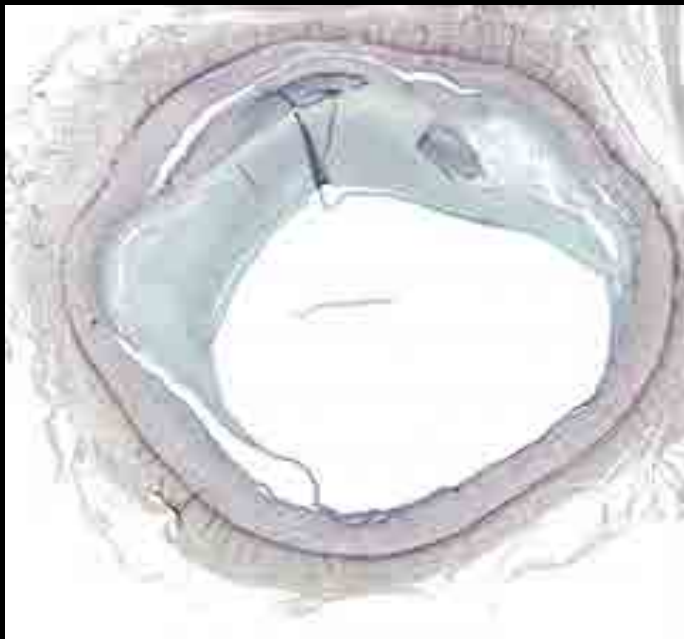
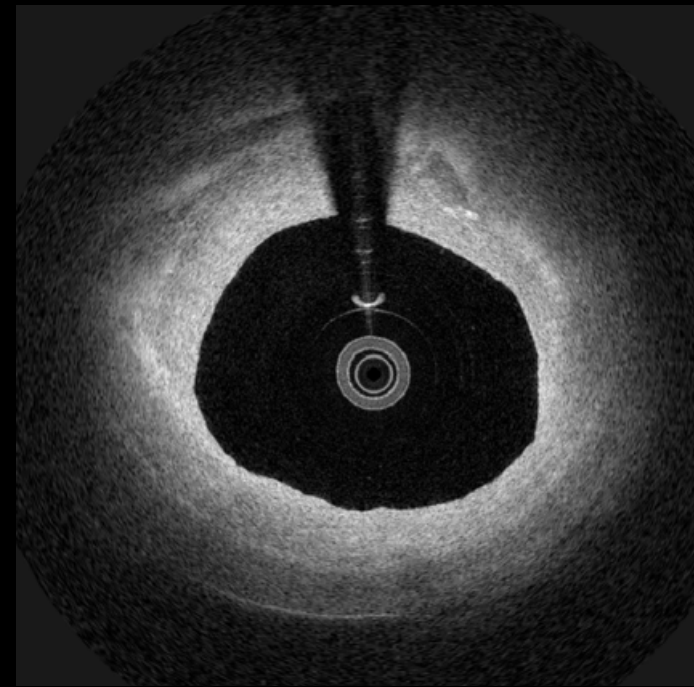
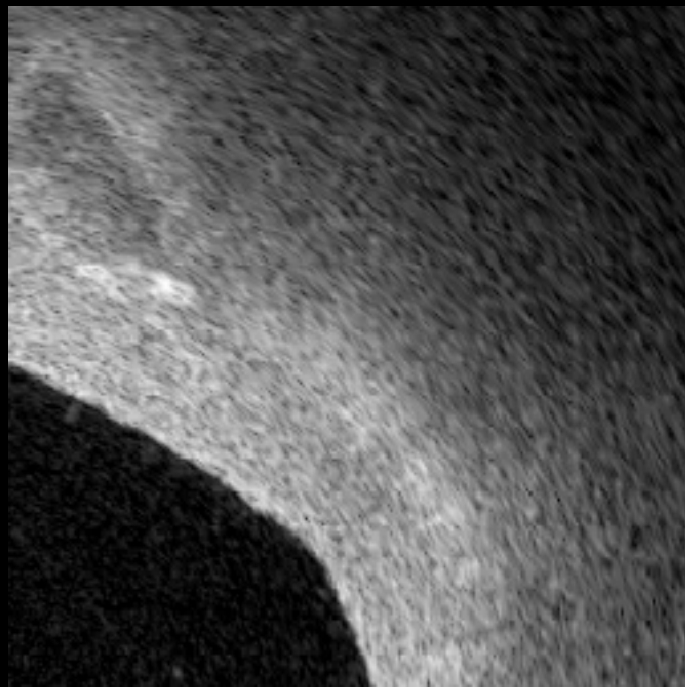
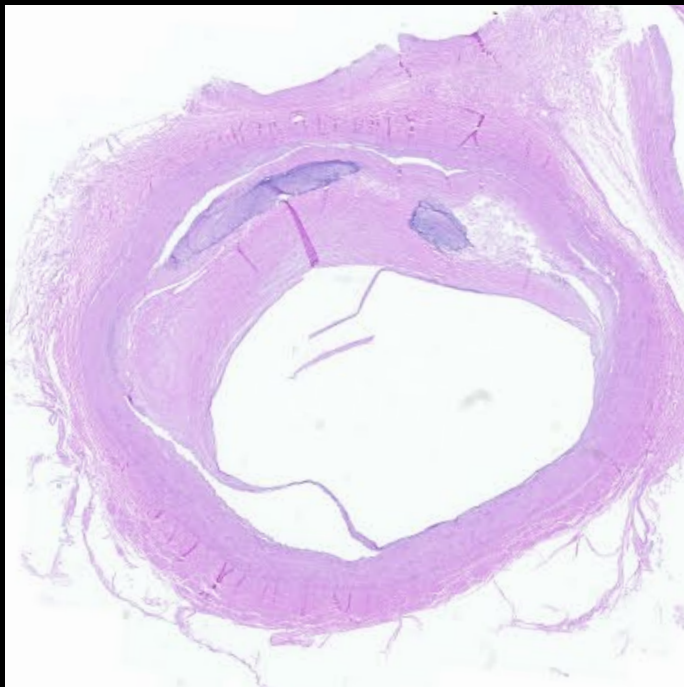9



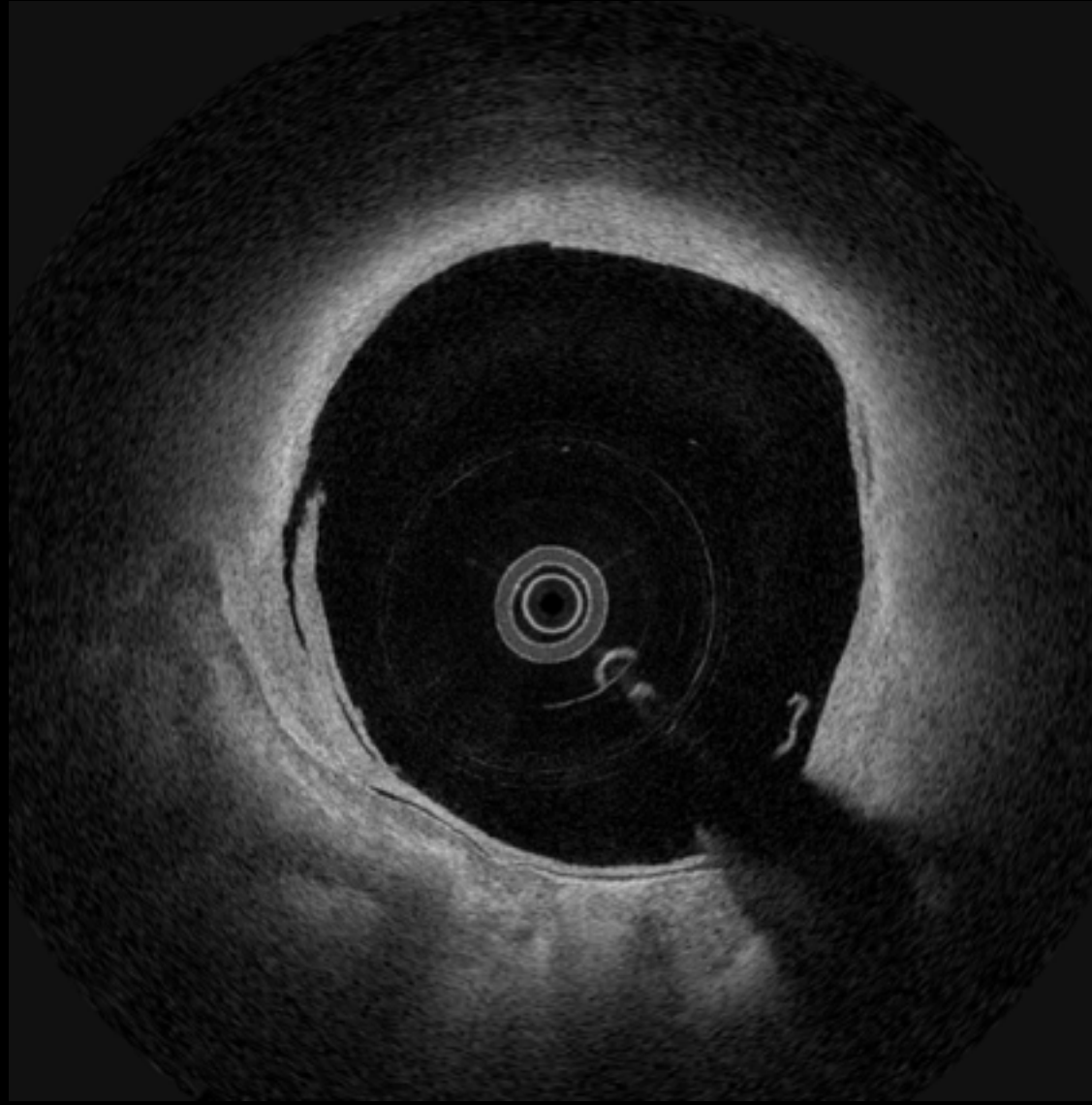
10



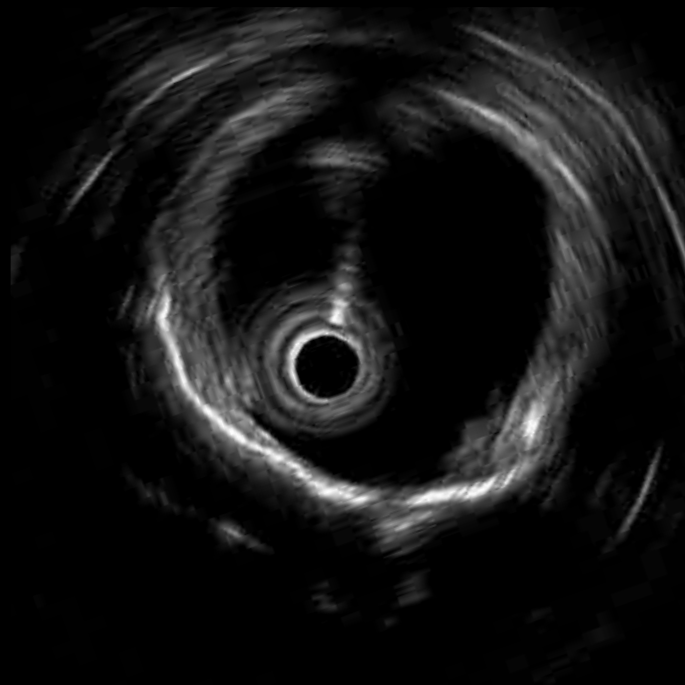
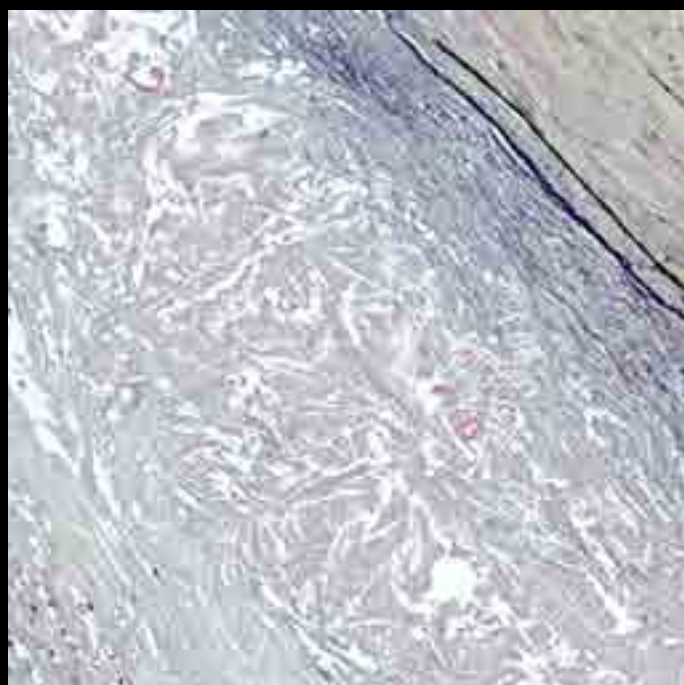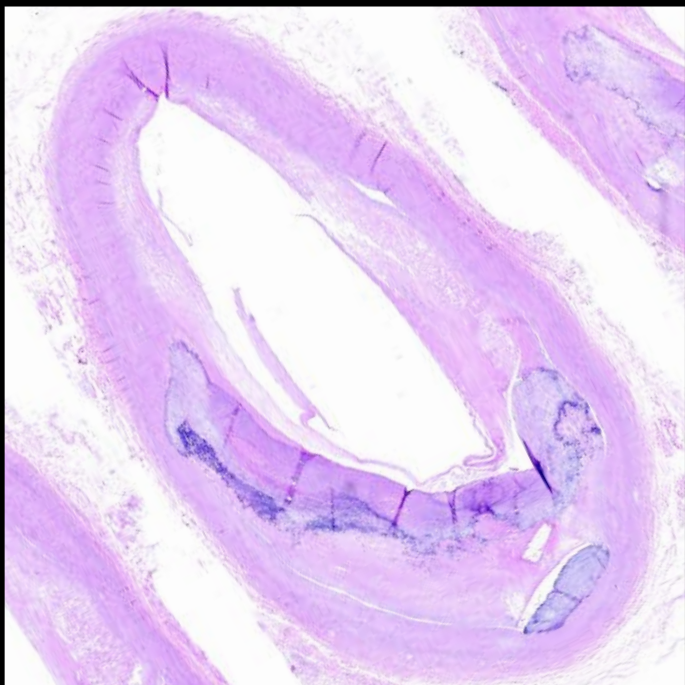
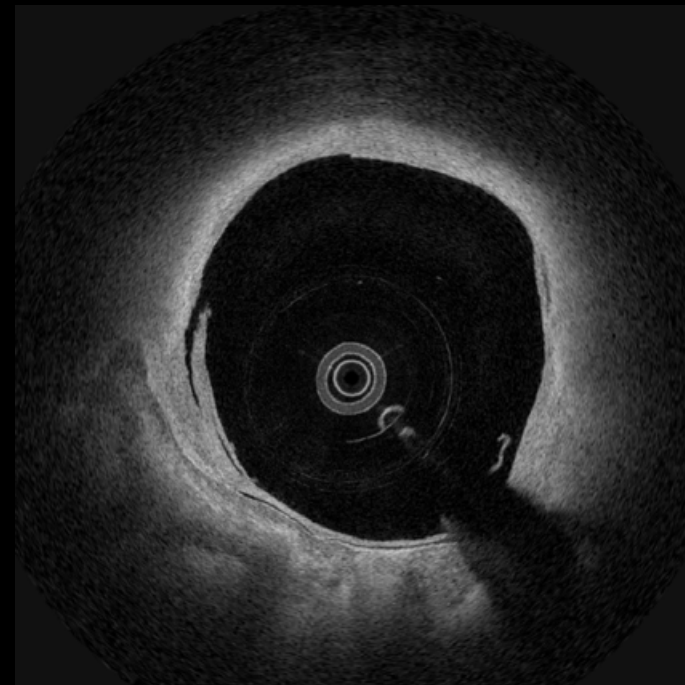

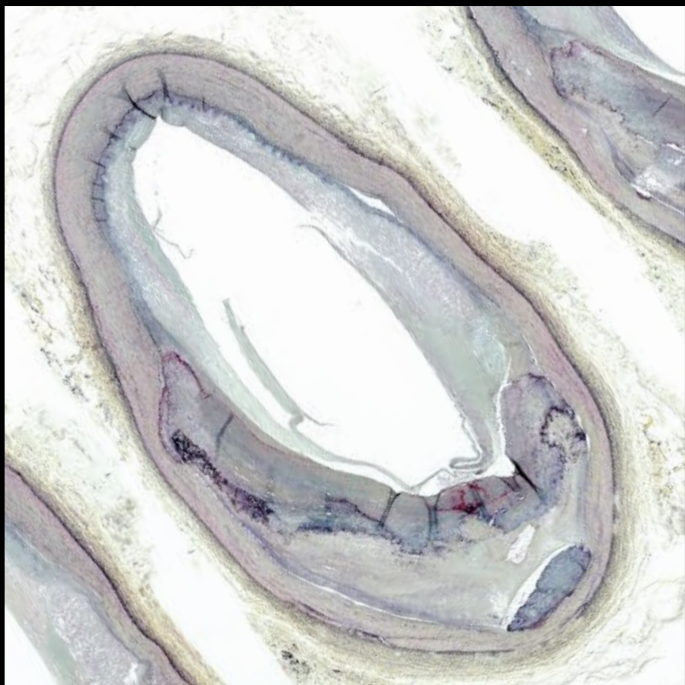10



11

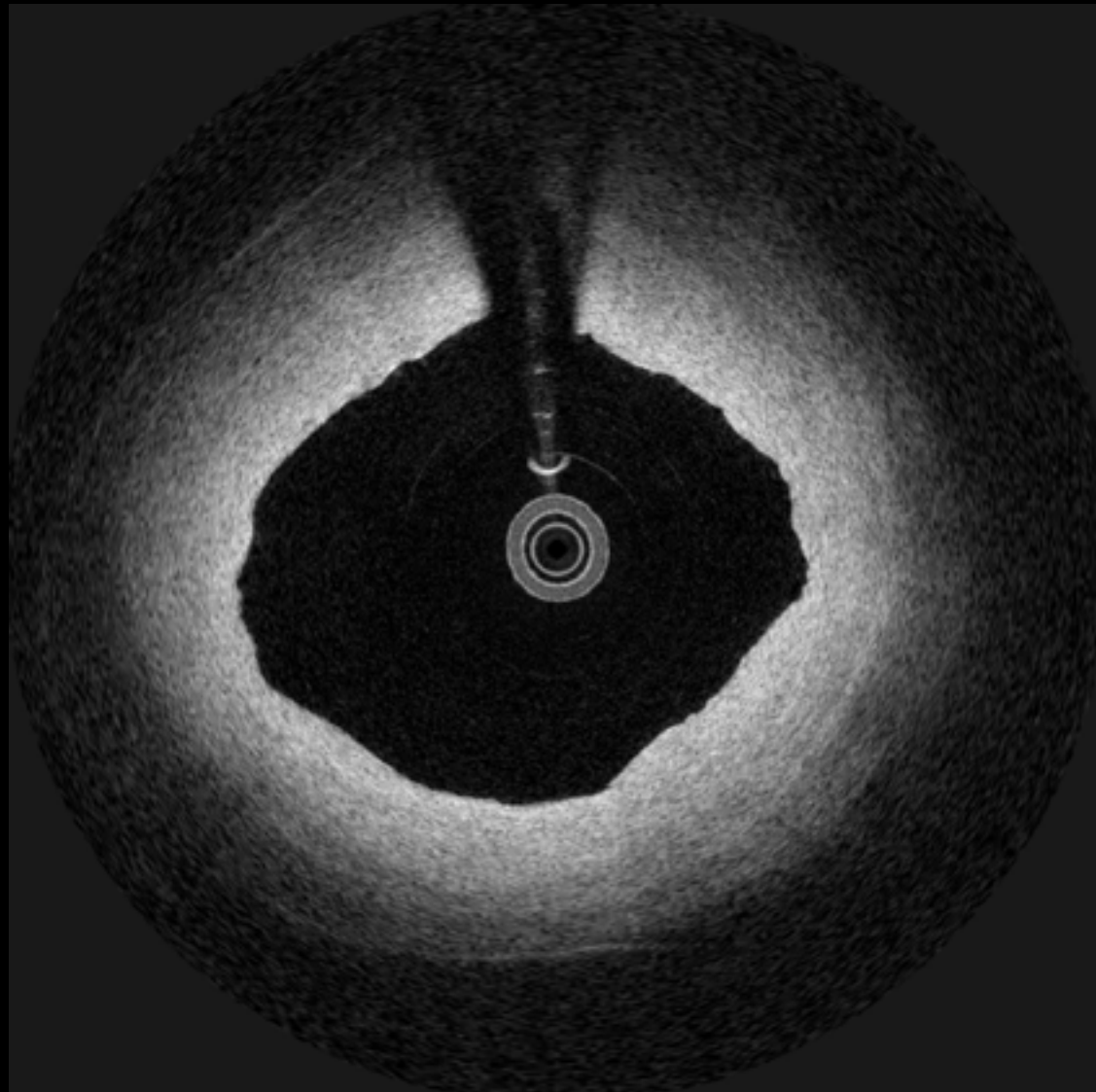


11

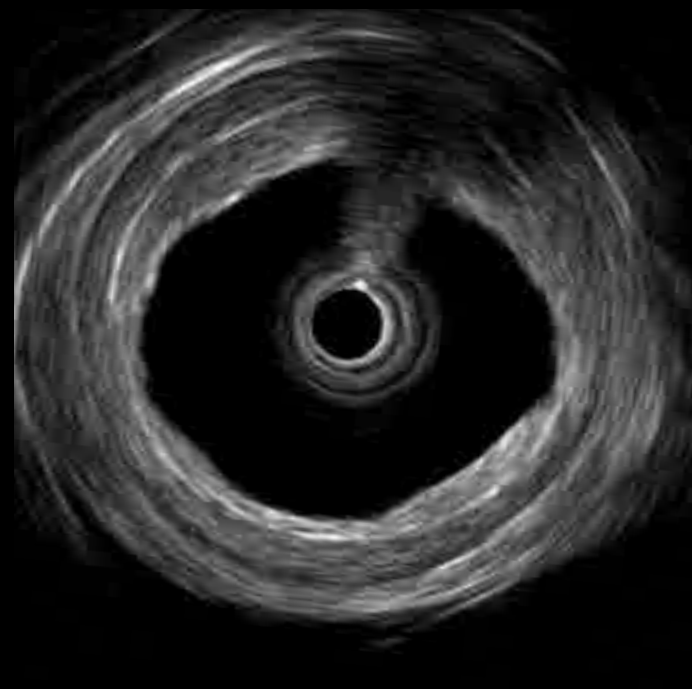
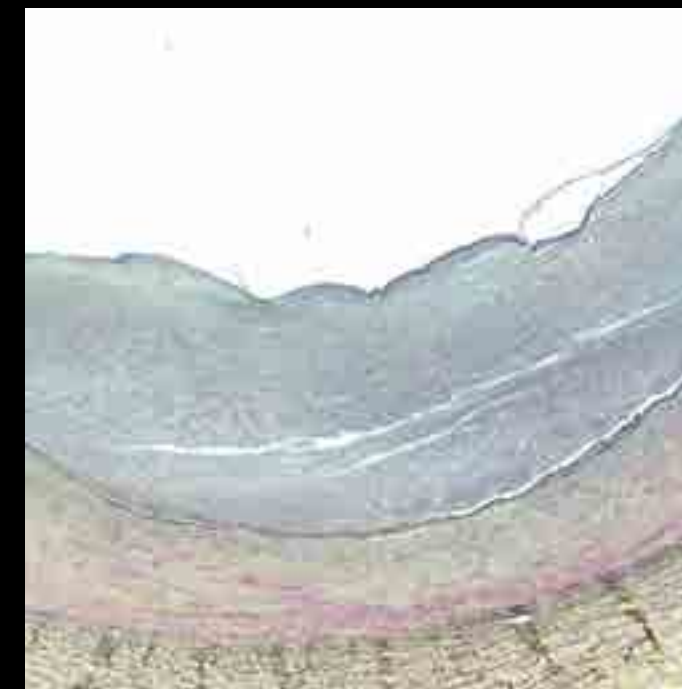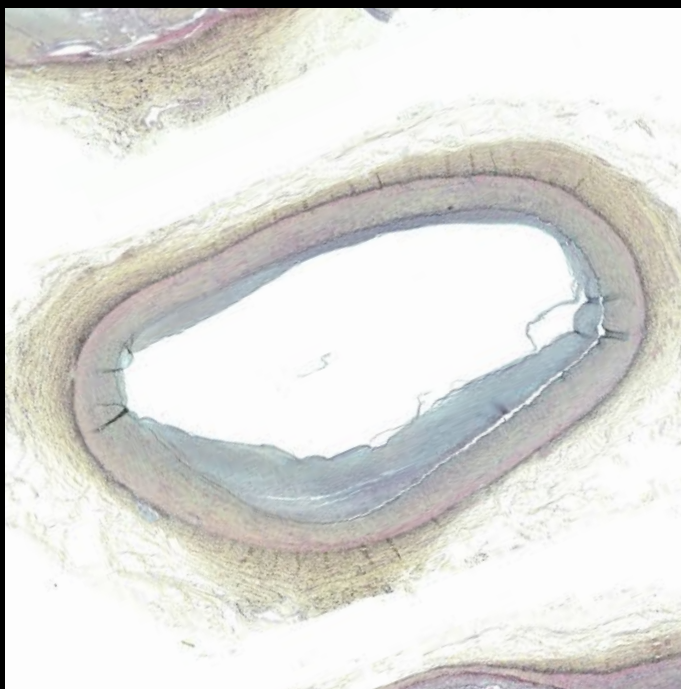
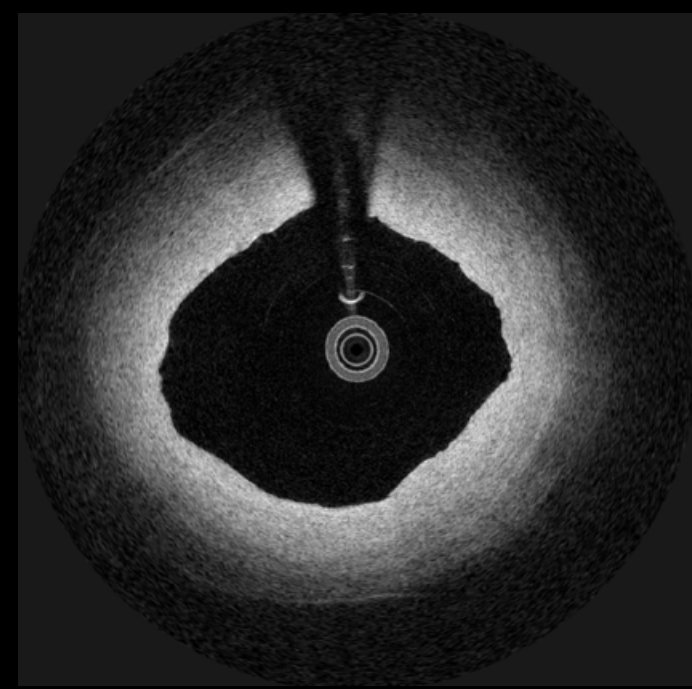
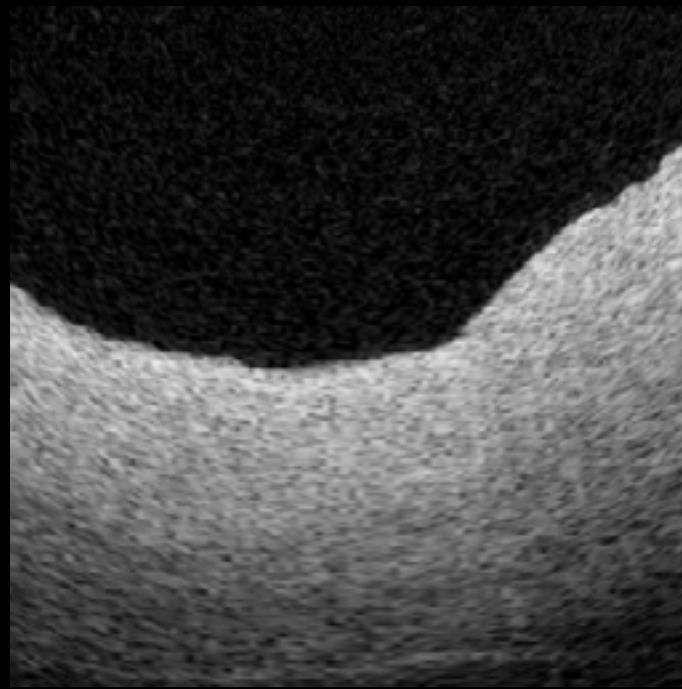
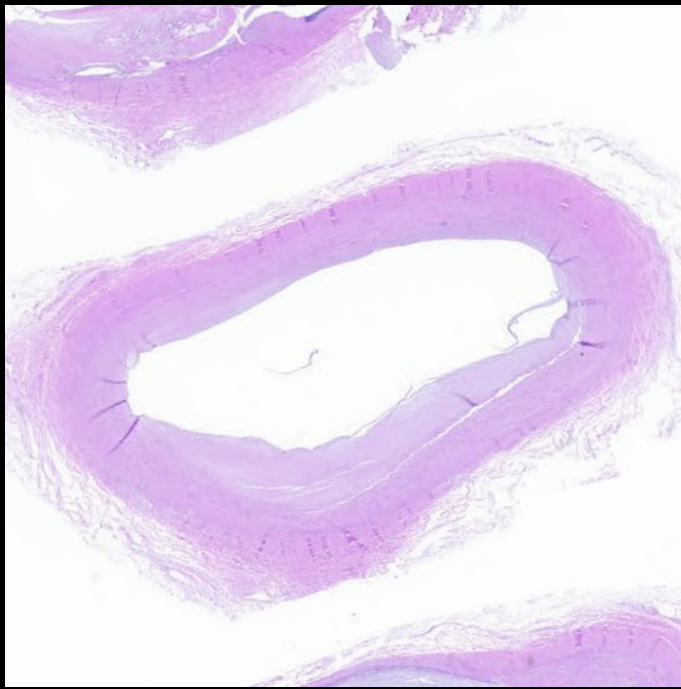


Fibrous plaque

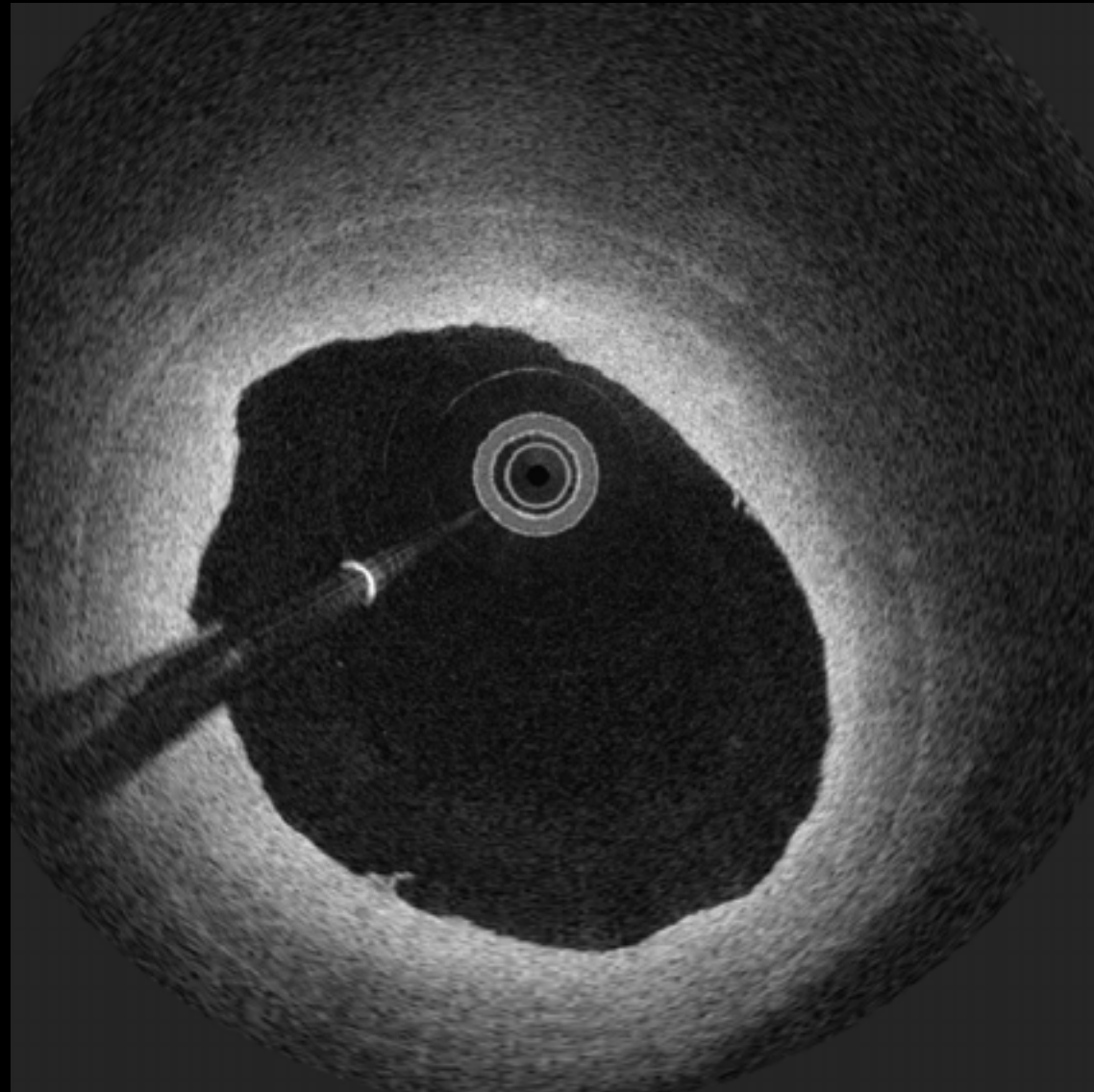
12



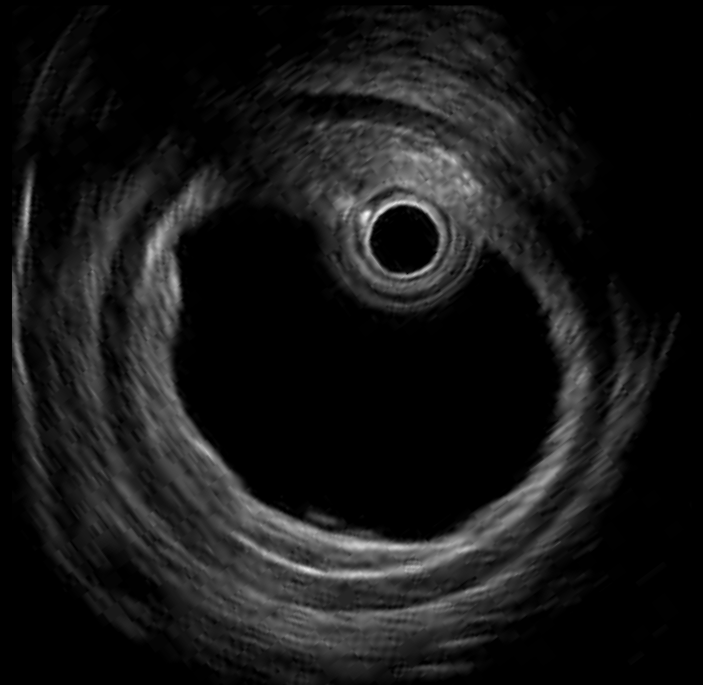
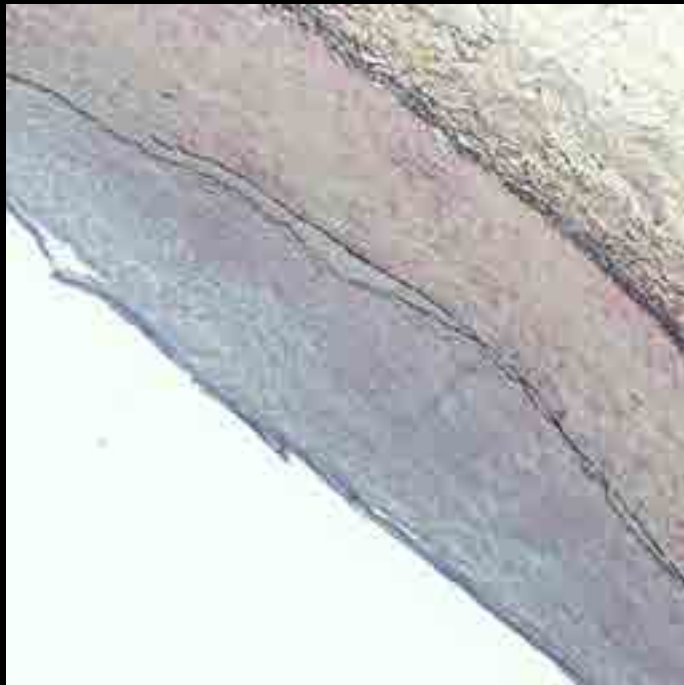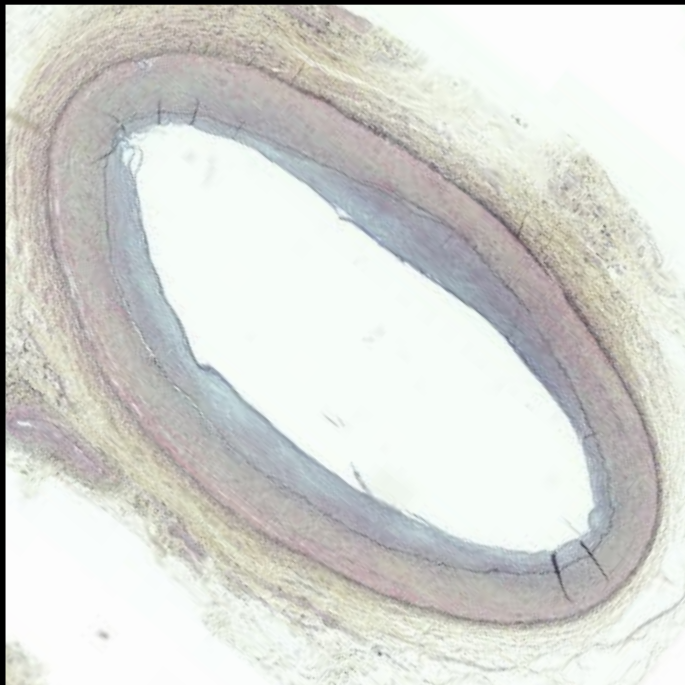
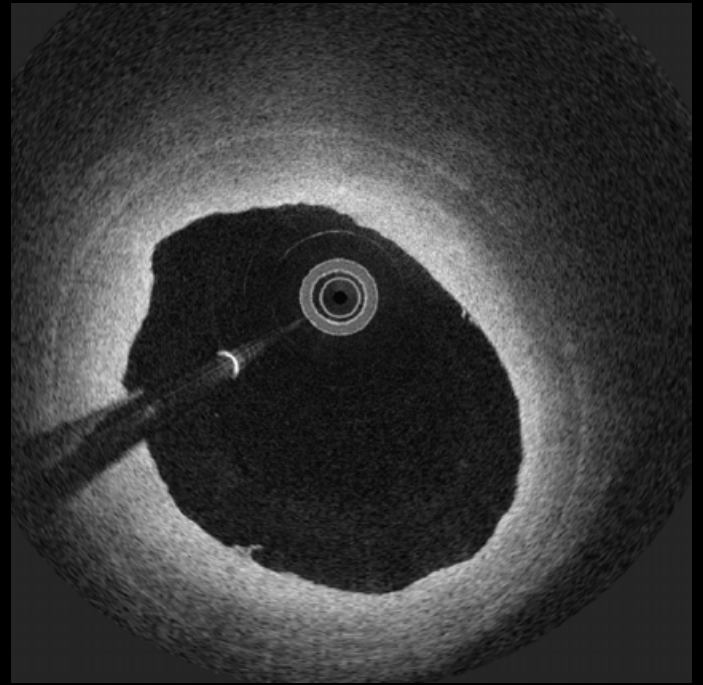

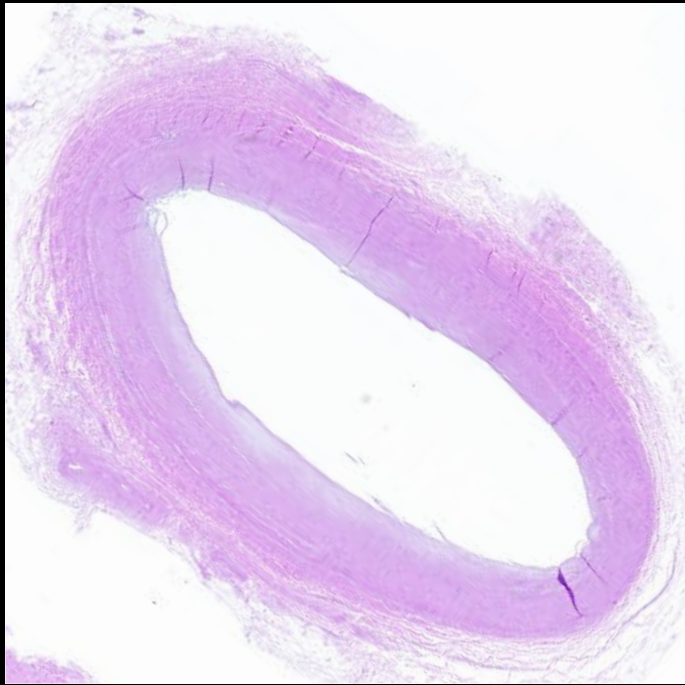
12



#13

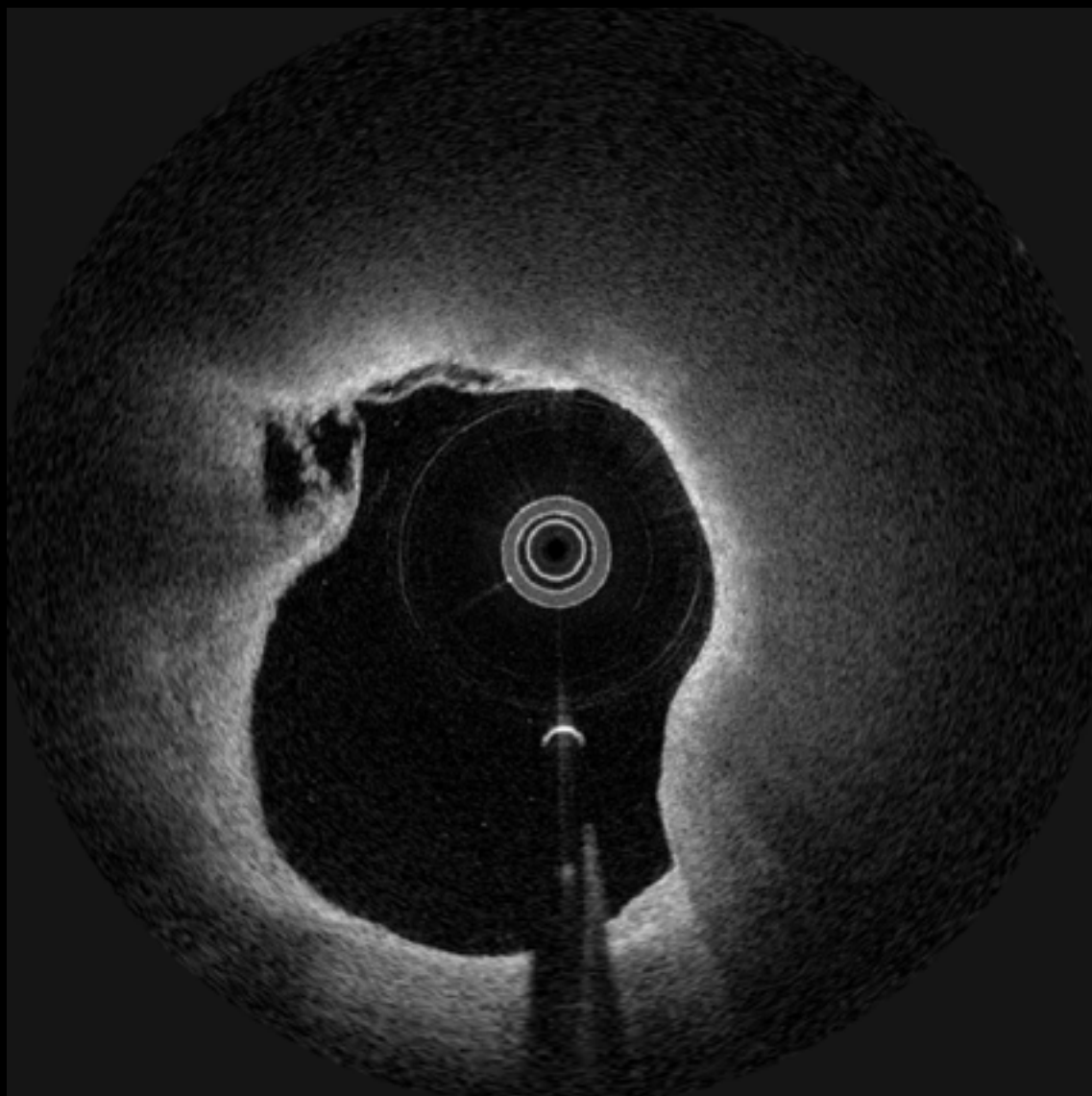


#13

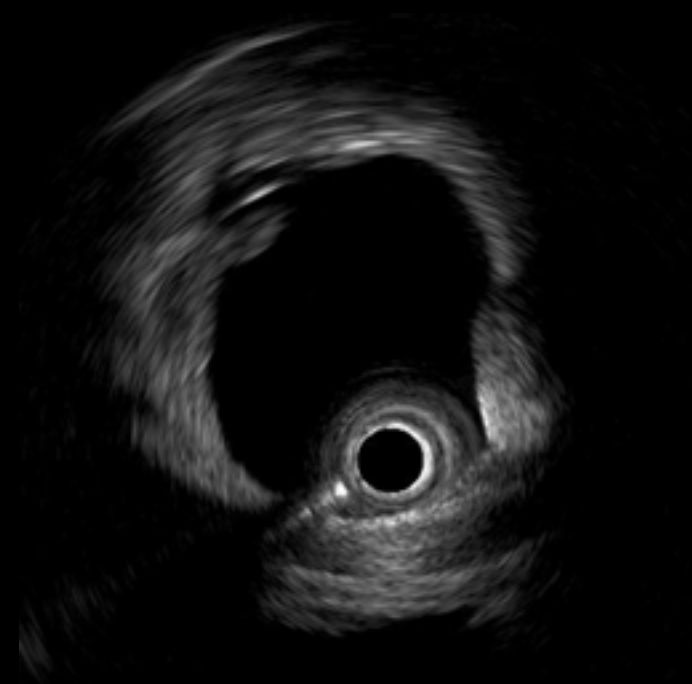
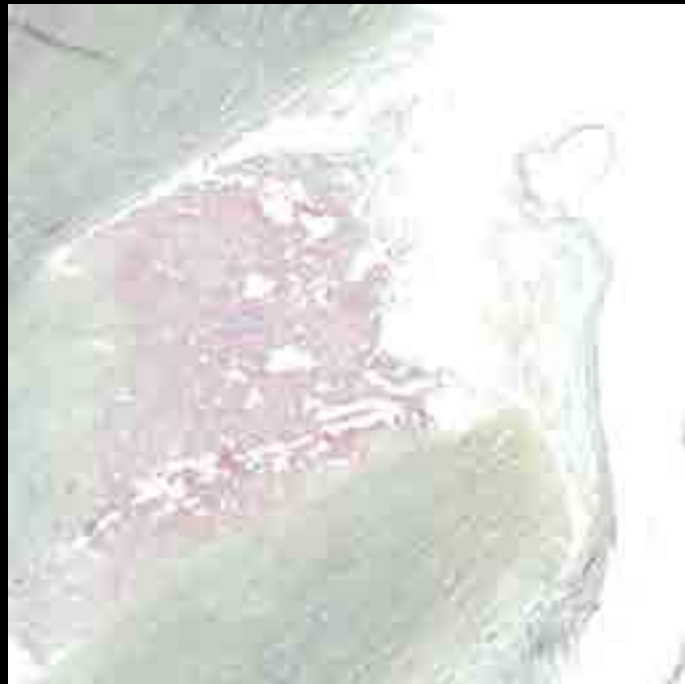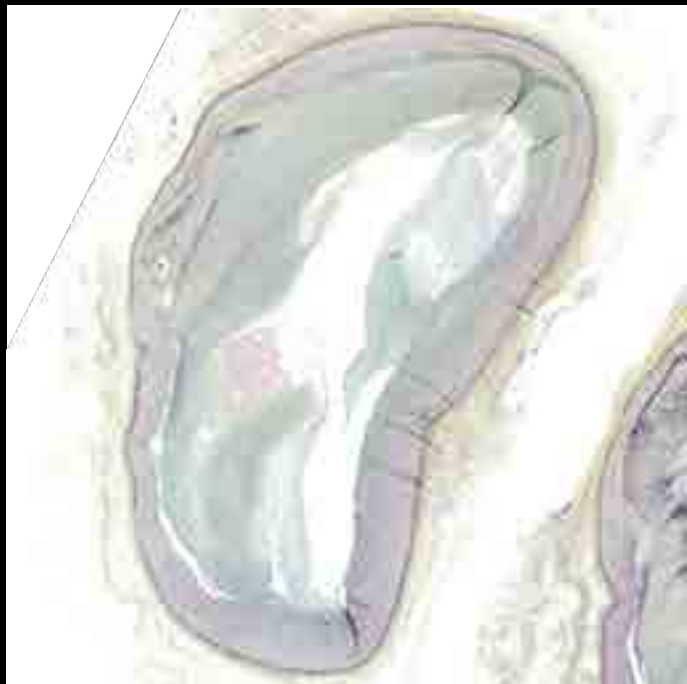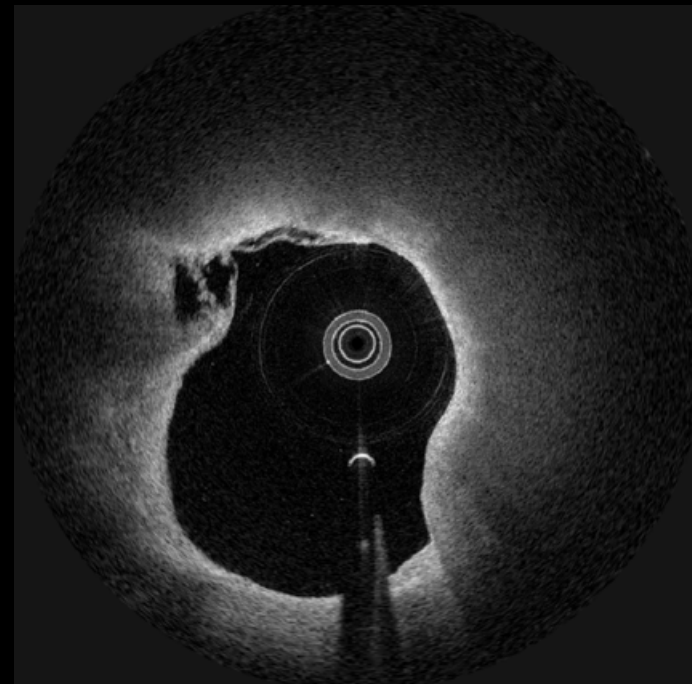
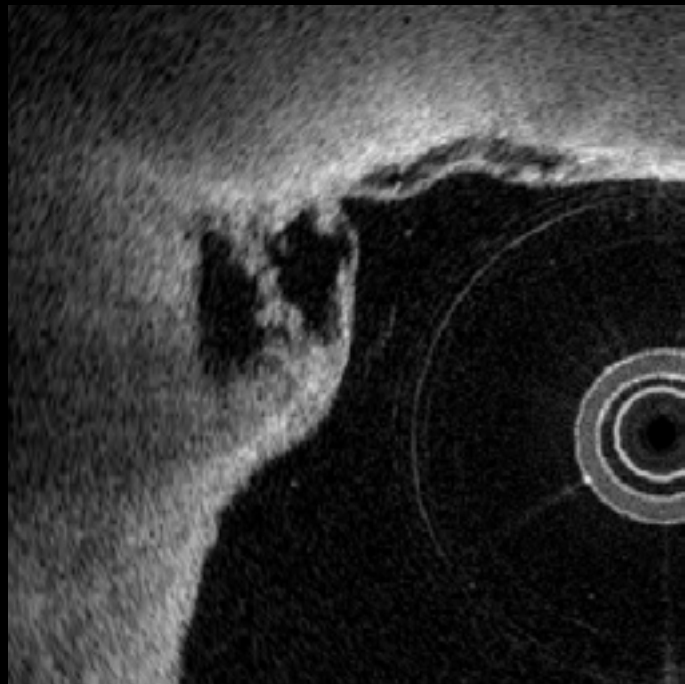


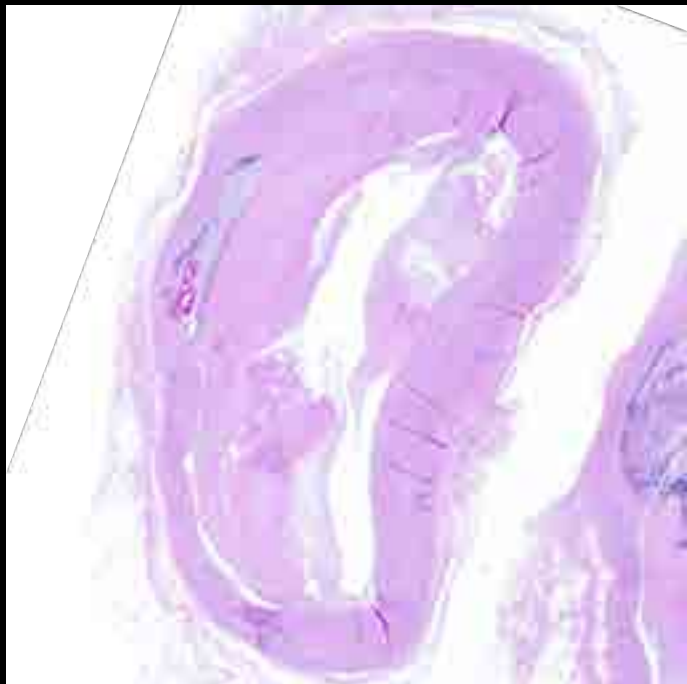Plaque Rupture

14

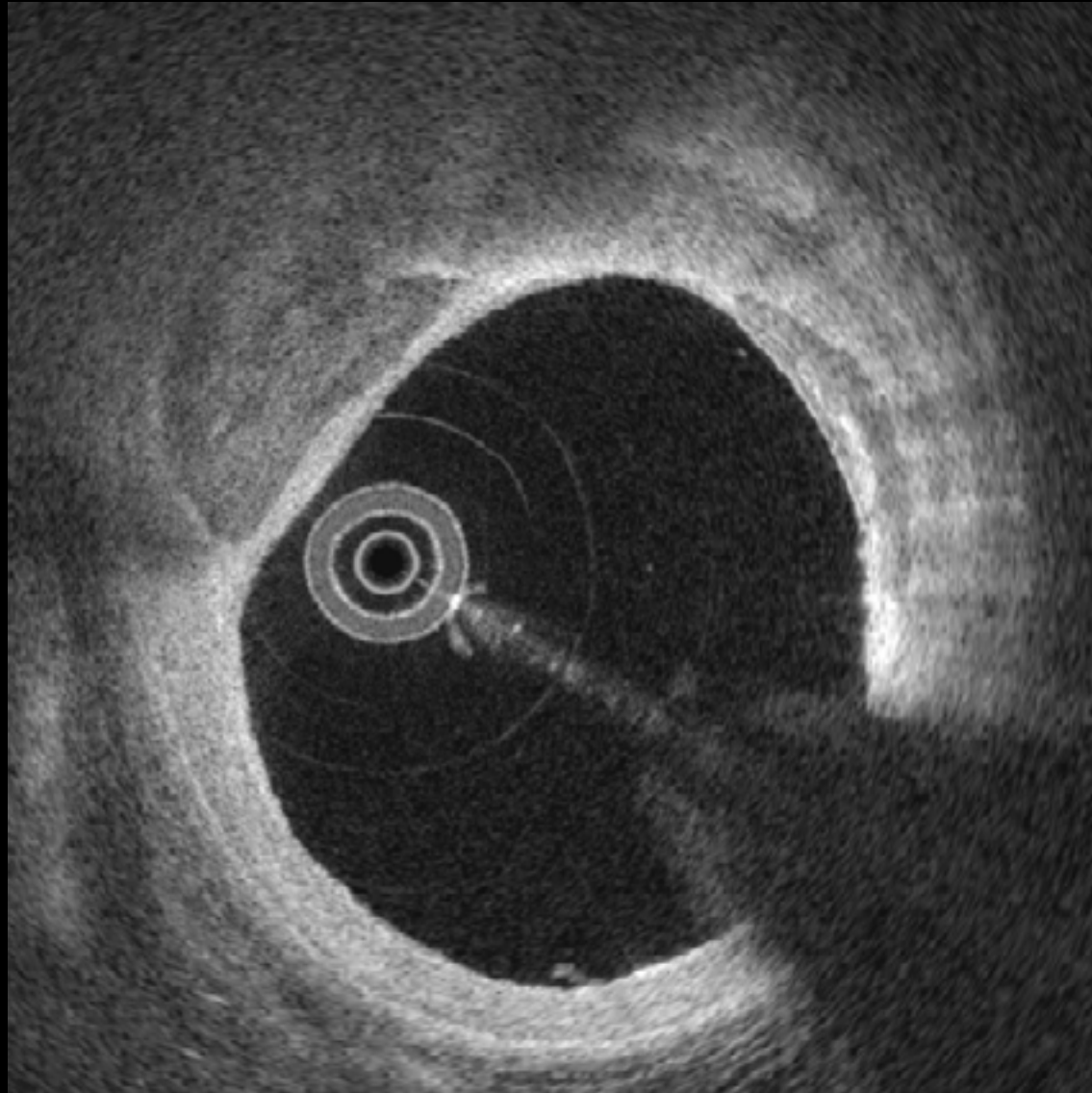


14

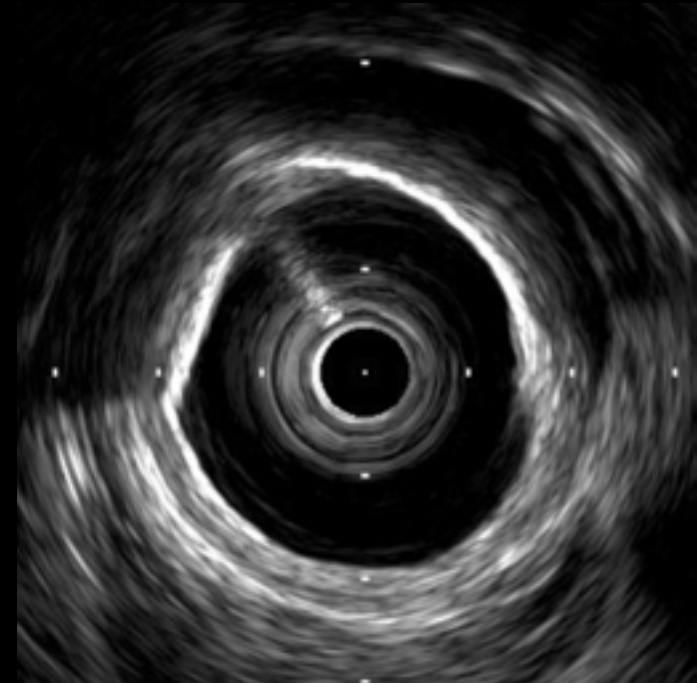
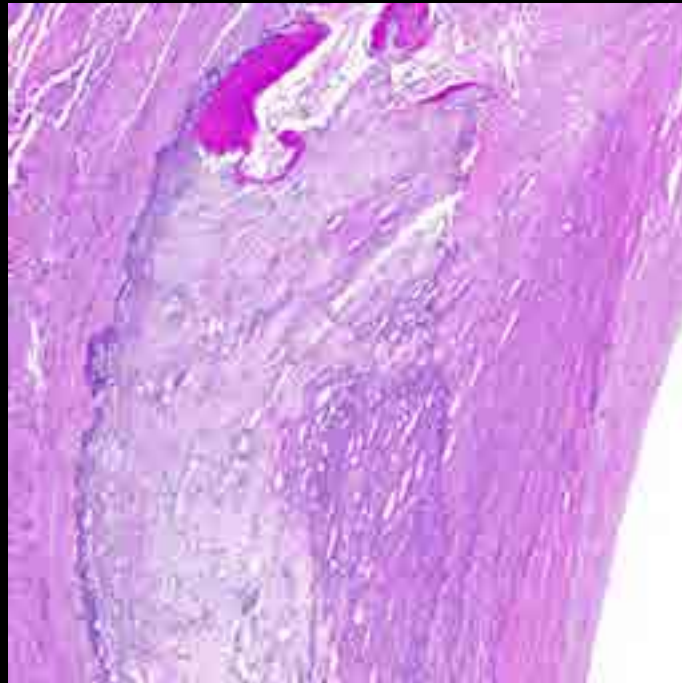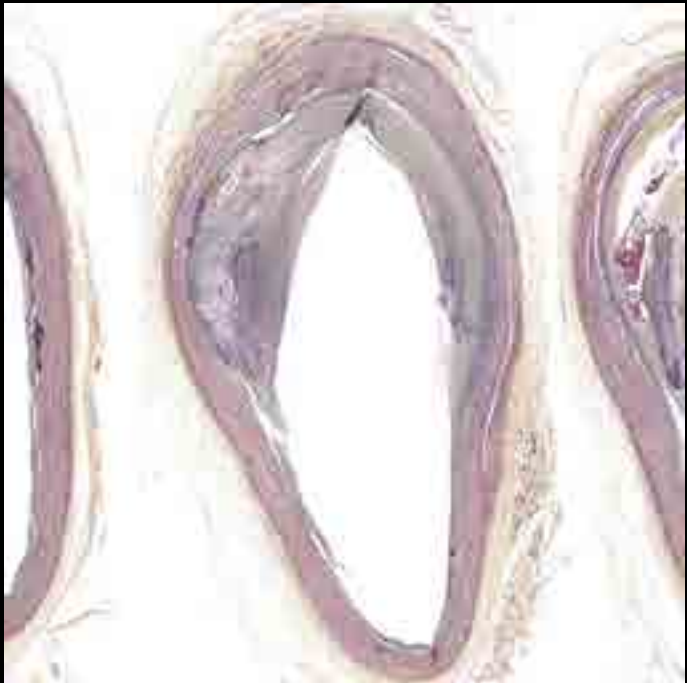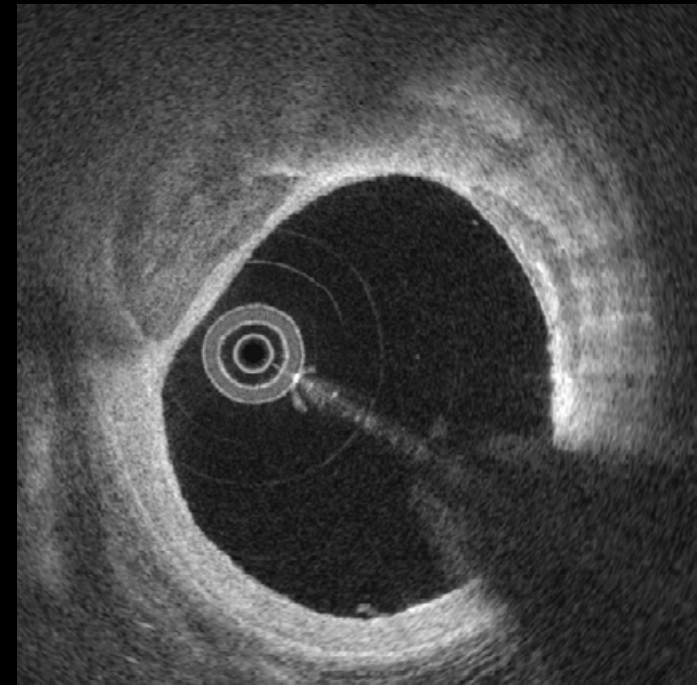
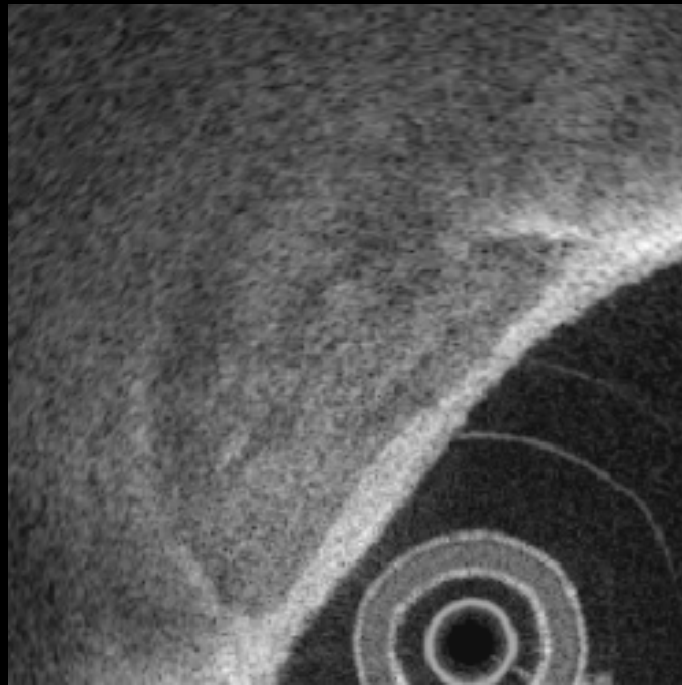


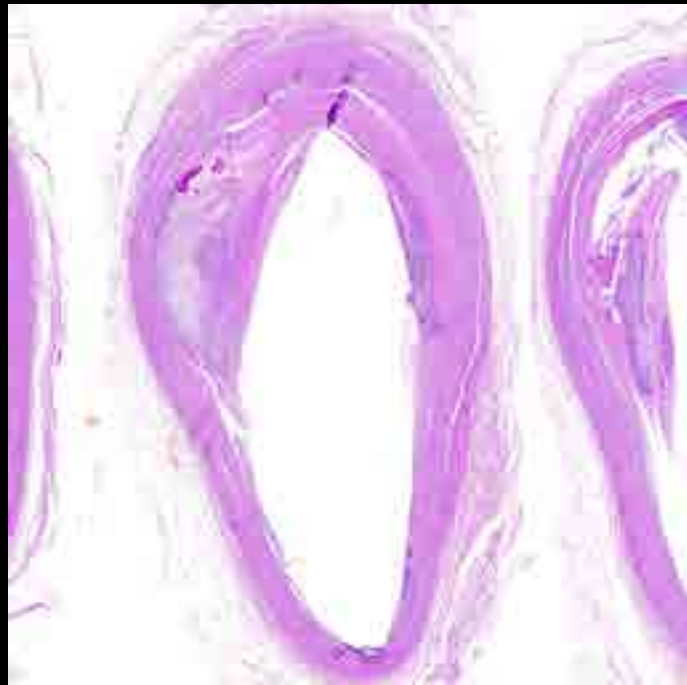Intimal Calcification

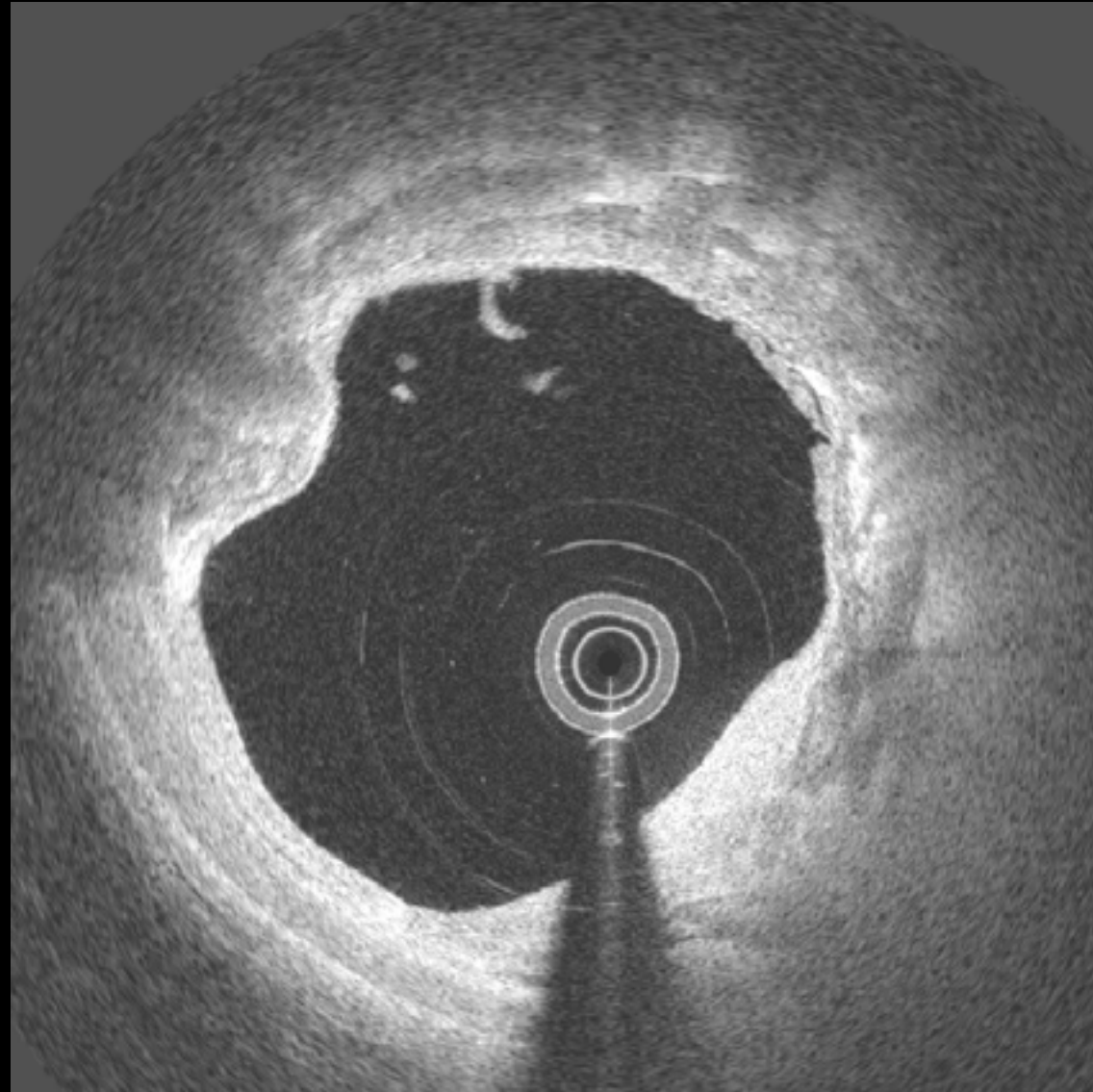
15



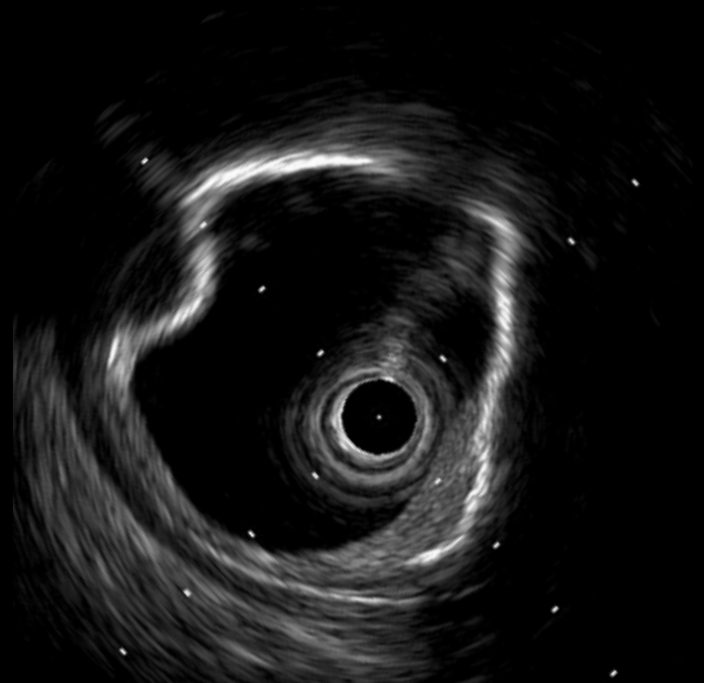
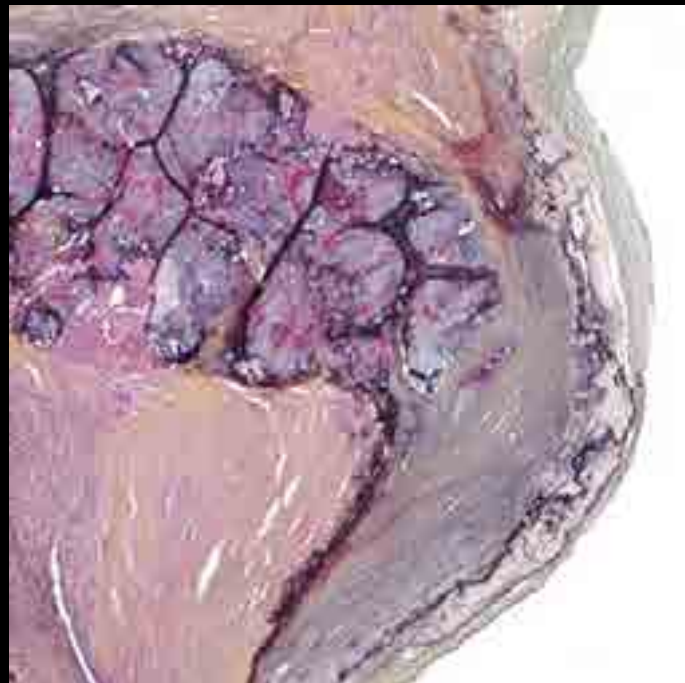
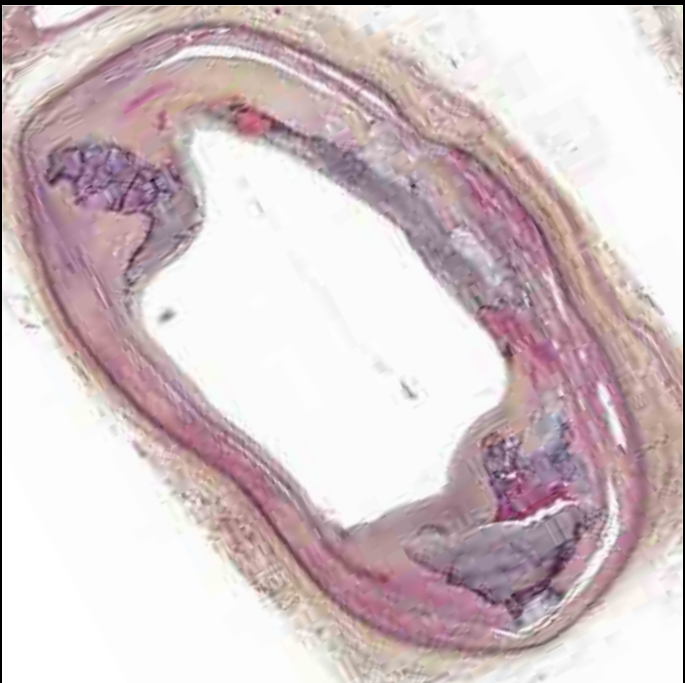
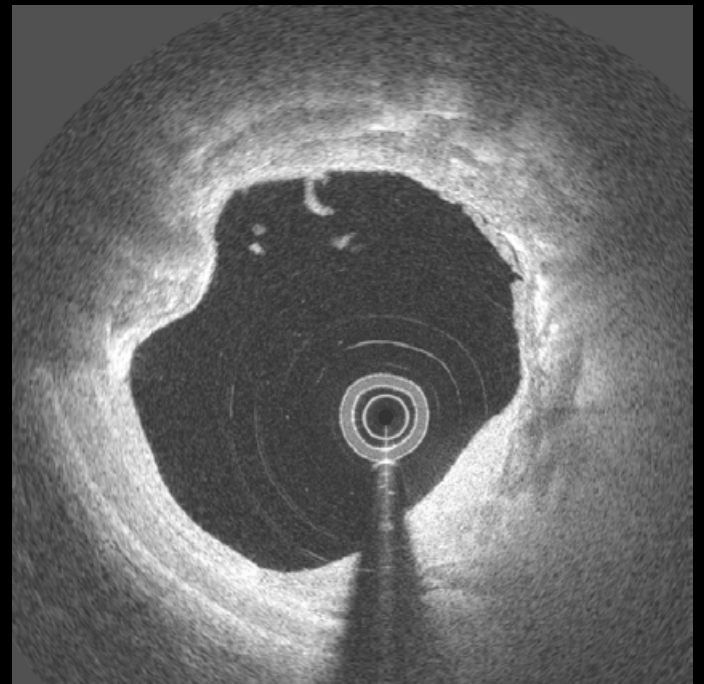
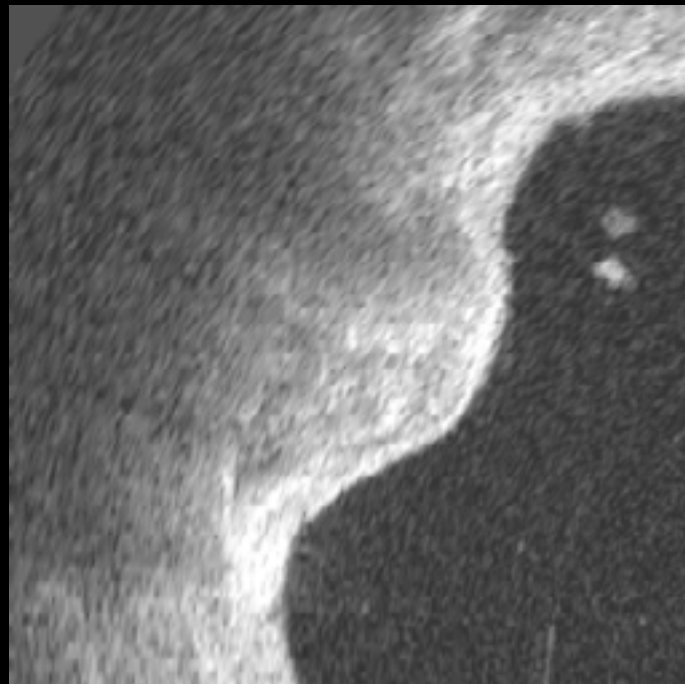
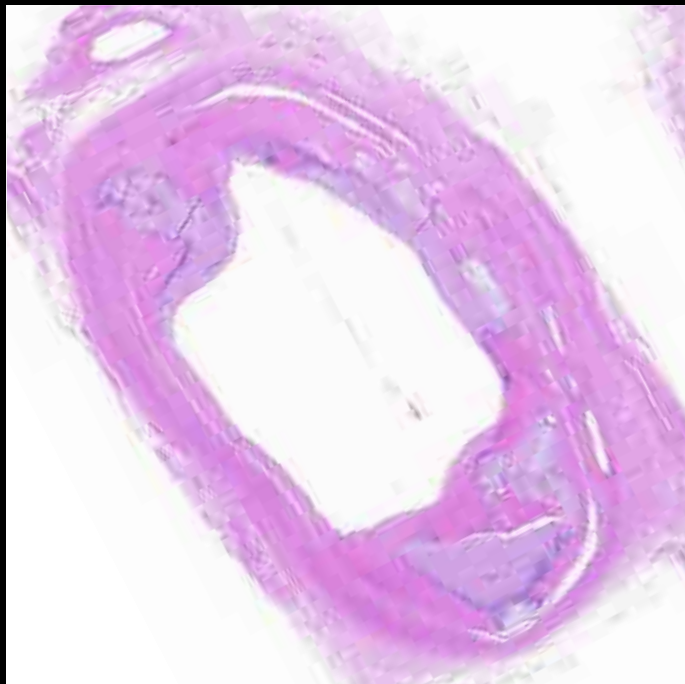
15



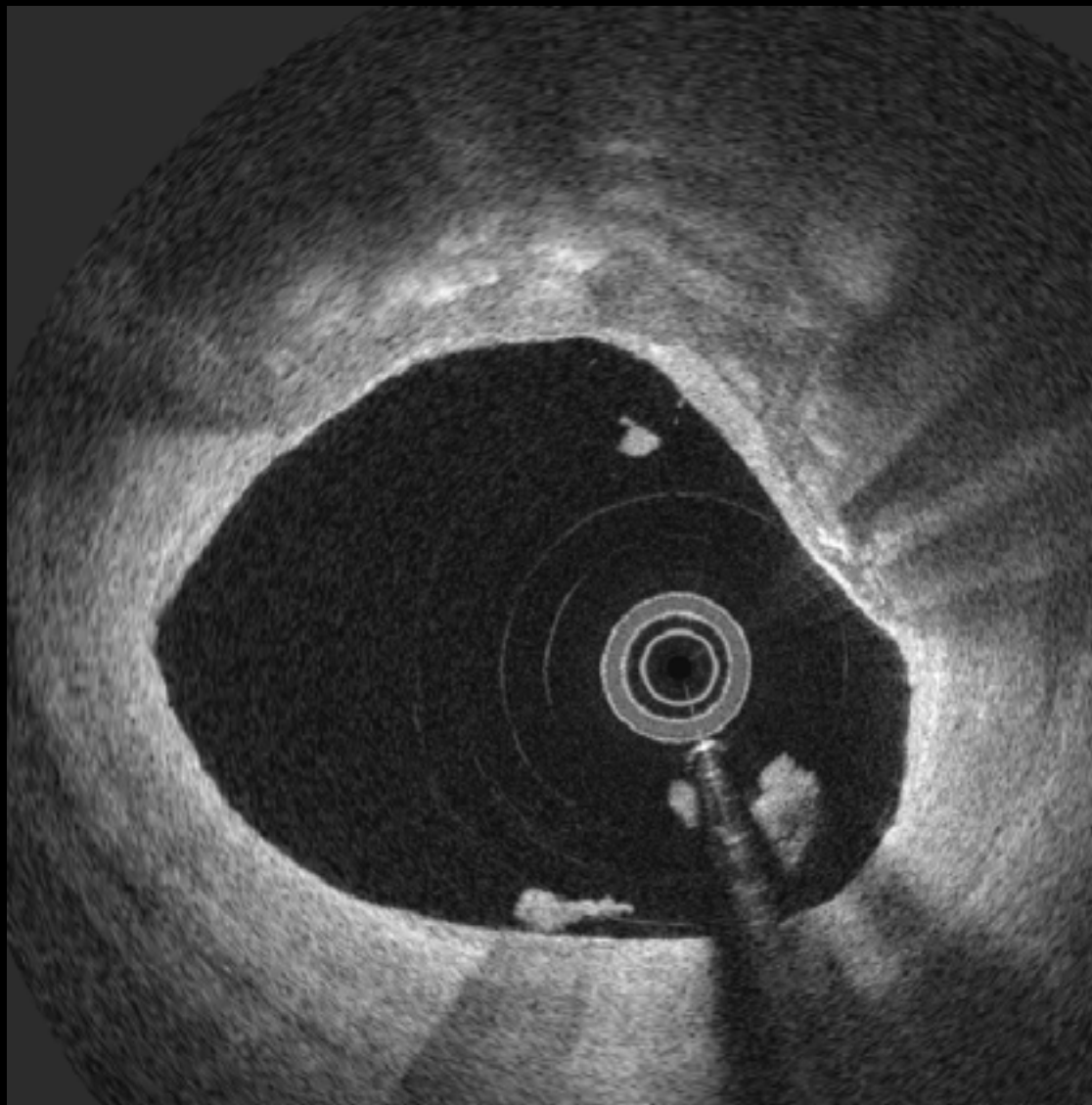
16



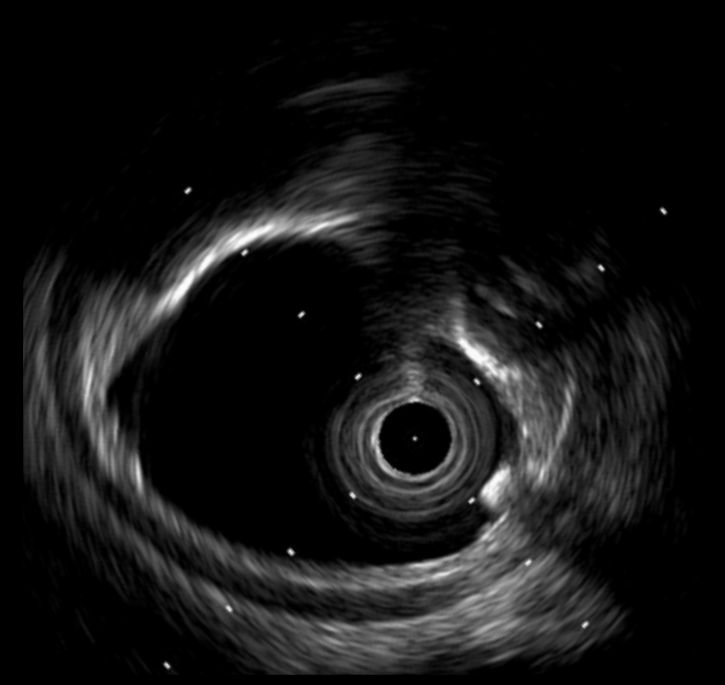
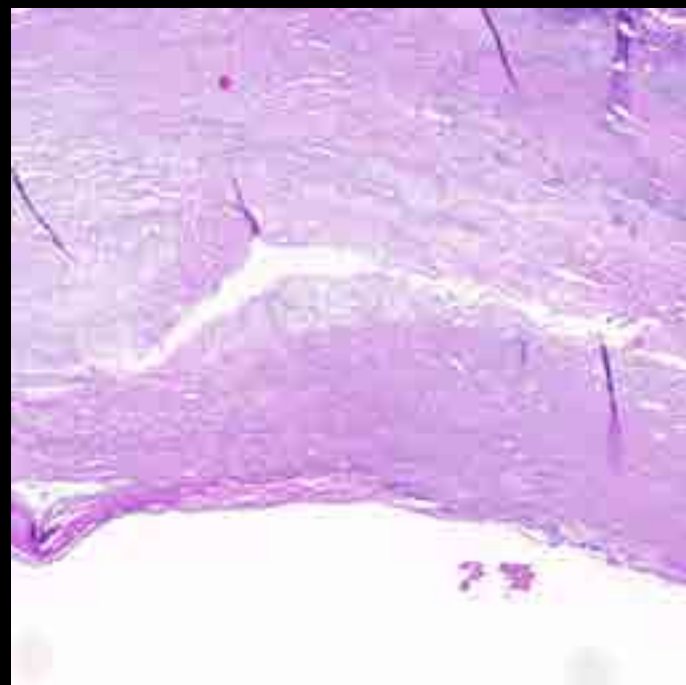
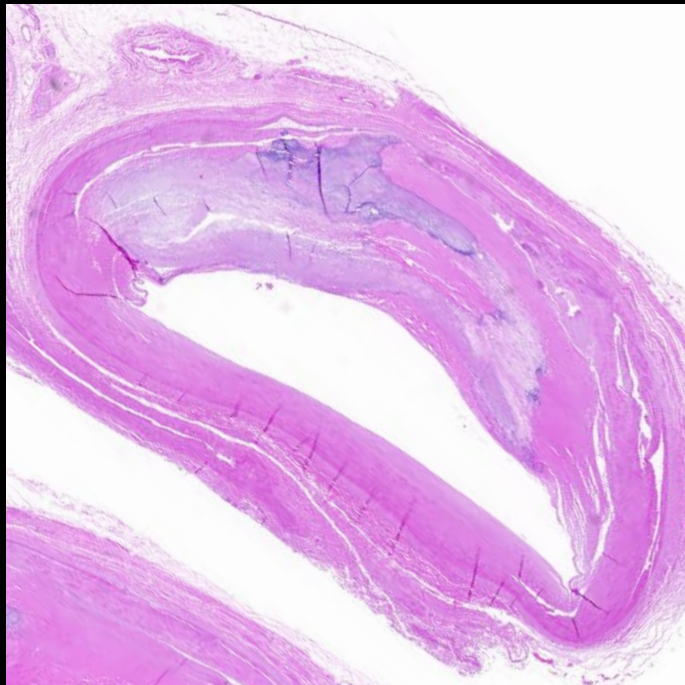
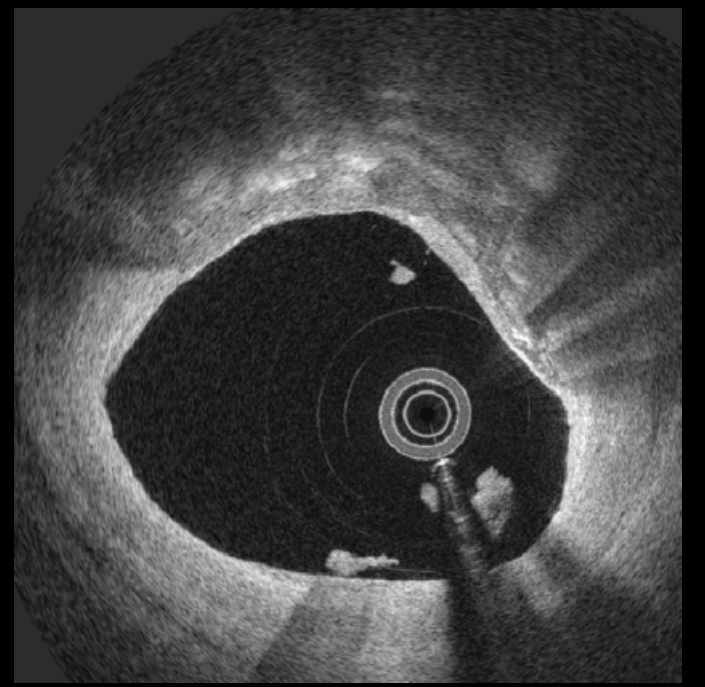
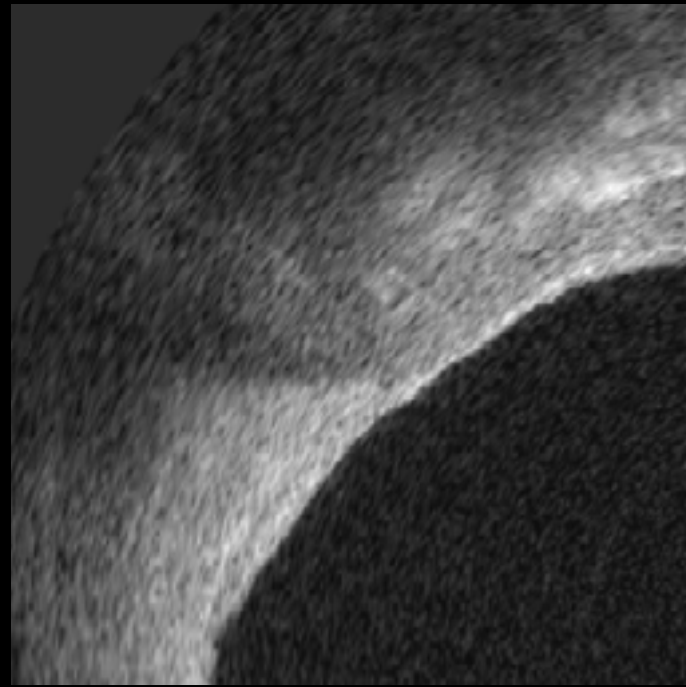
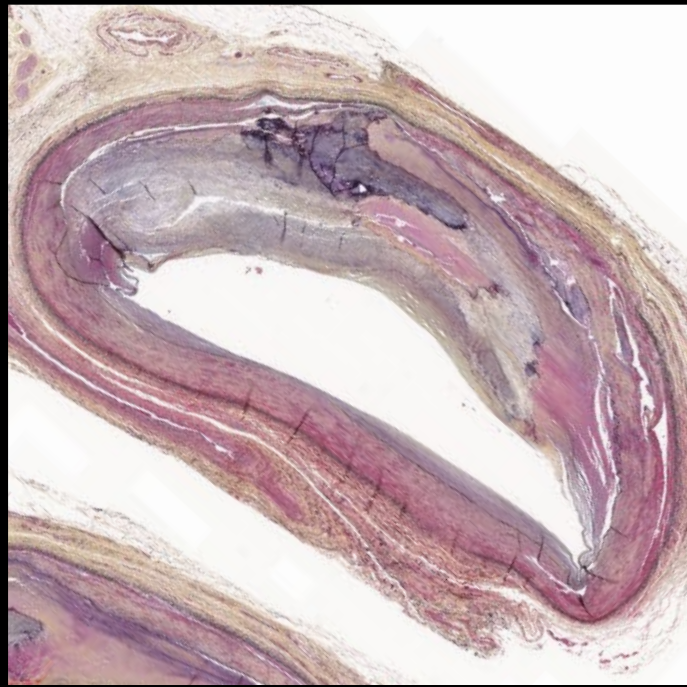
16



17

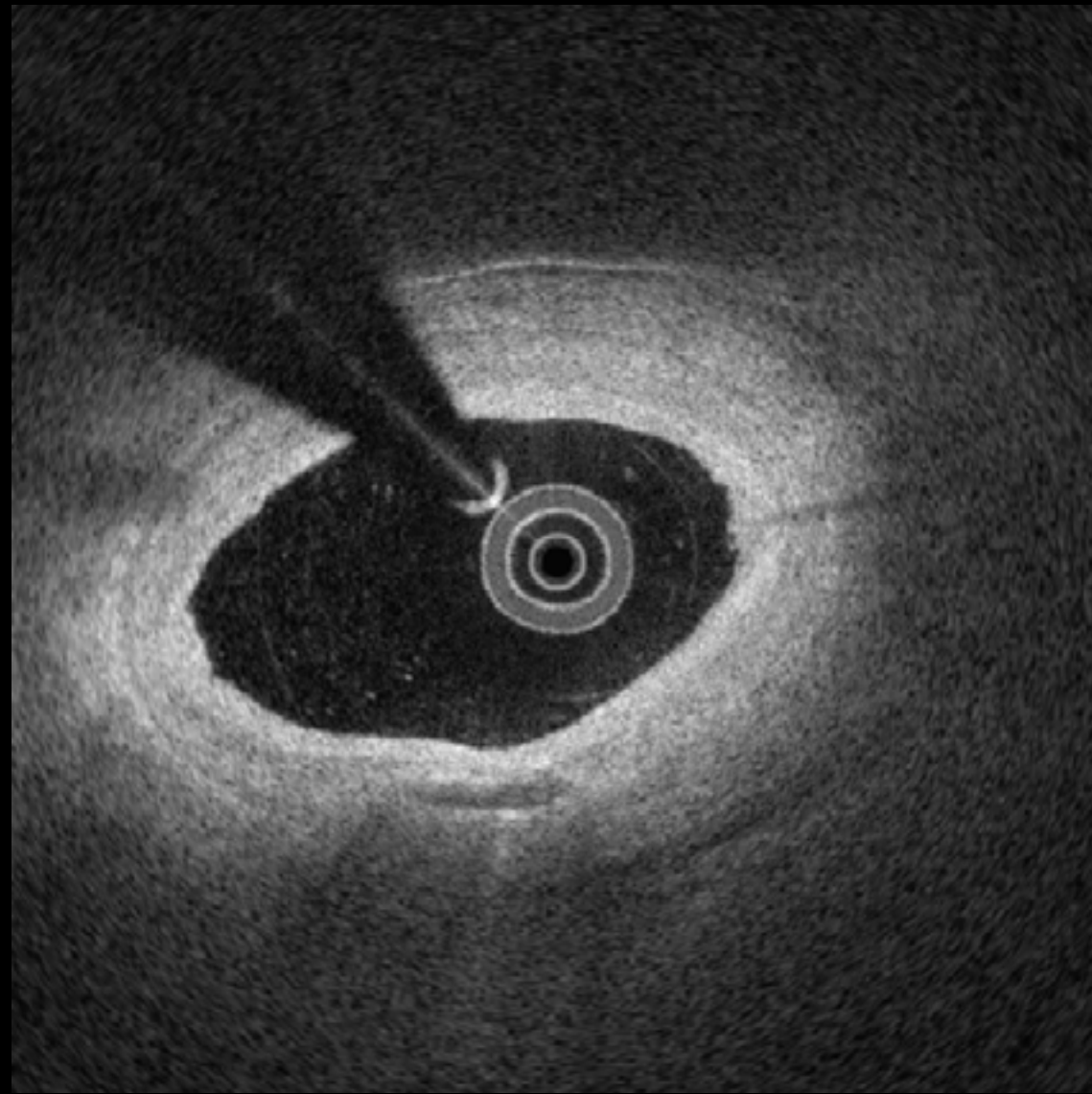


17

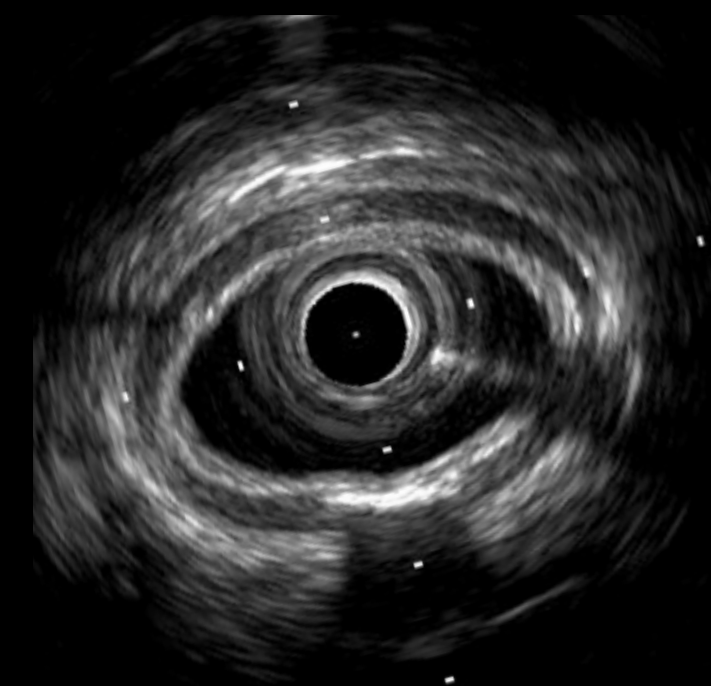
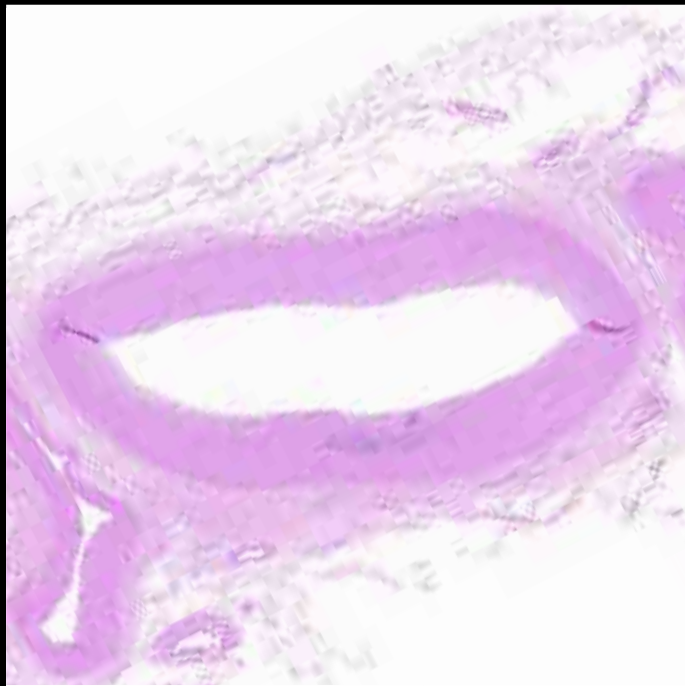
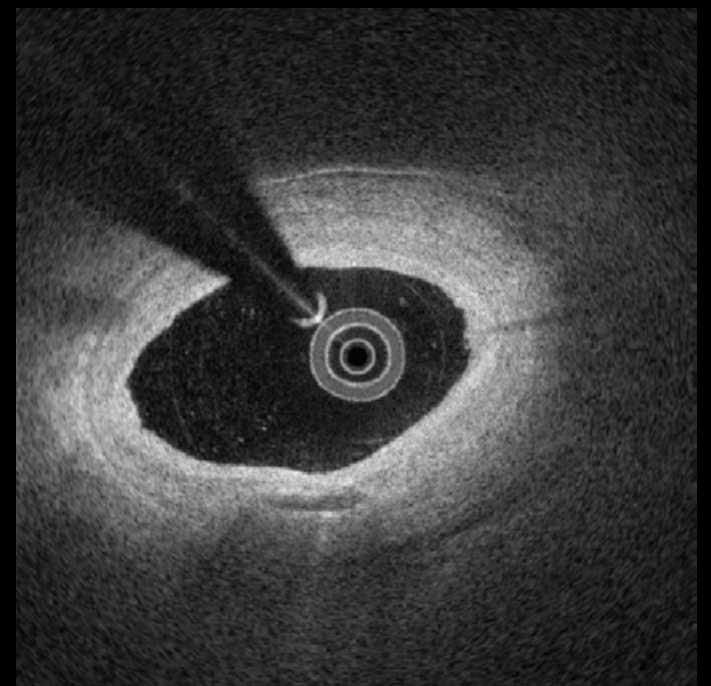
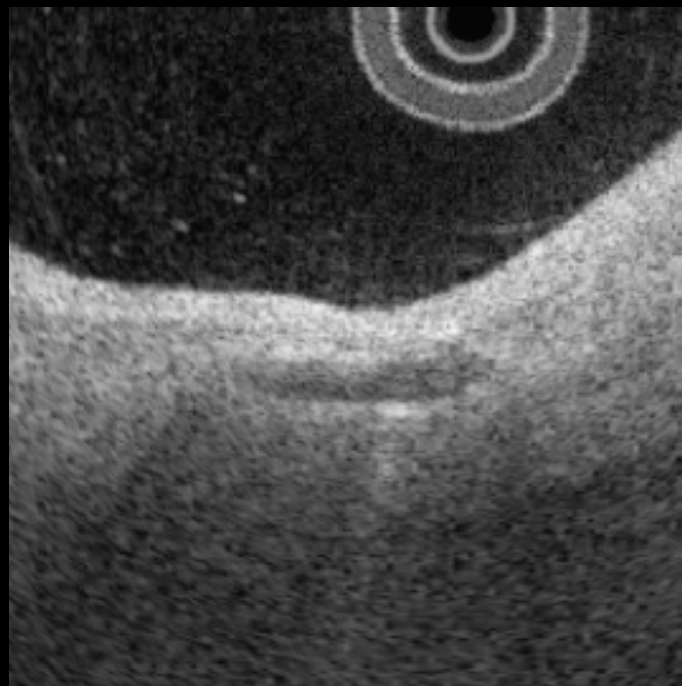
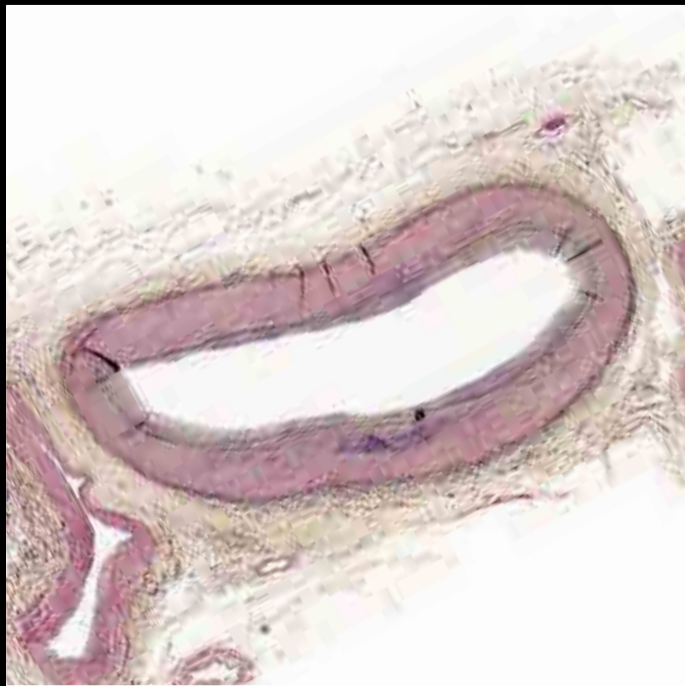

Medial Calcification

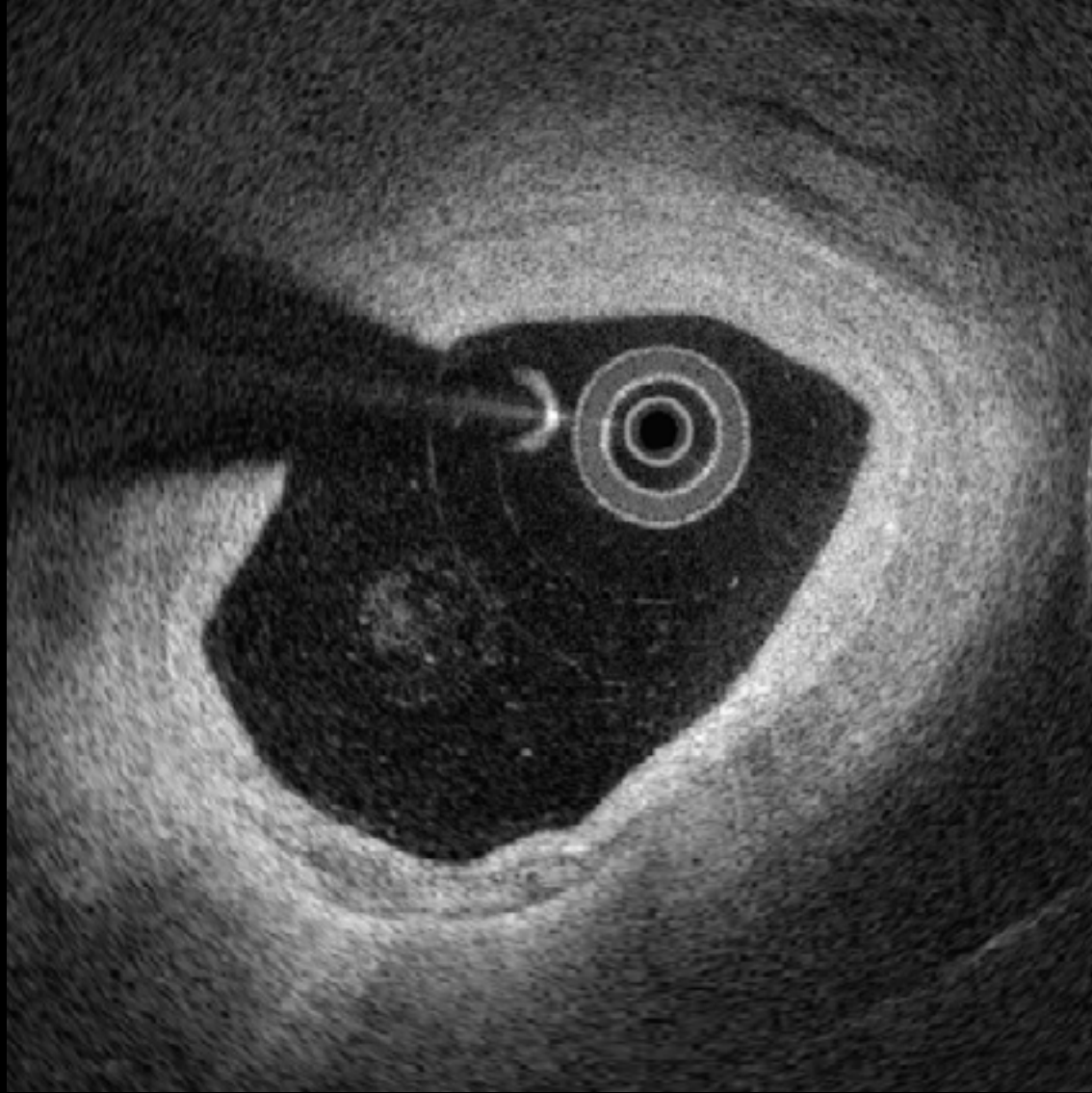
#18



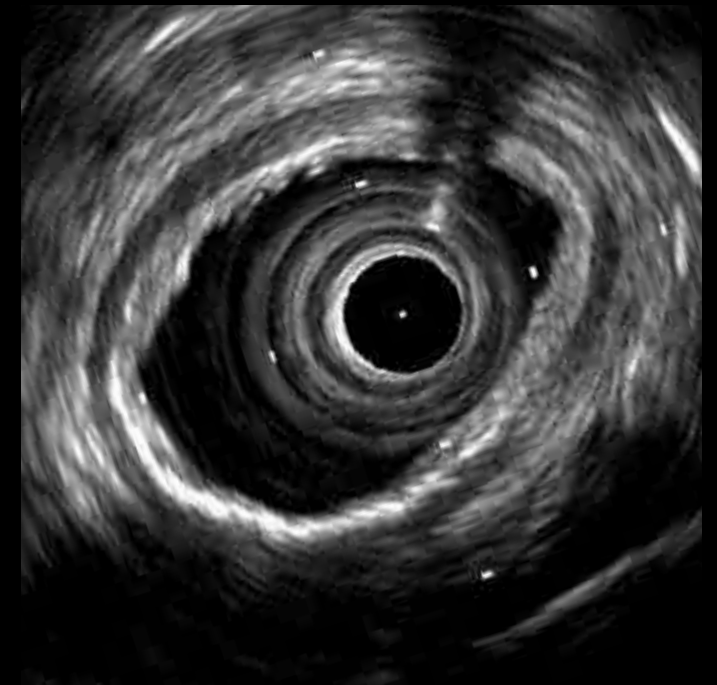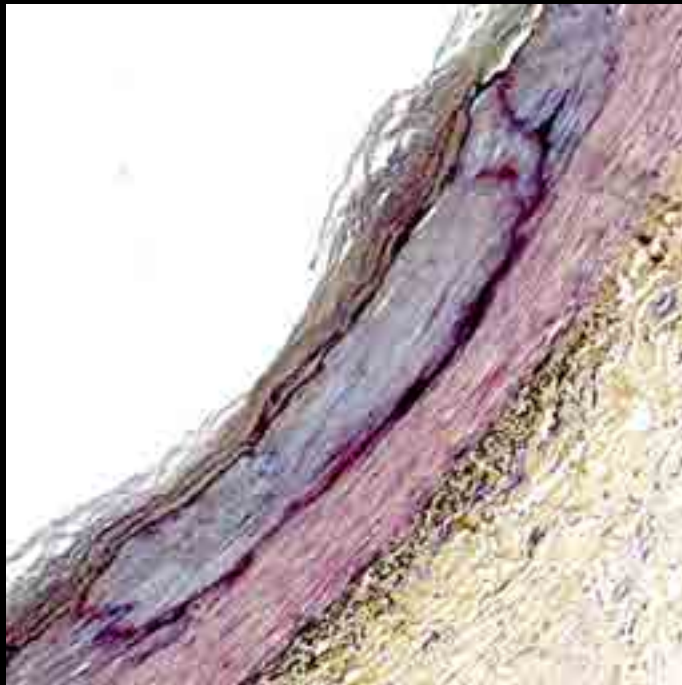
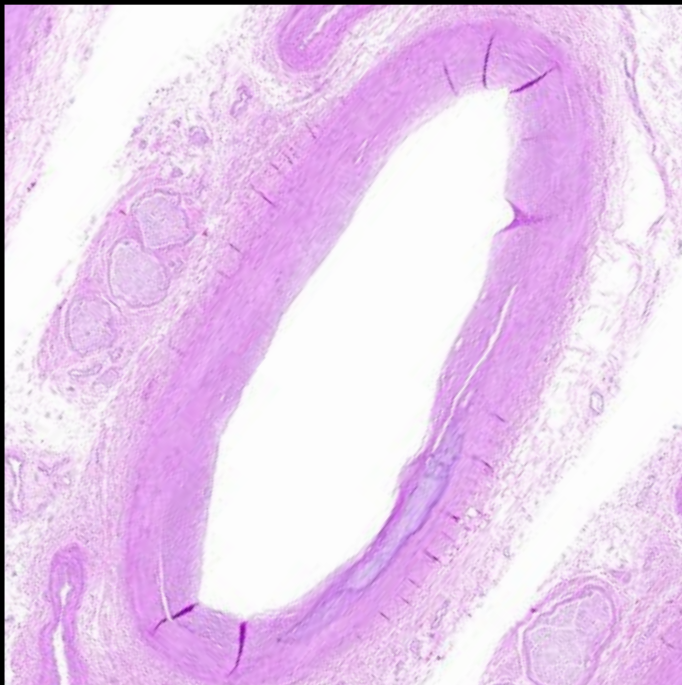
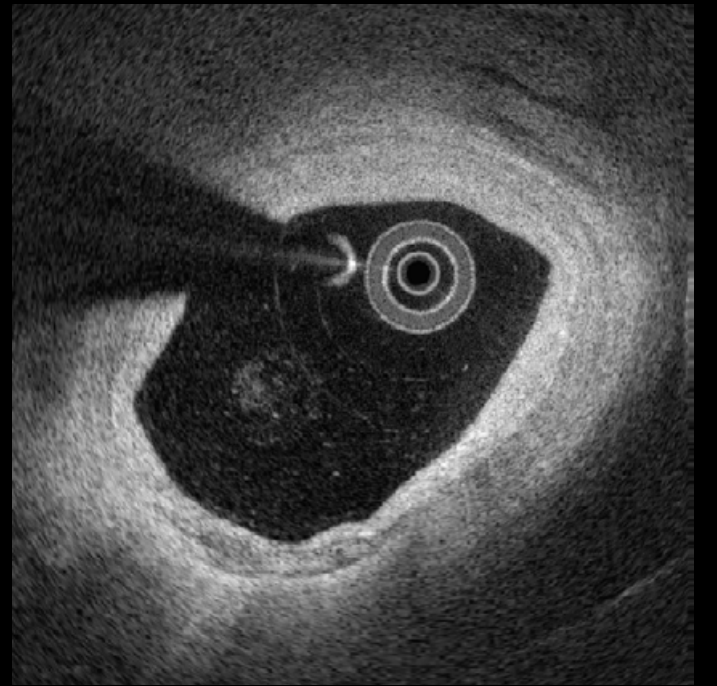
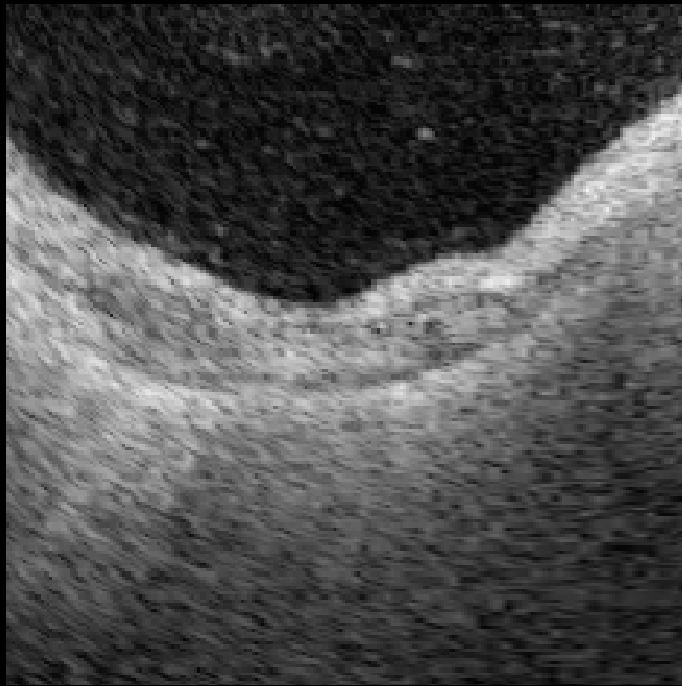
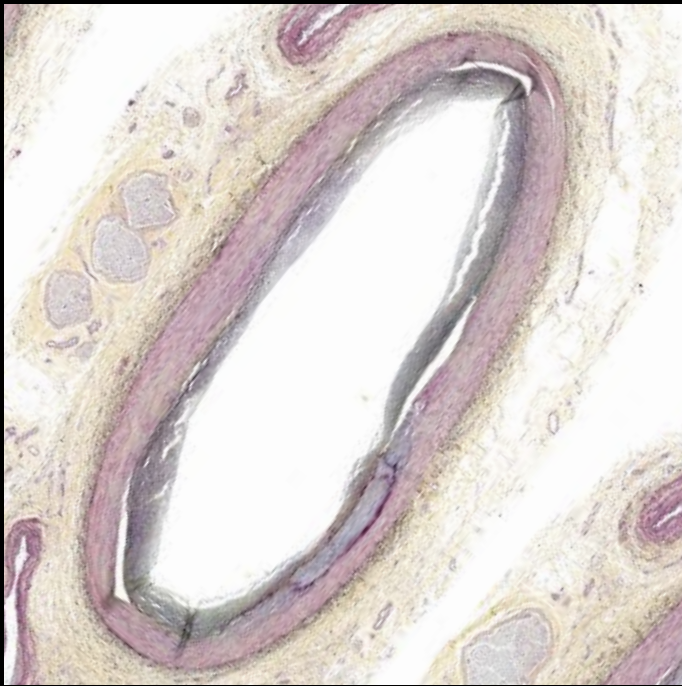
#18



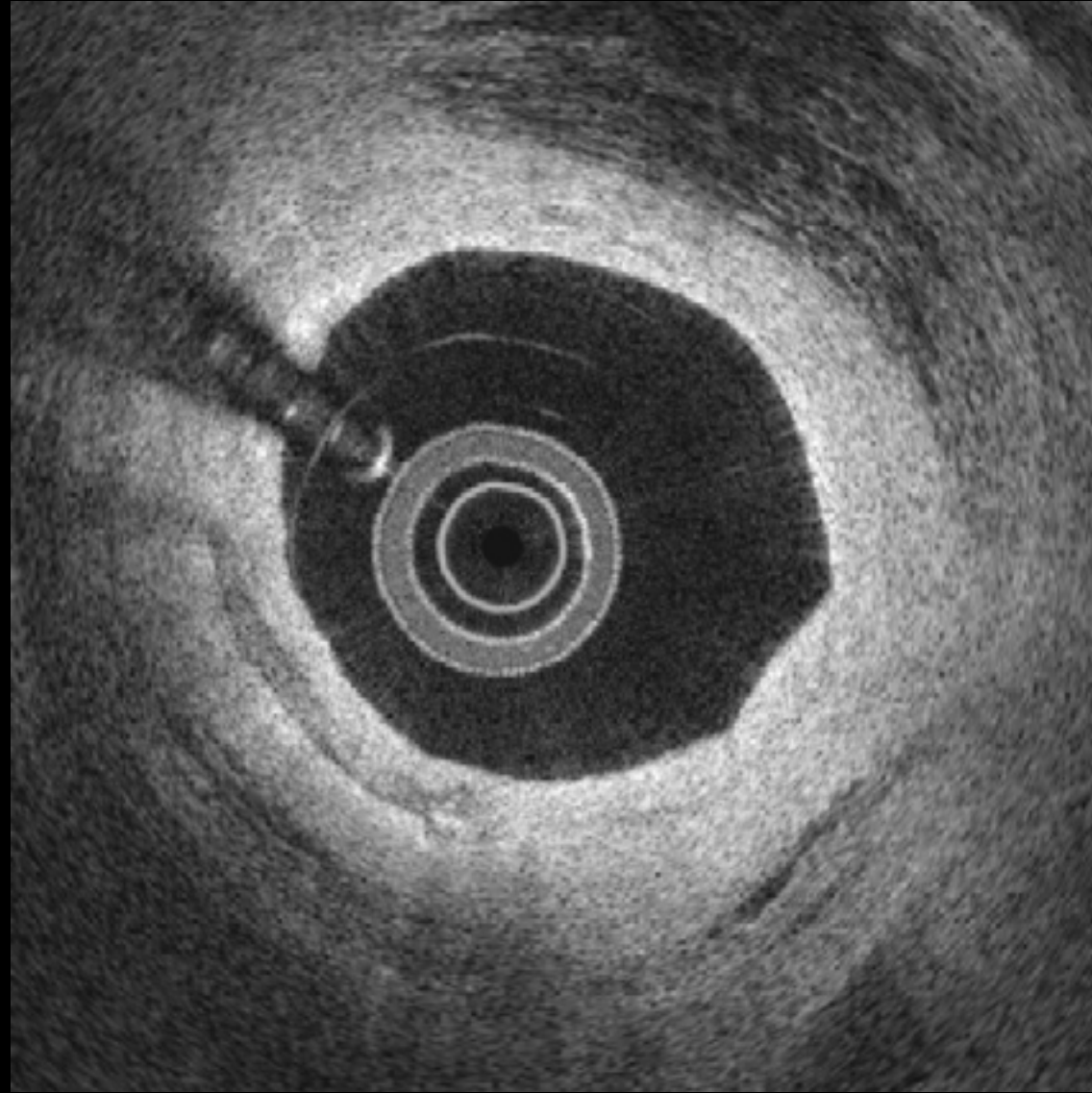
19



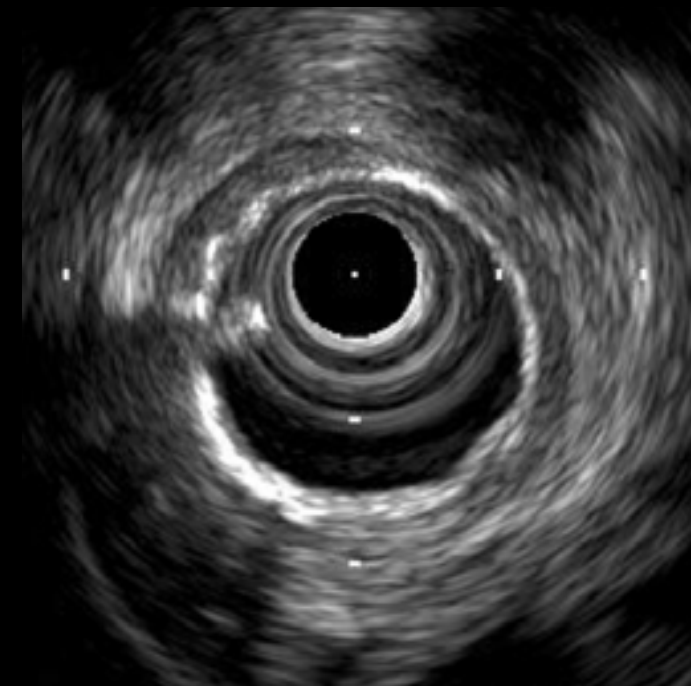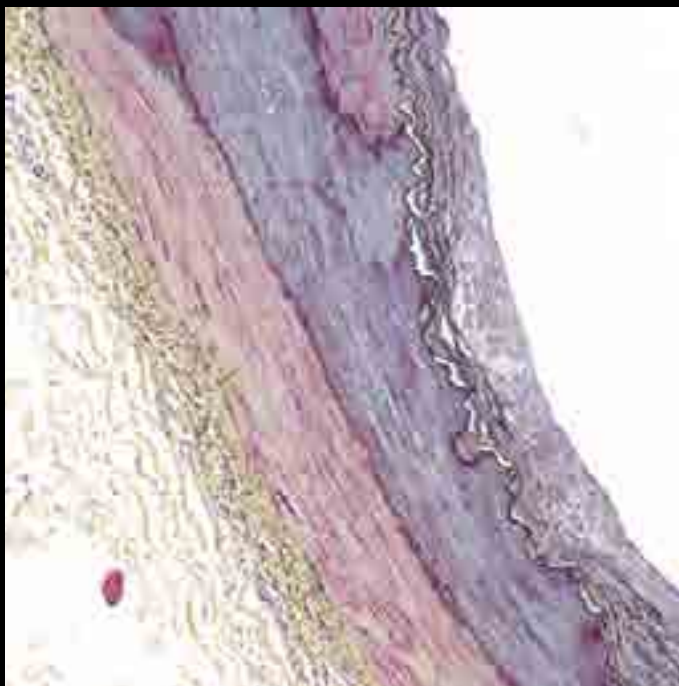
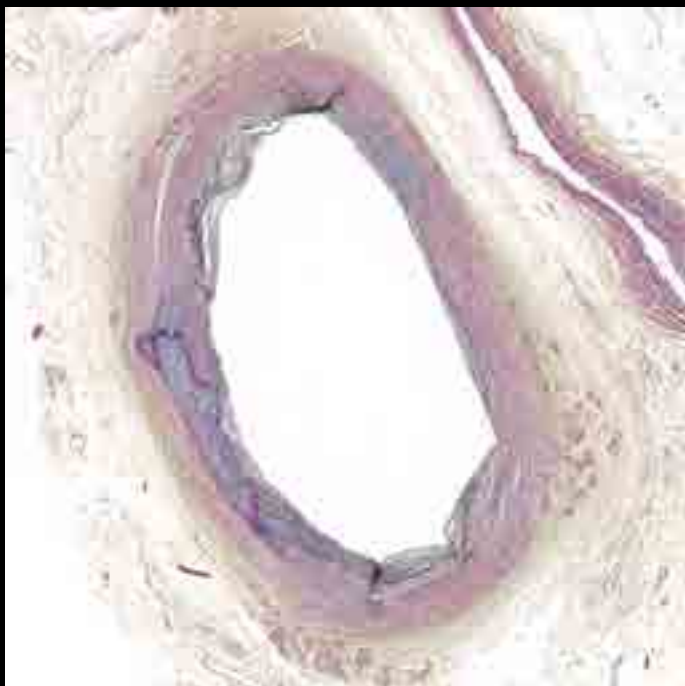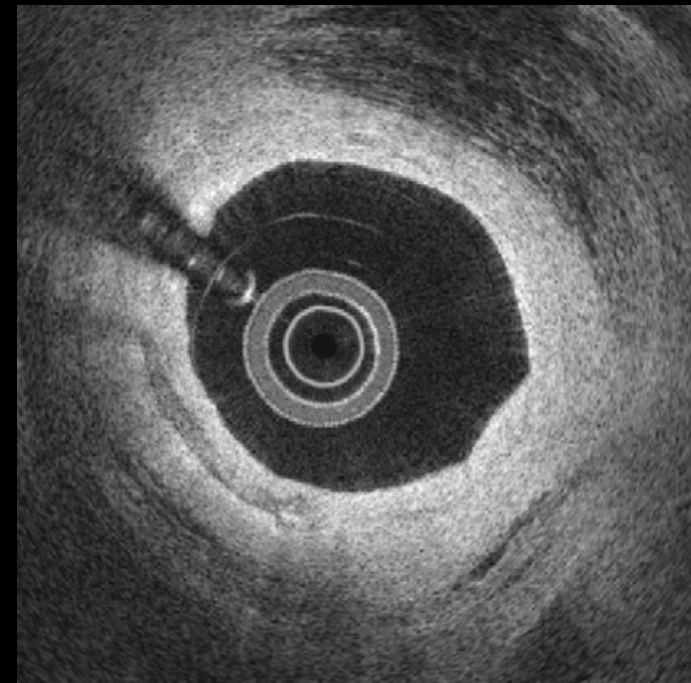
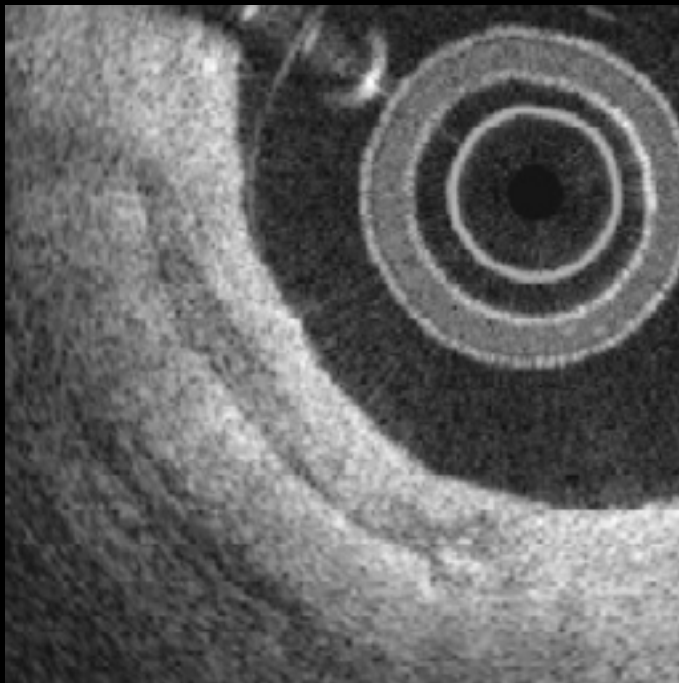
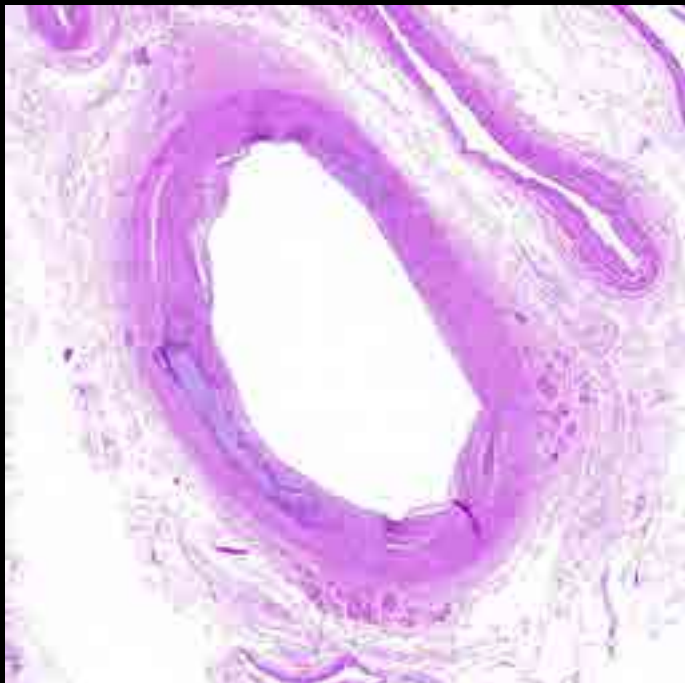
19



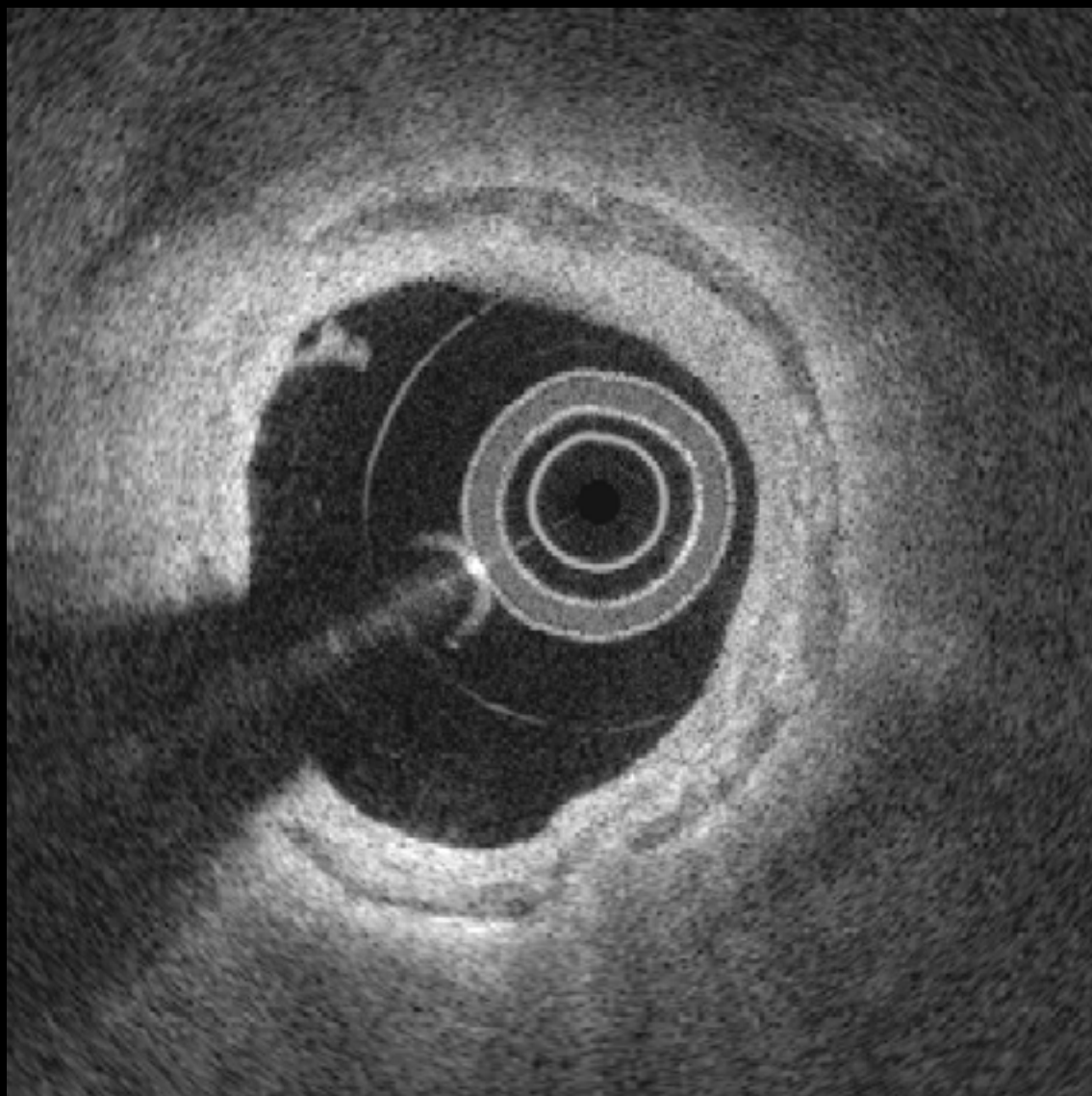
#20



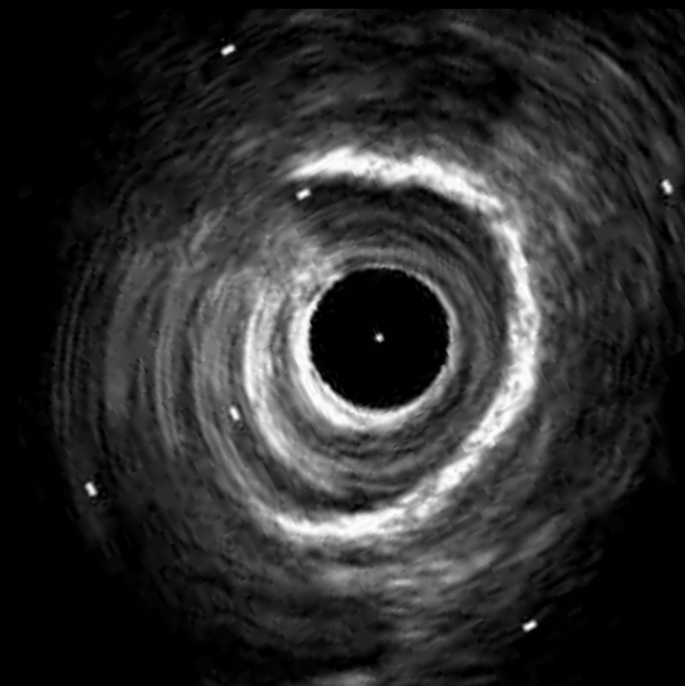
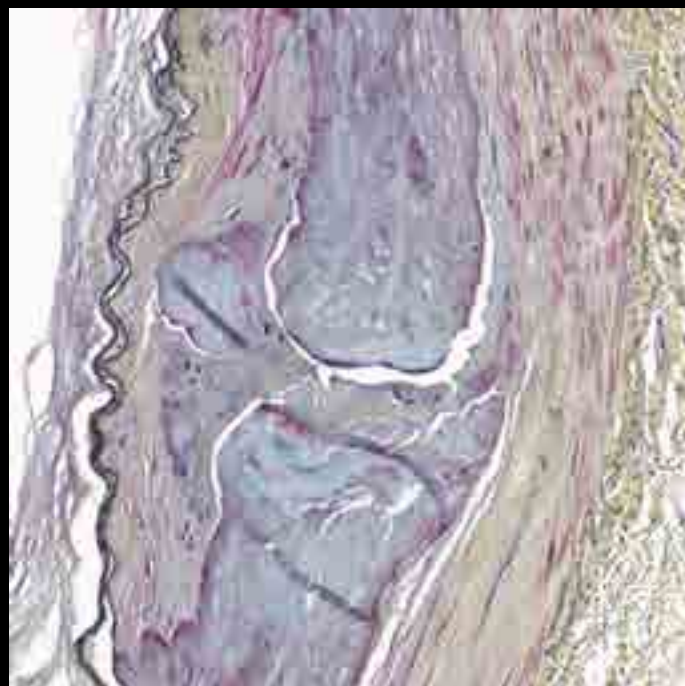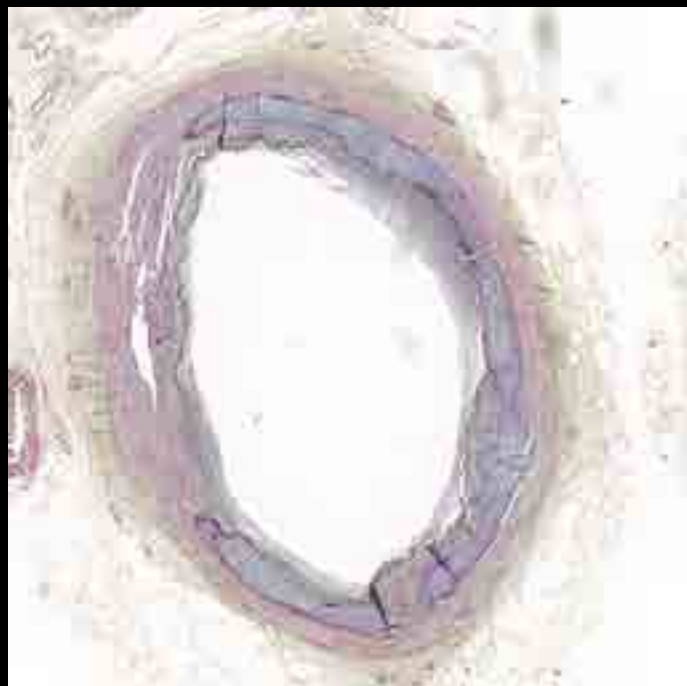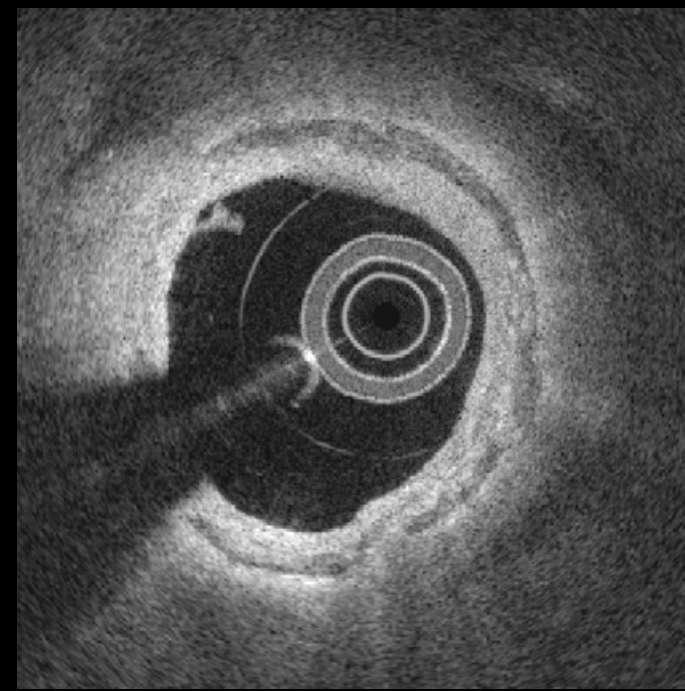
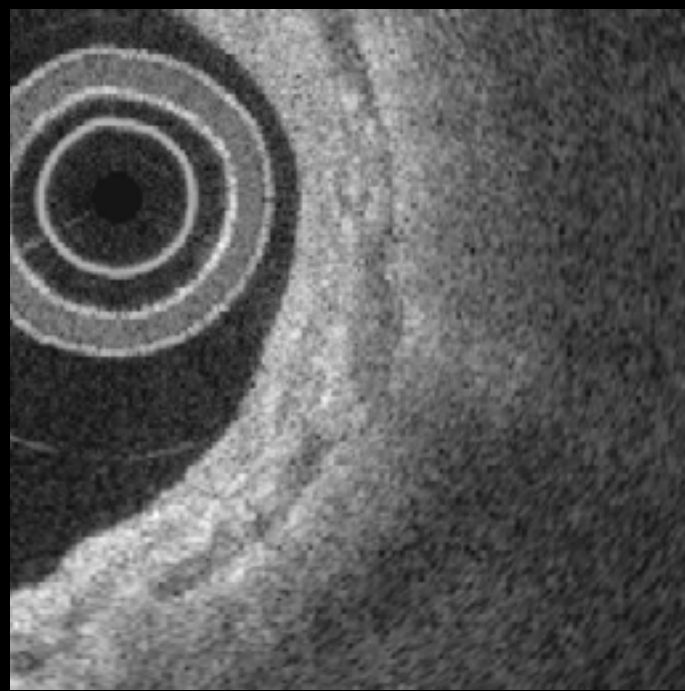
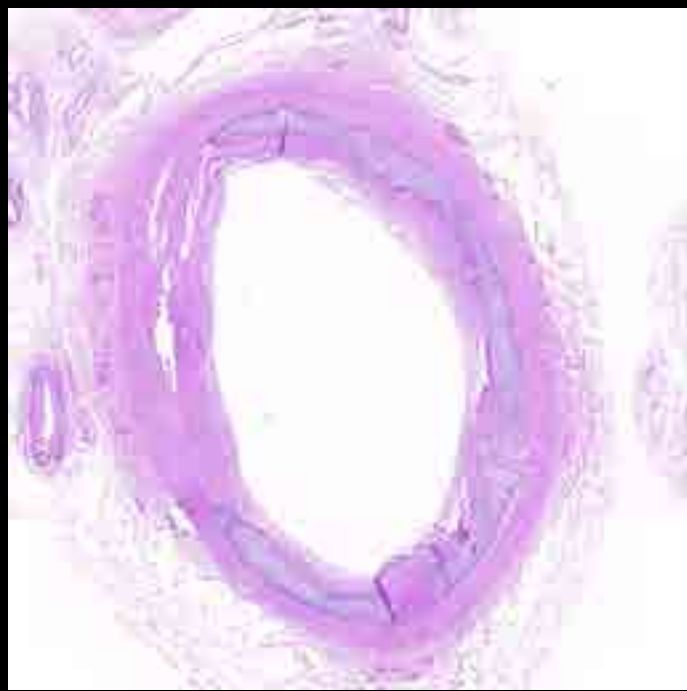
#20



#21

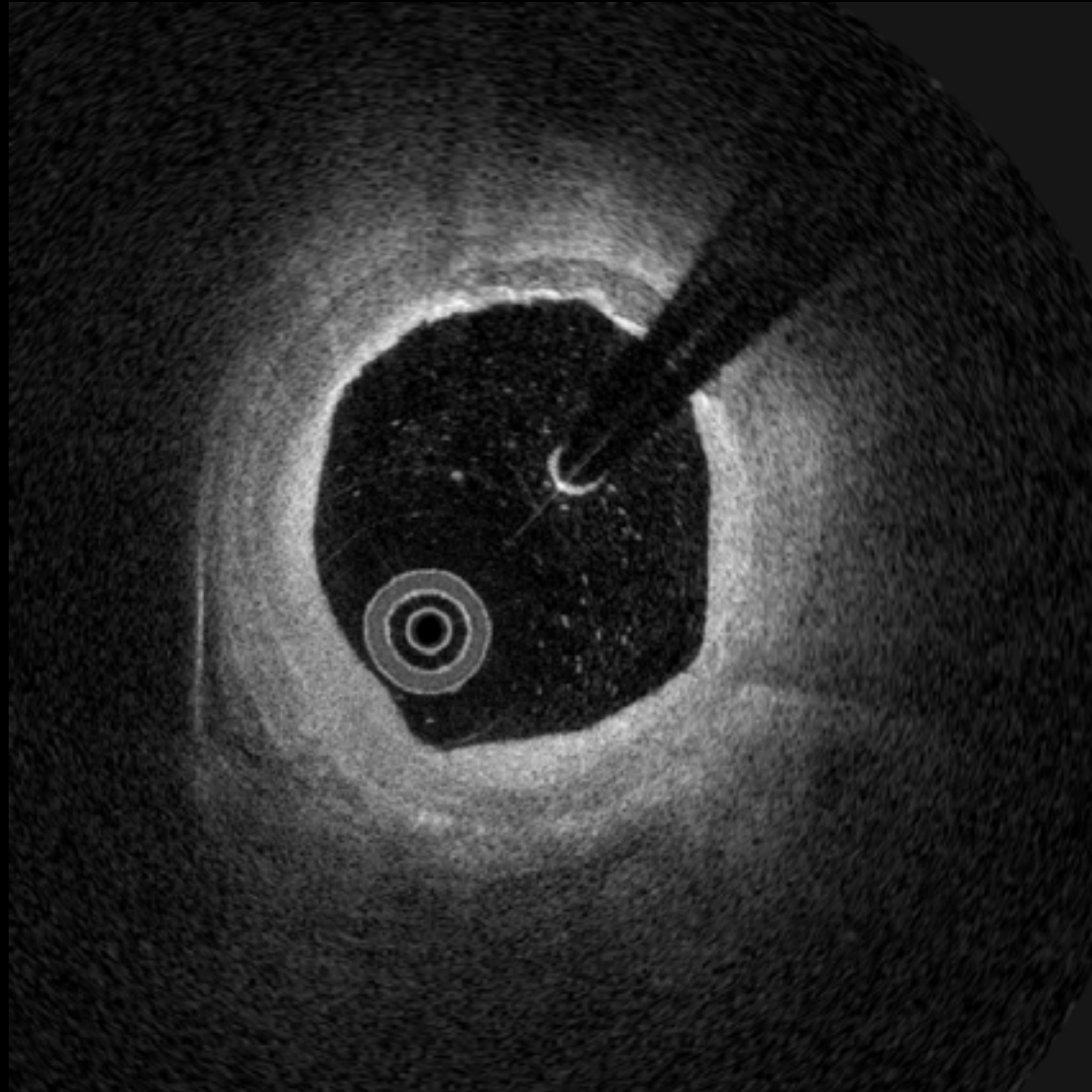


#21

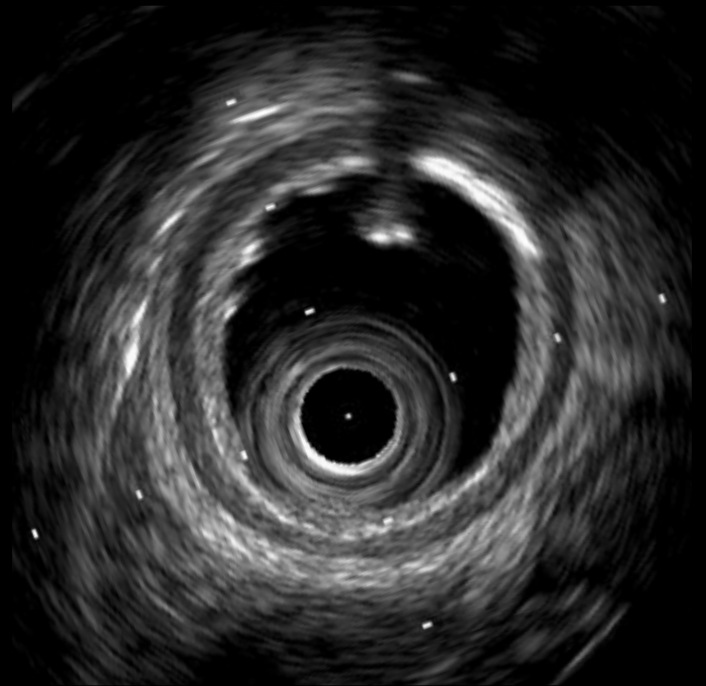
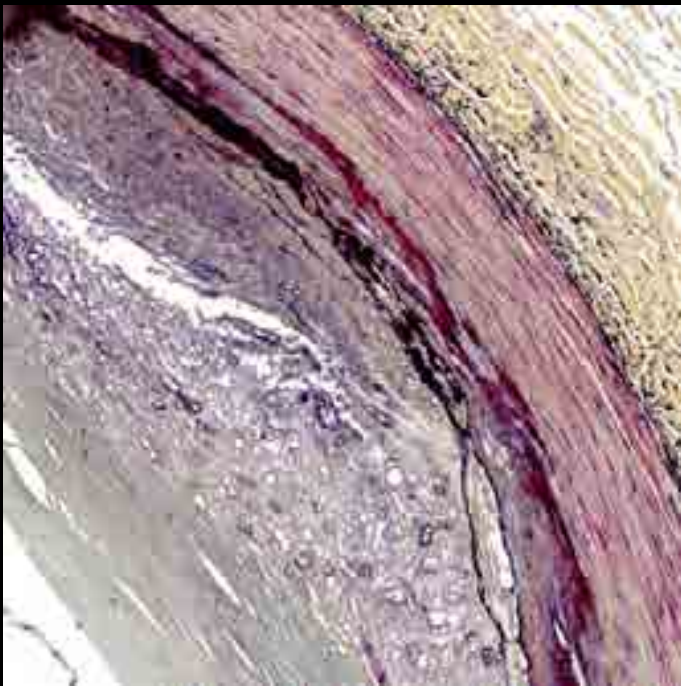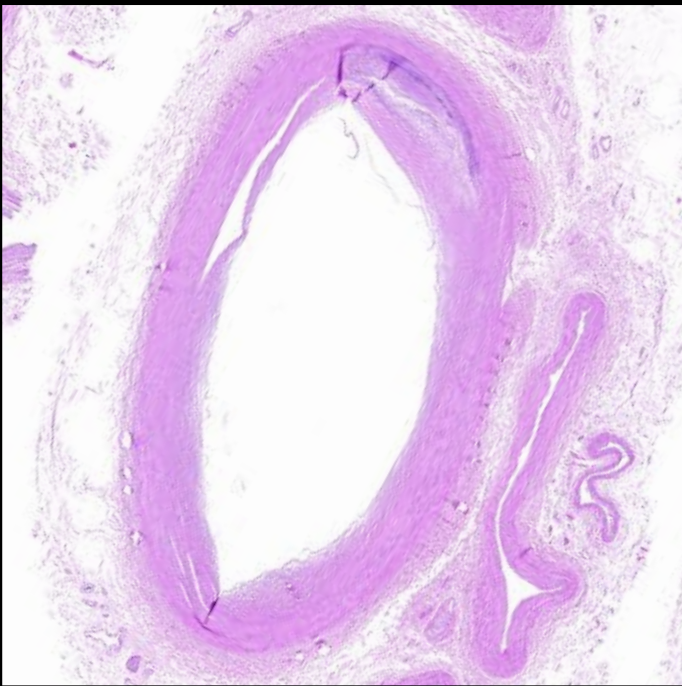
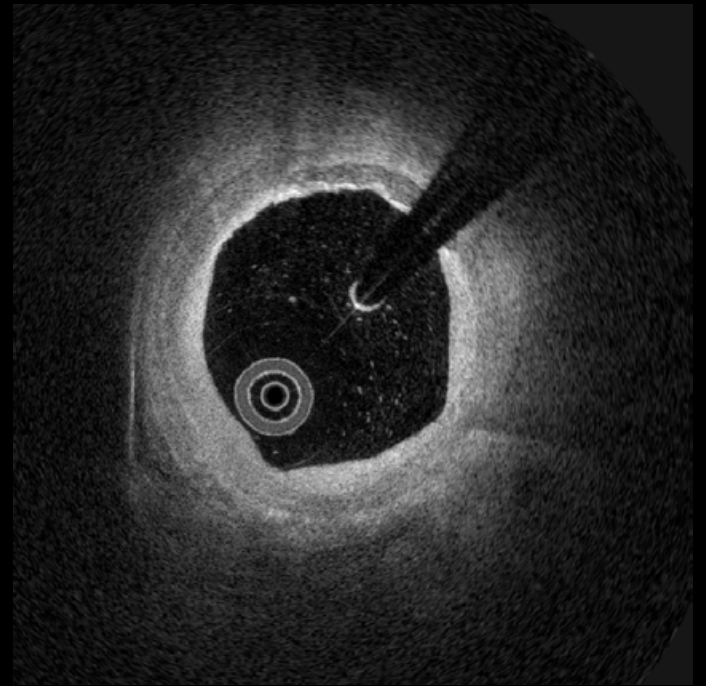
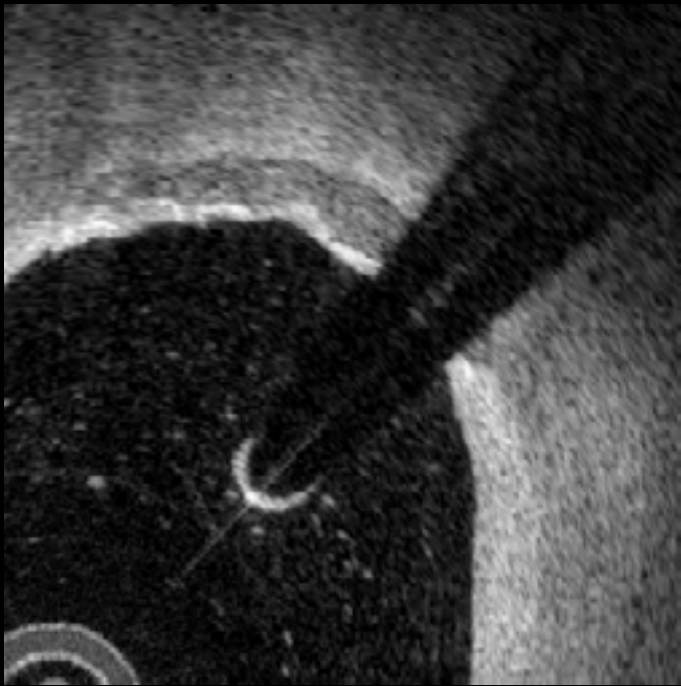
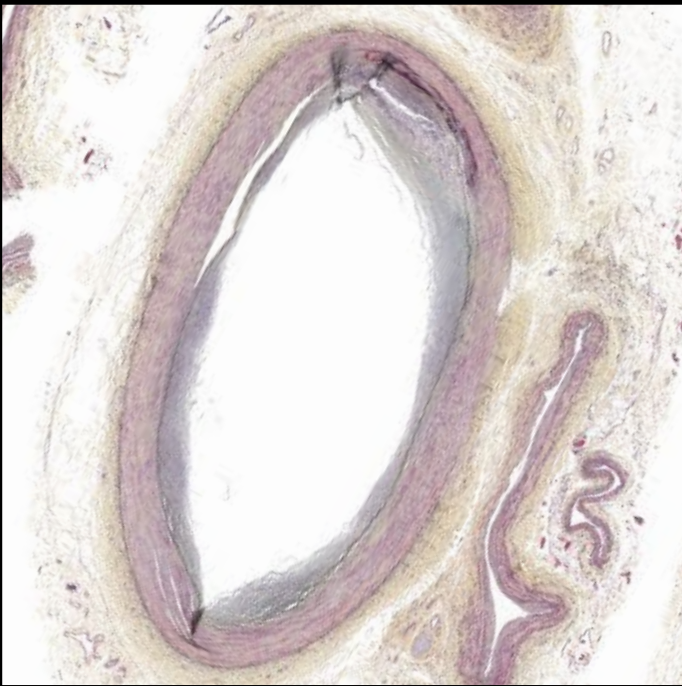


Fusion
calcification

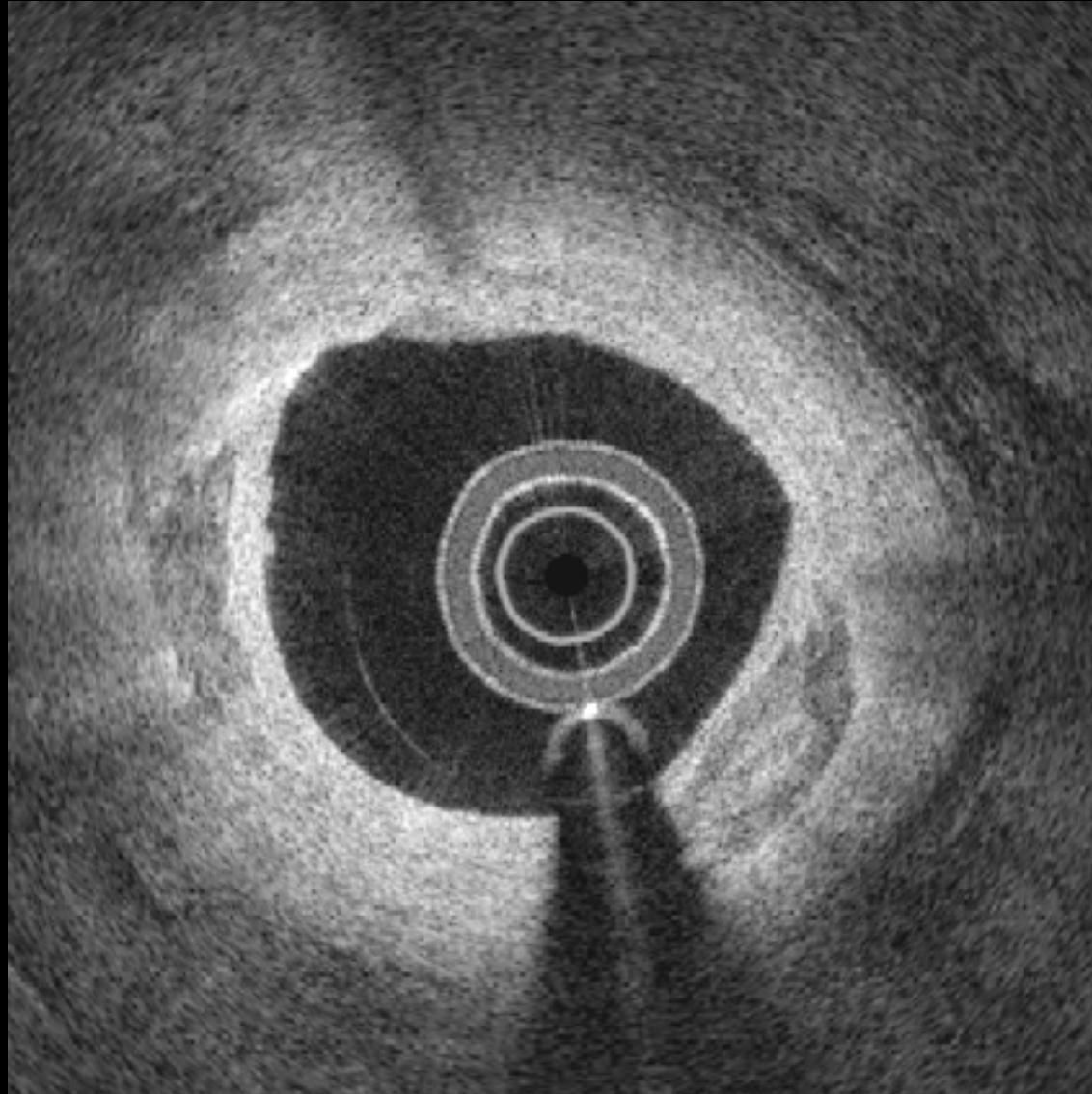
22



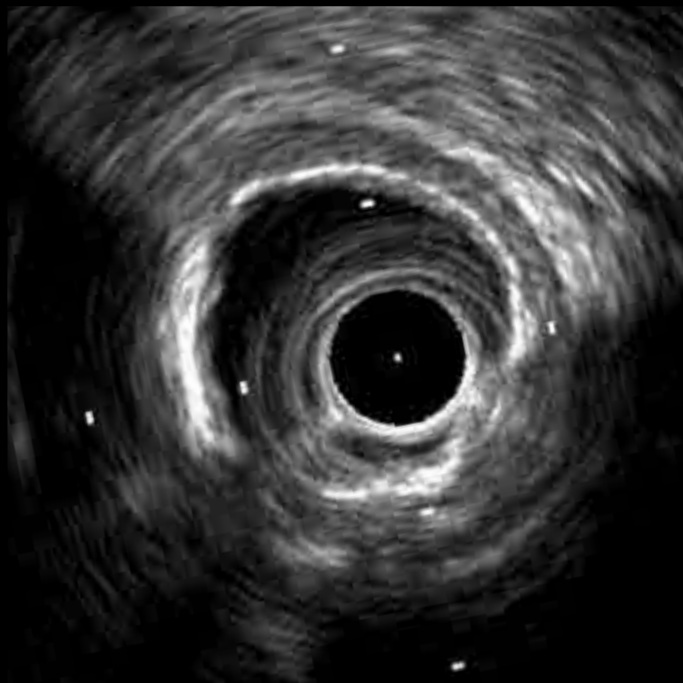
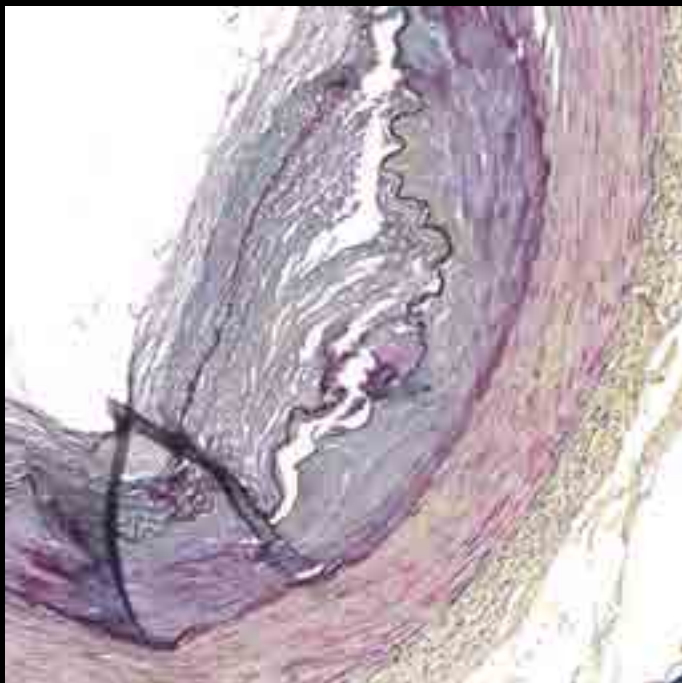
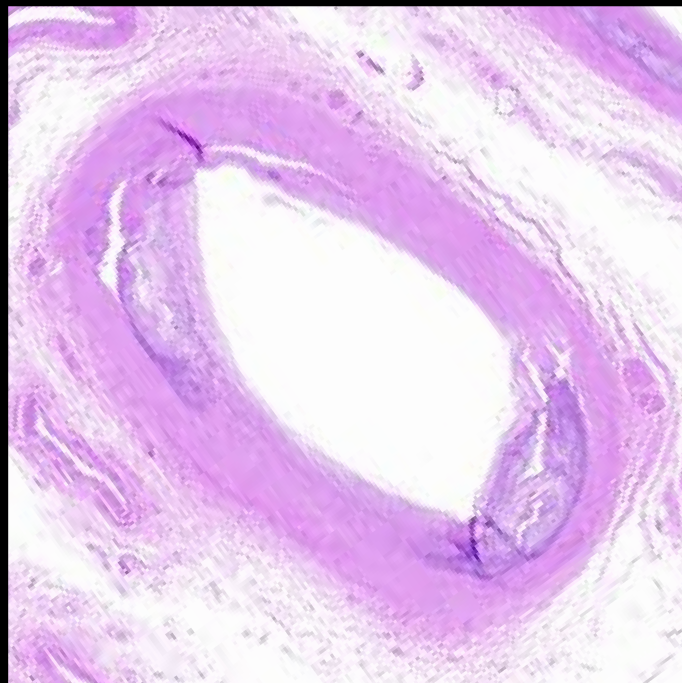
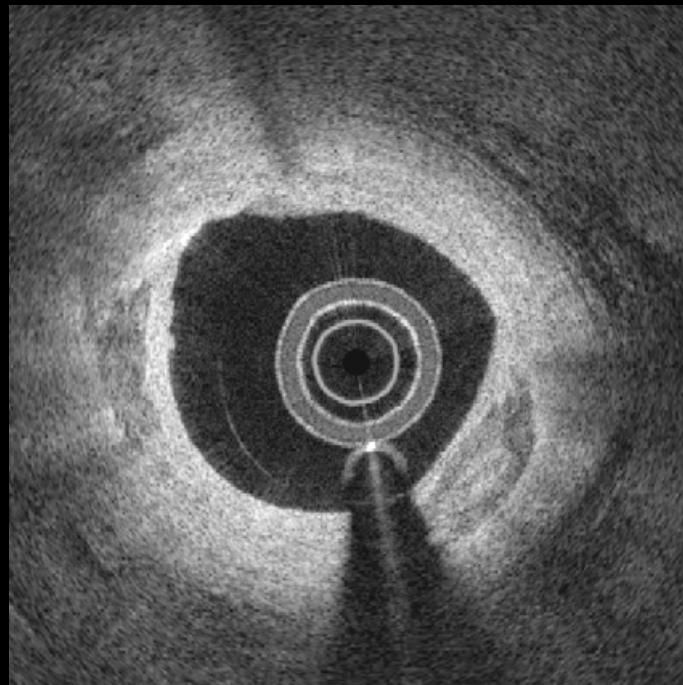
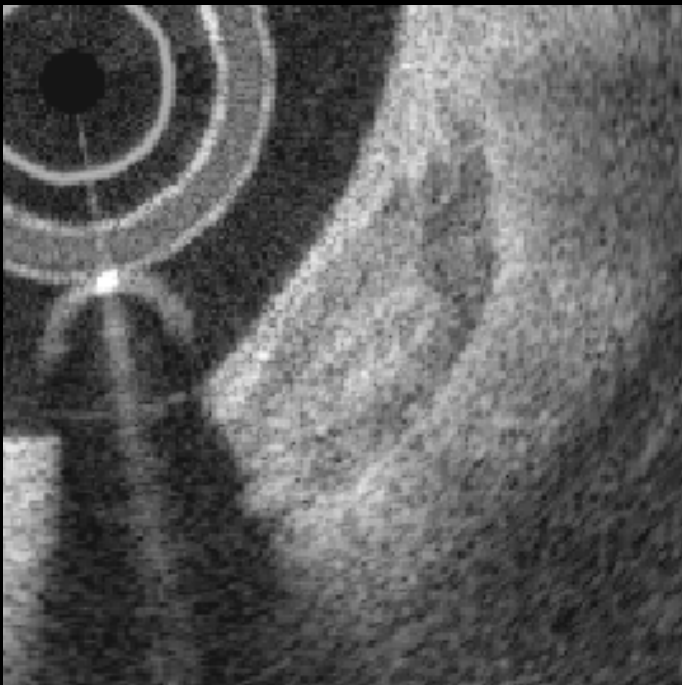
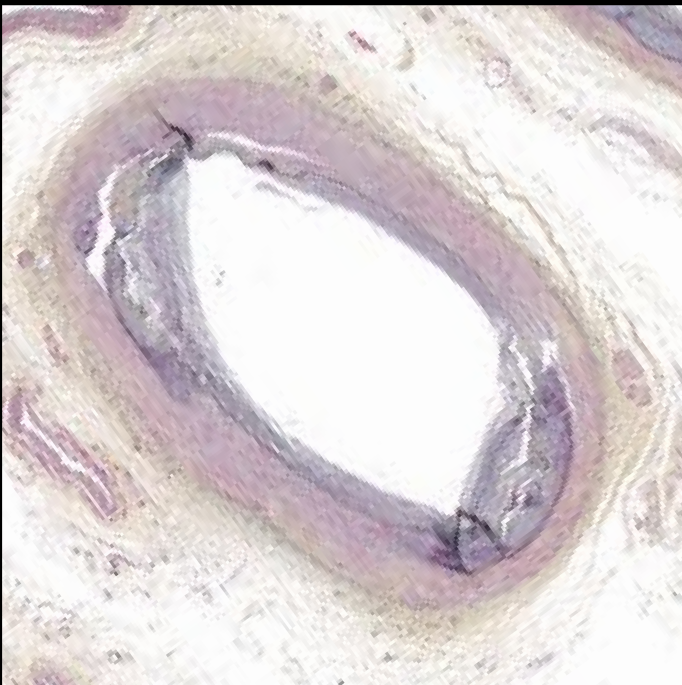
22



#23

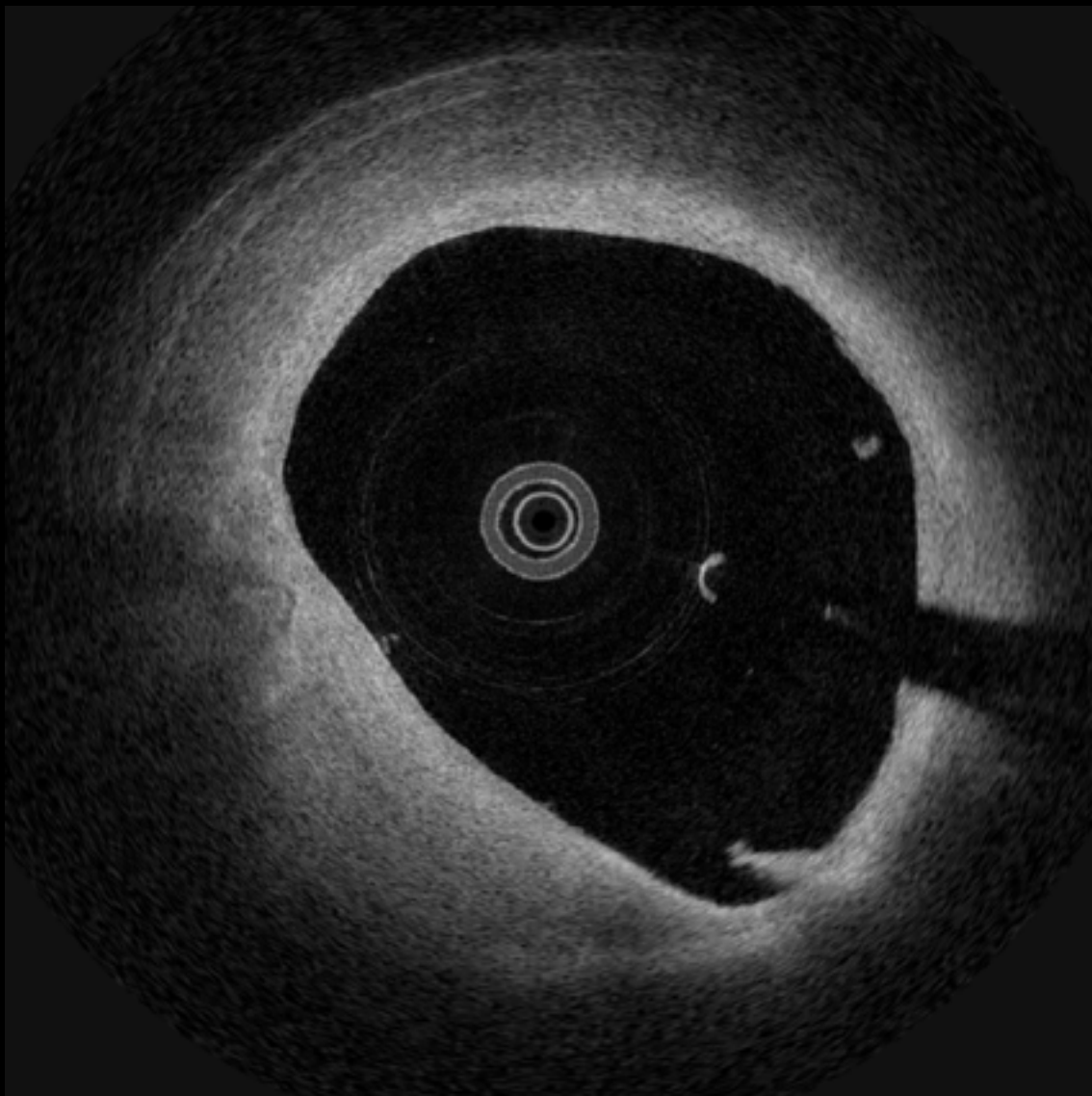


#23

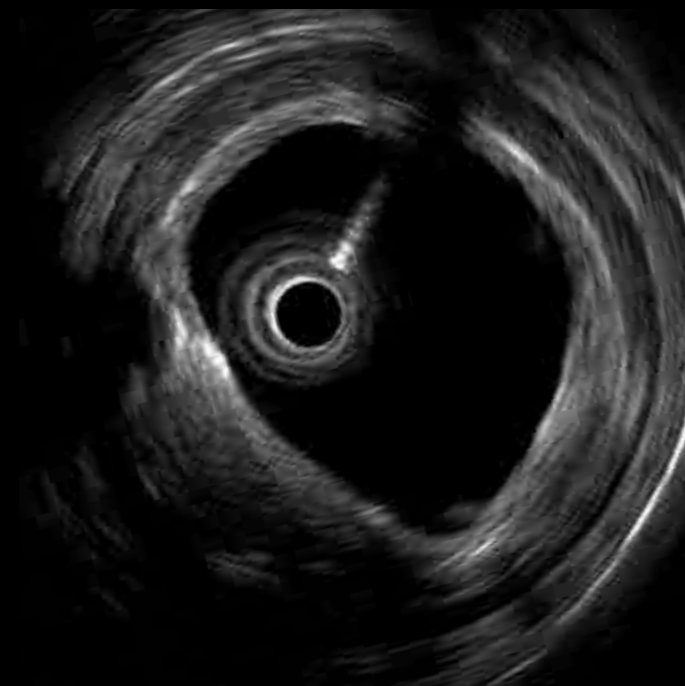
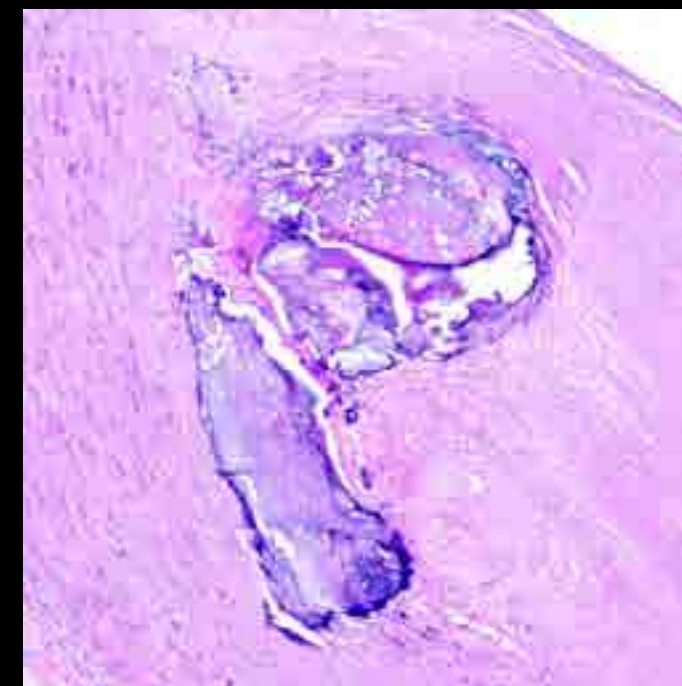
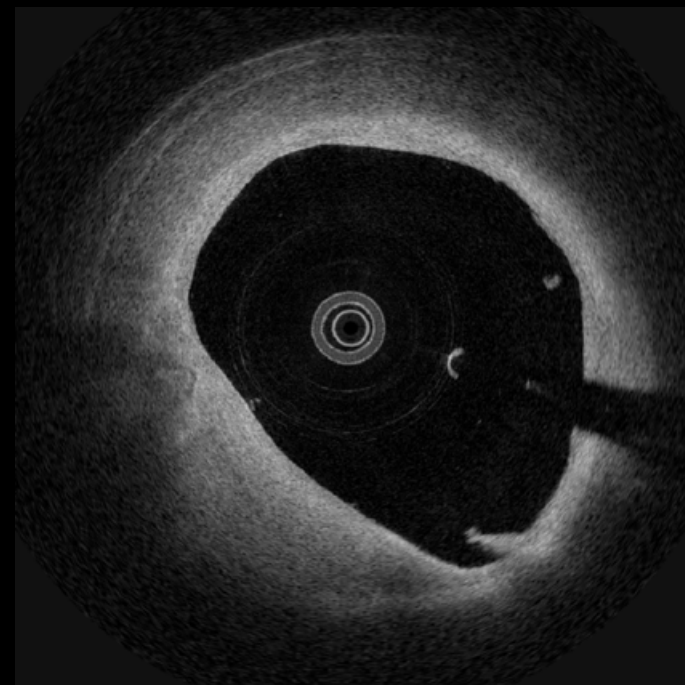

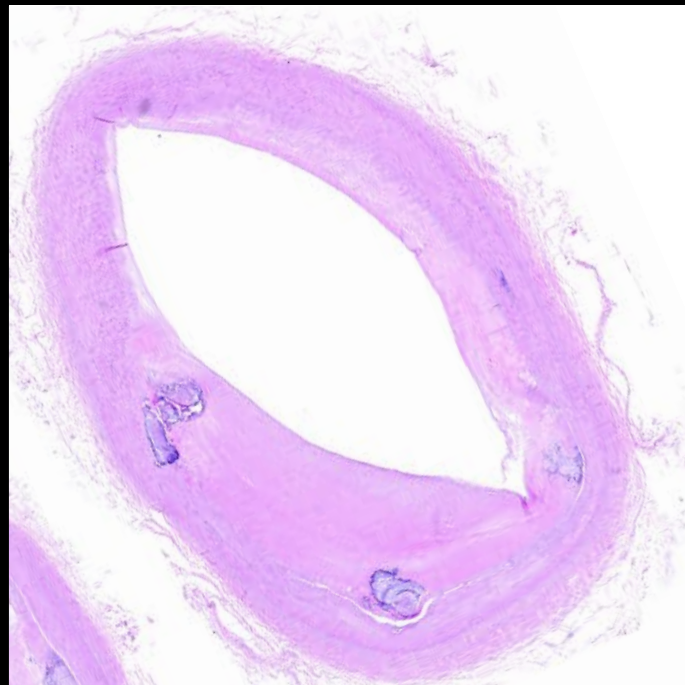


Nodular
calcification

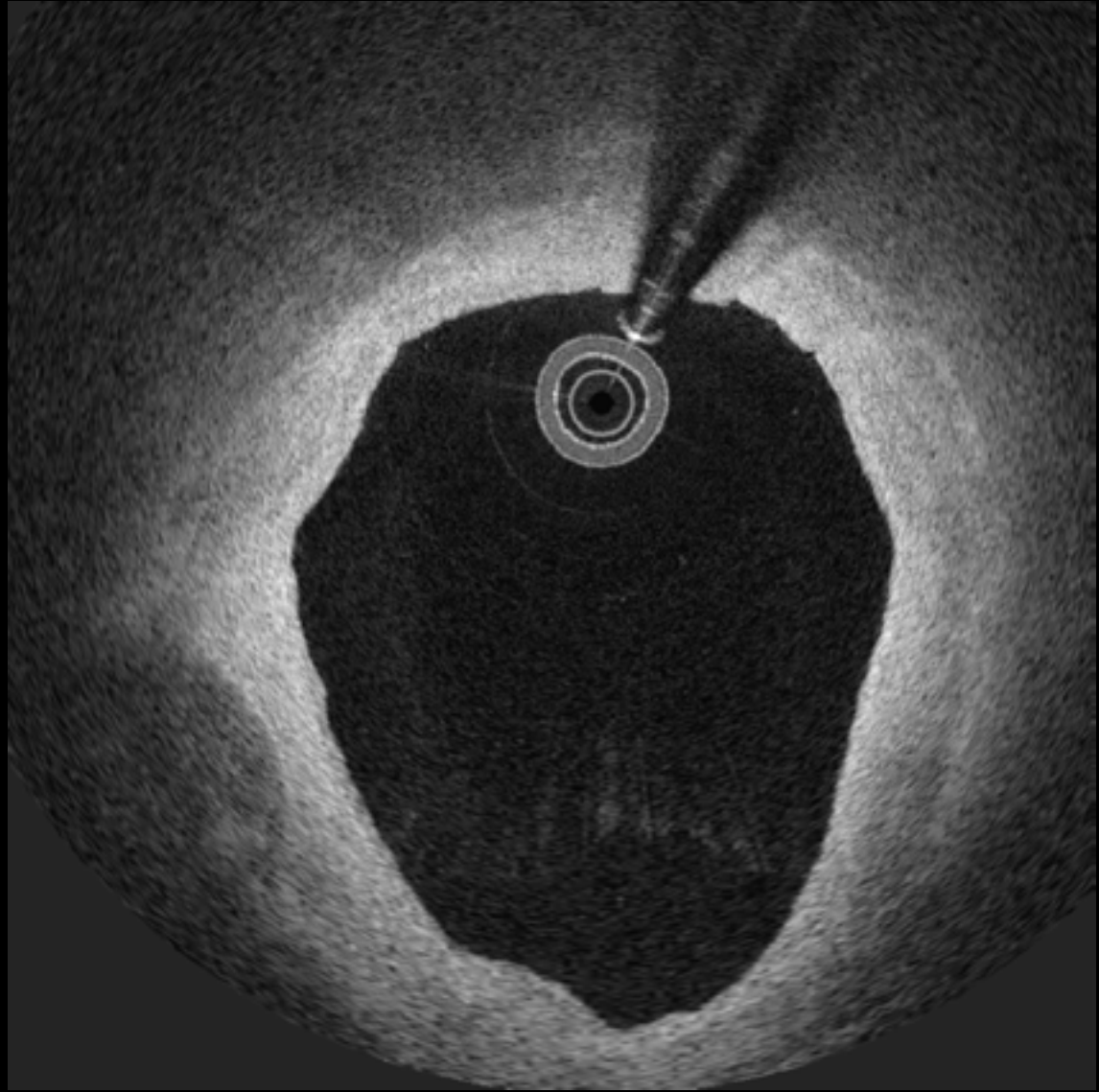
24



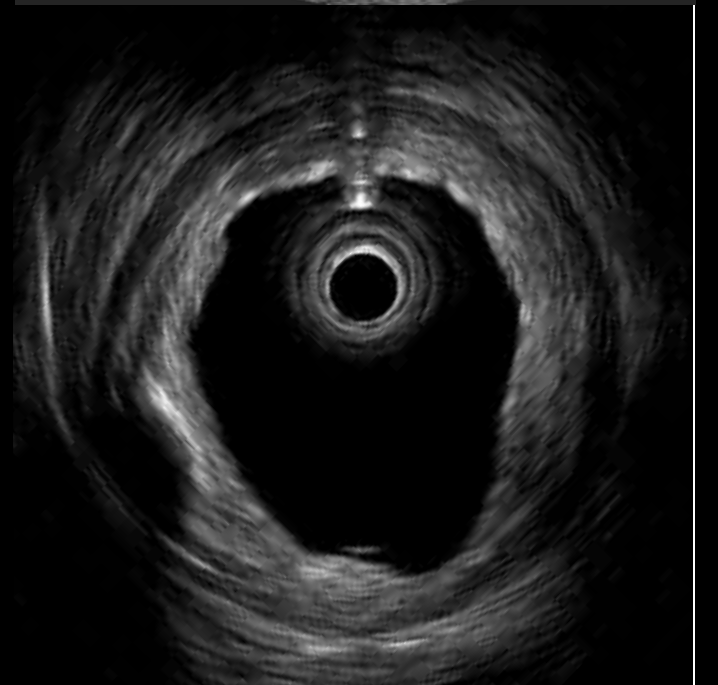
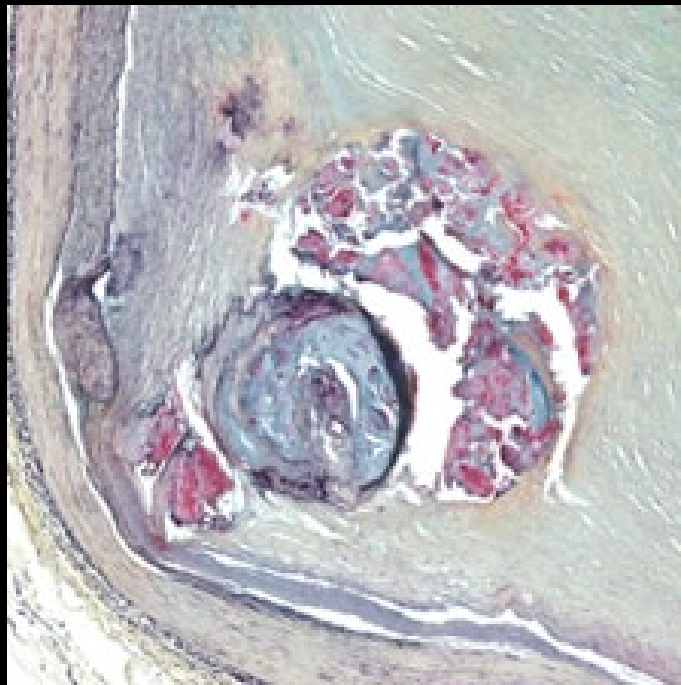
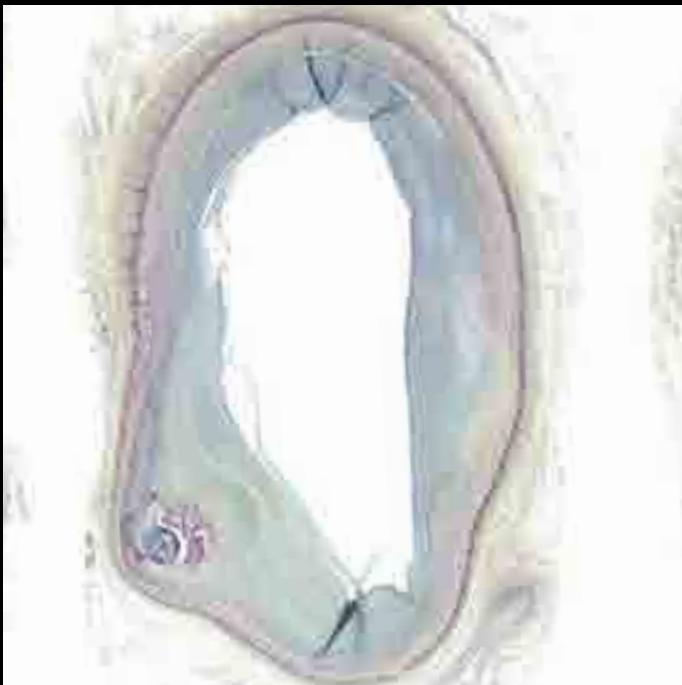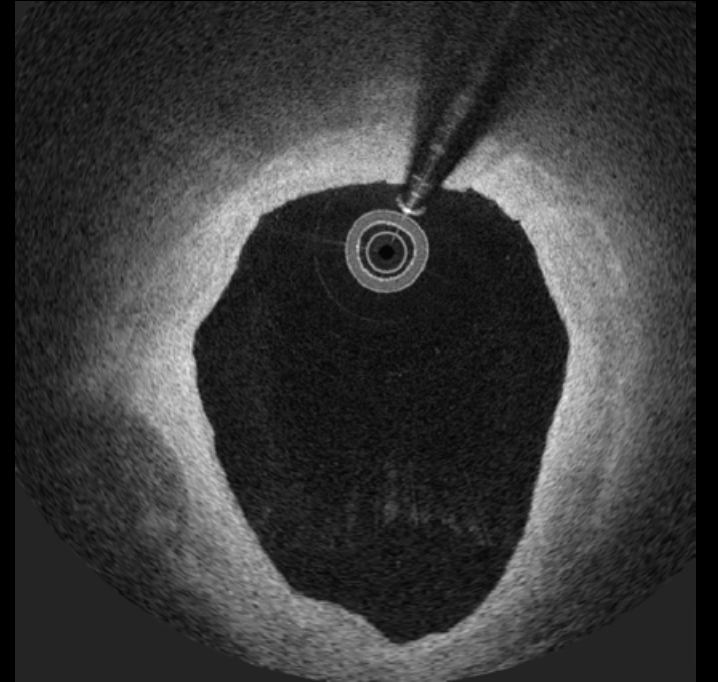
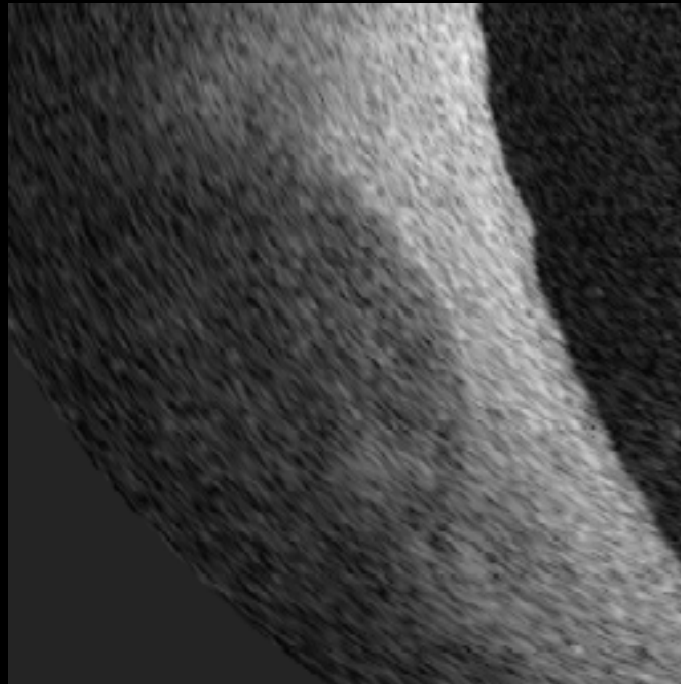
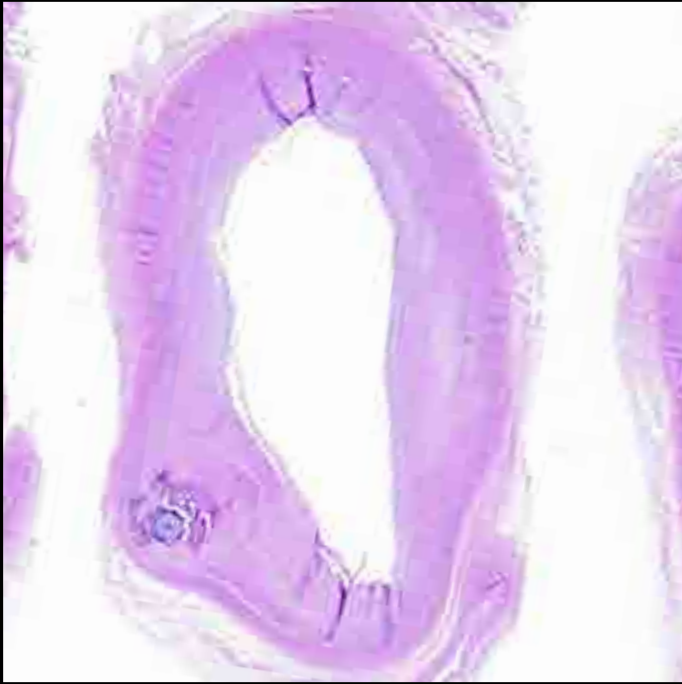24



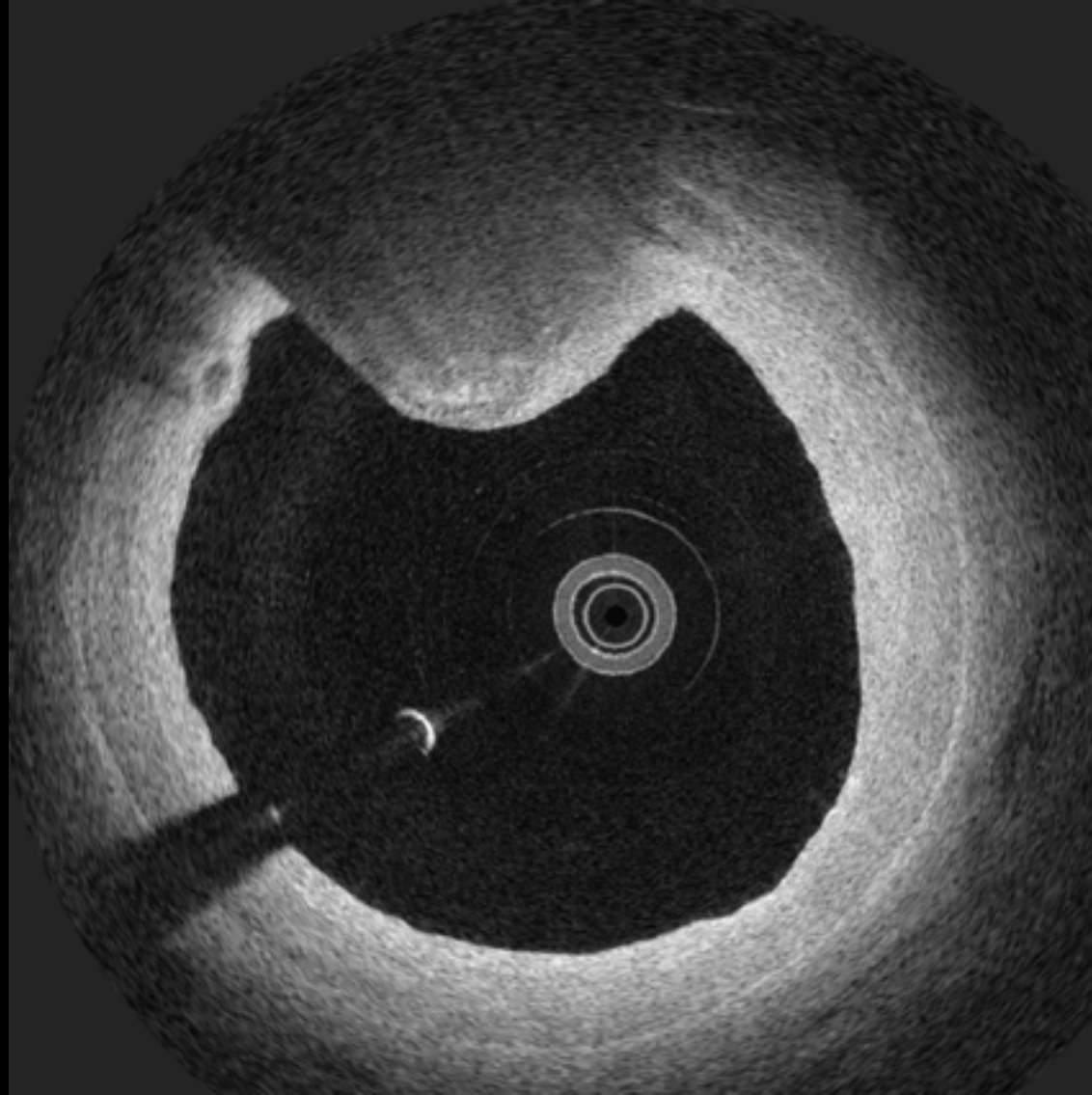
25



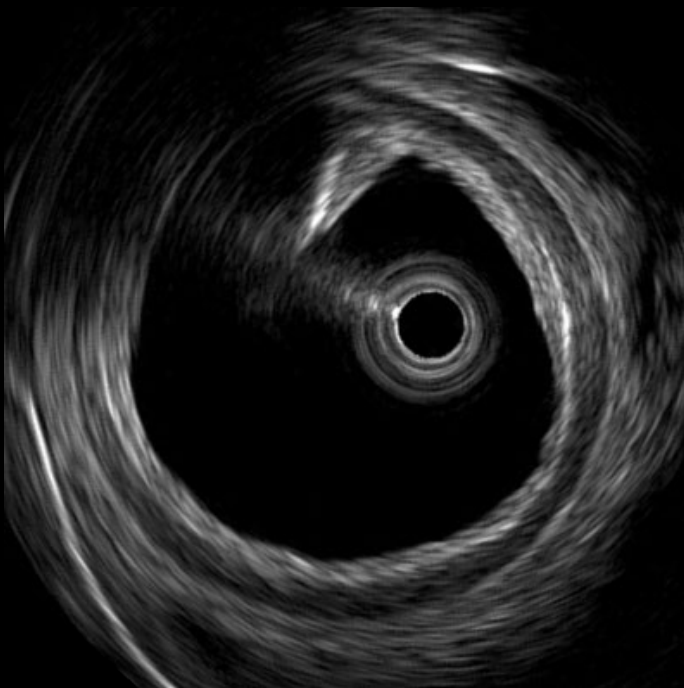
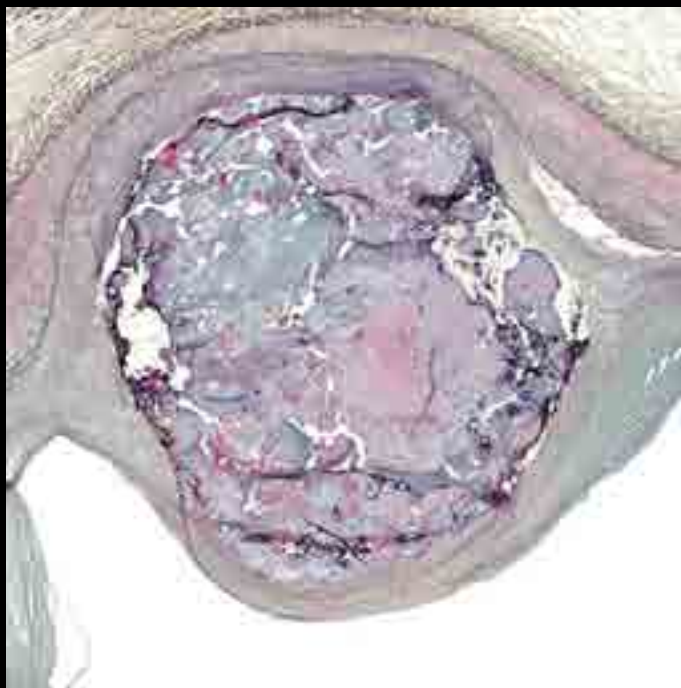
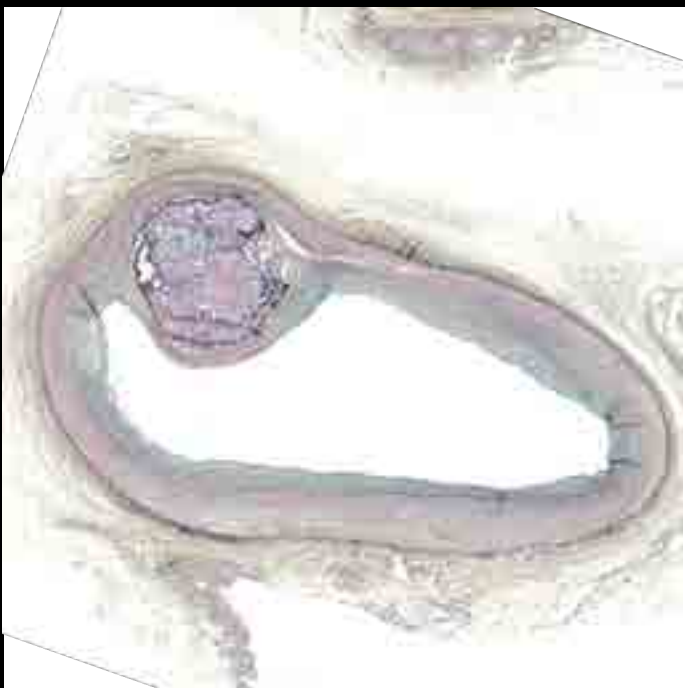
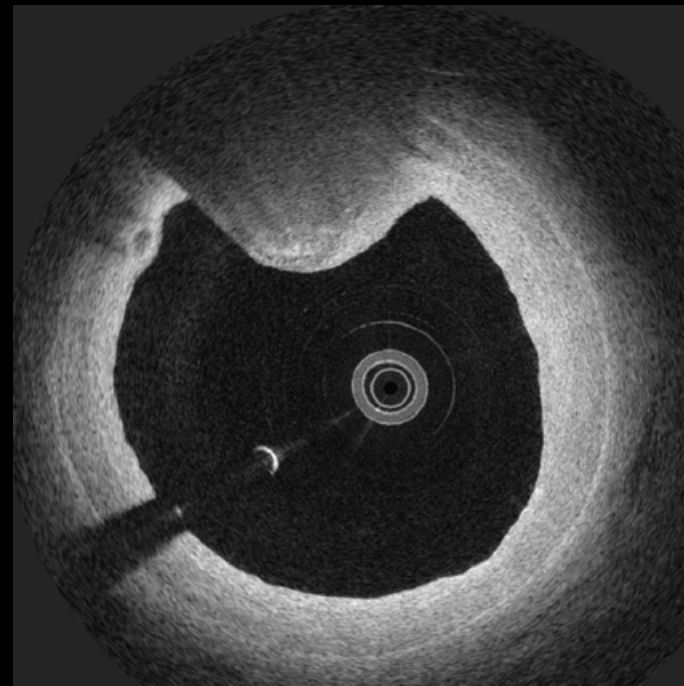
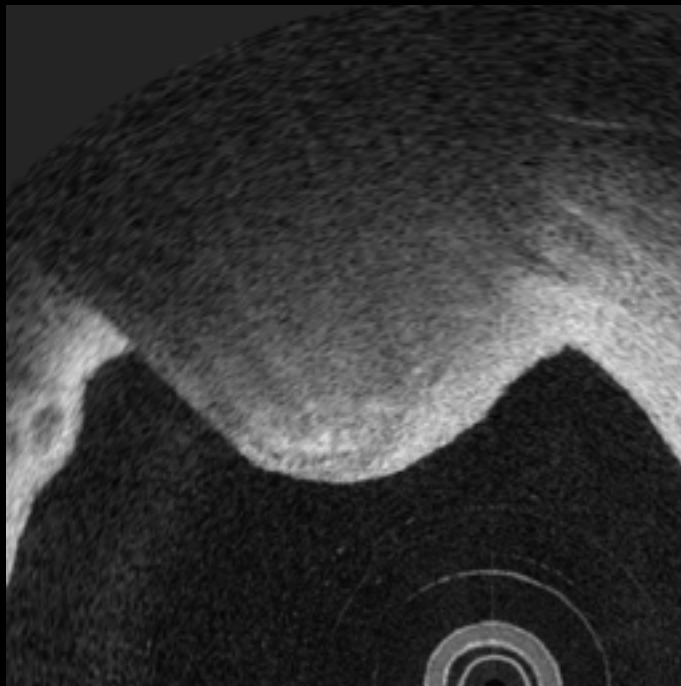
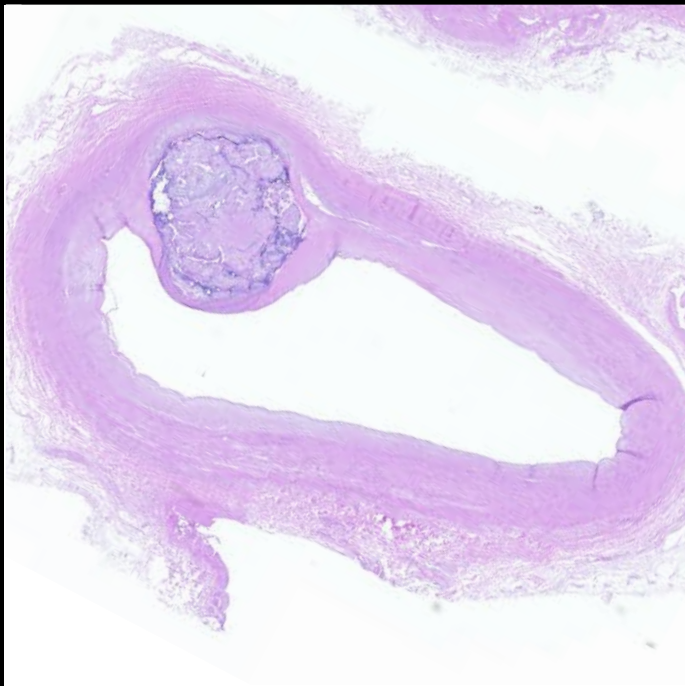
25



26

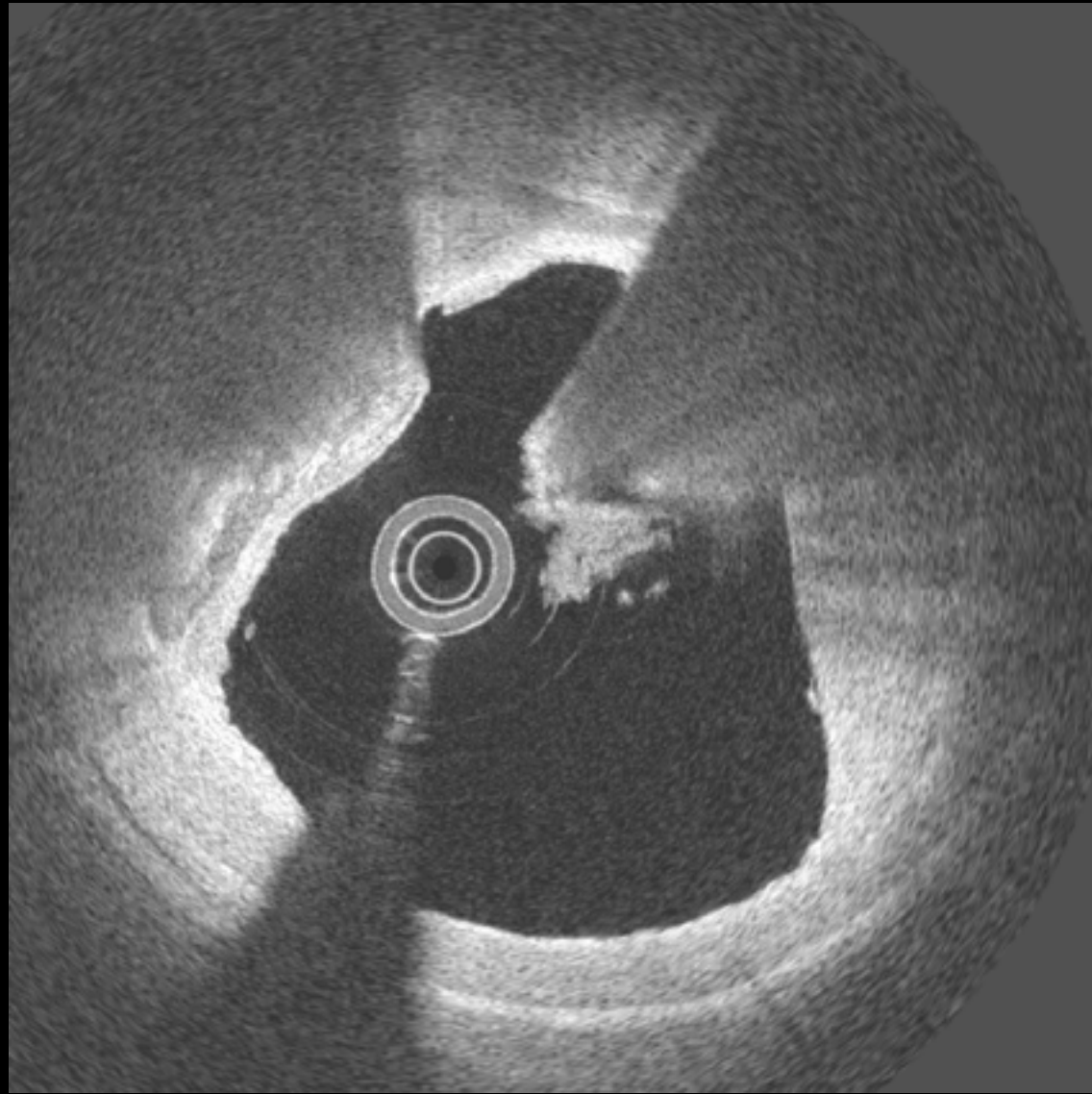


26

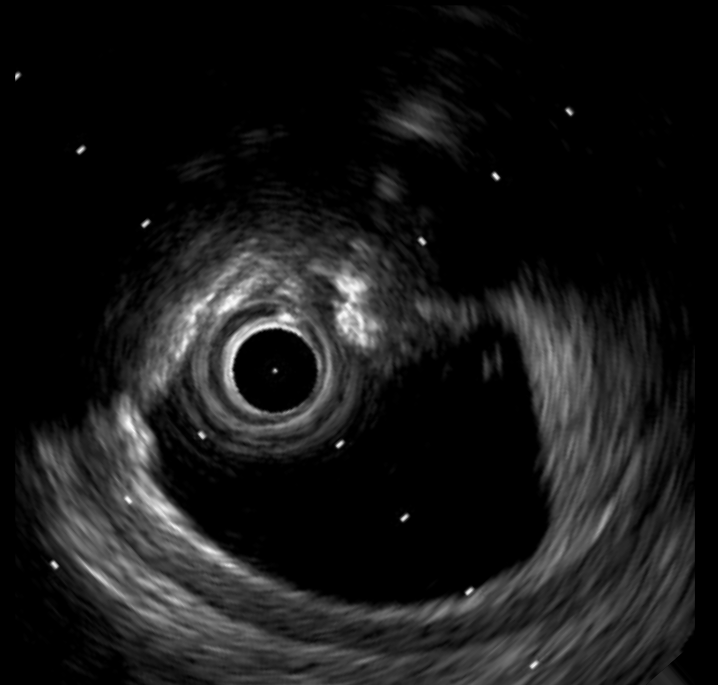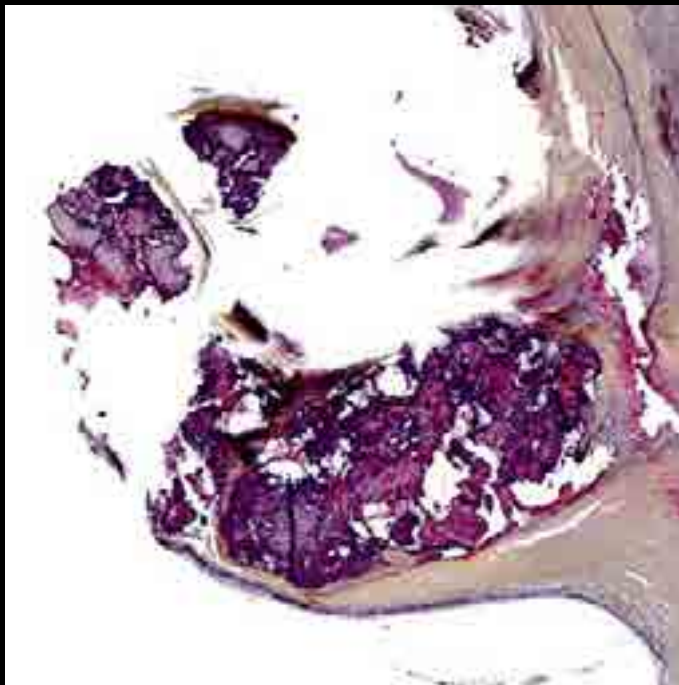
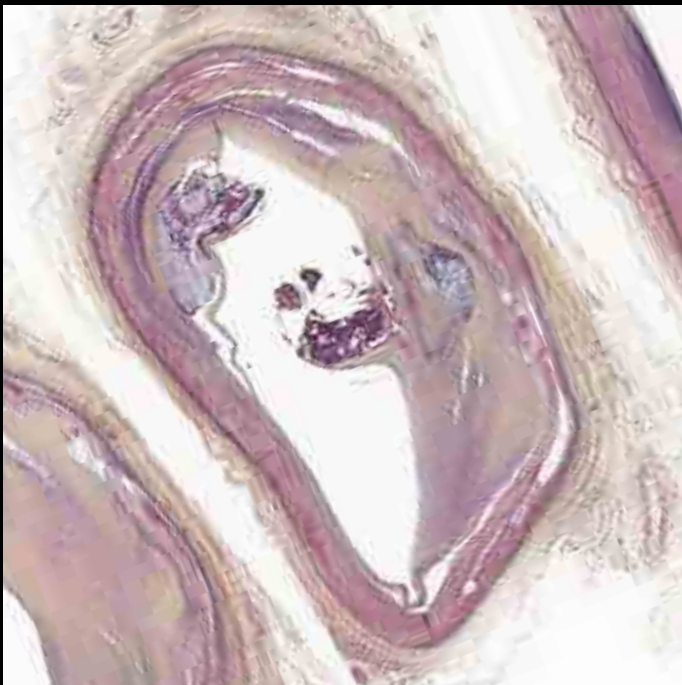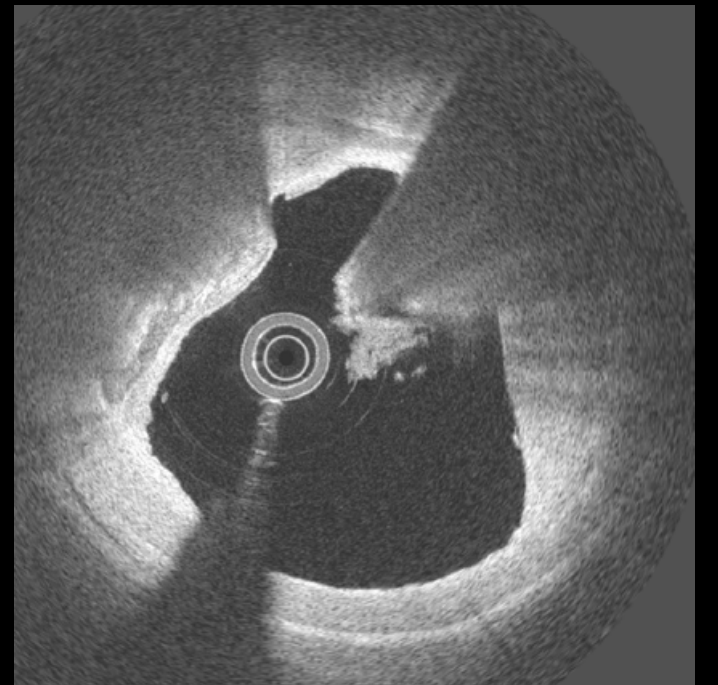
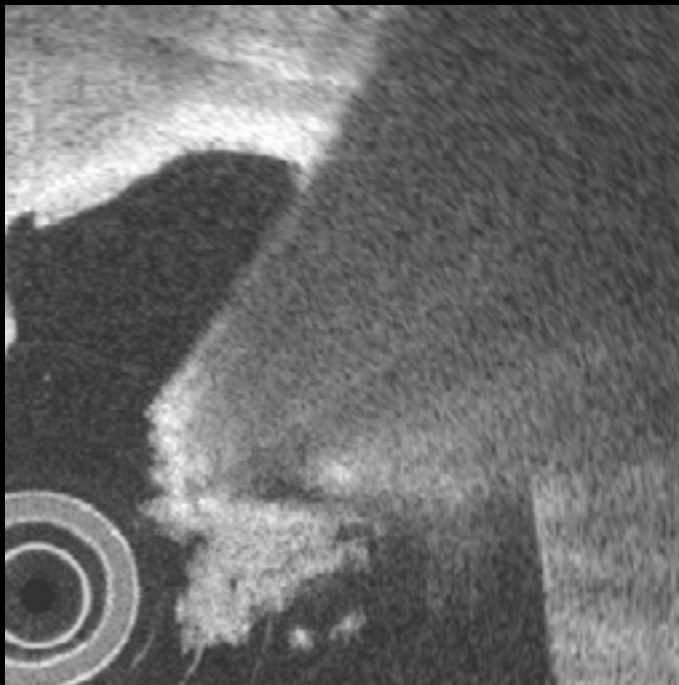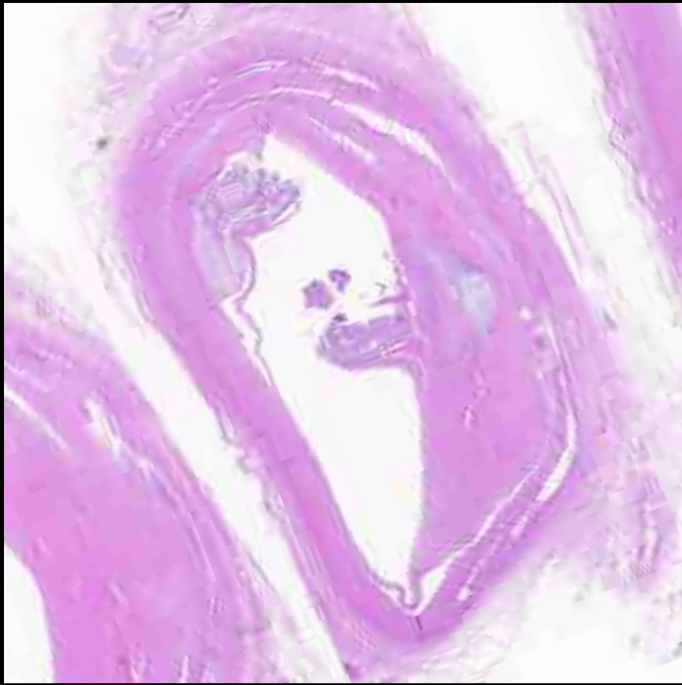


Calcified Nodule

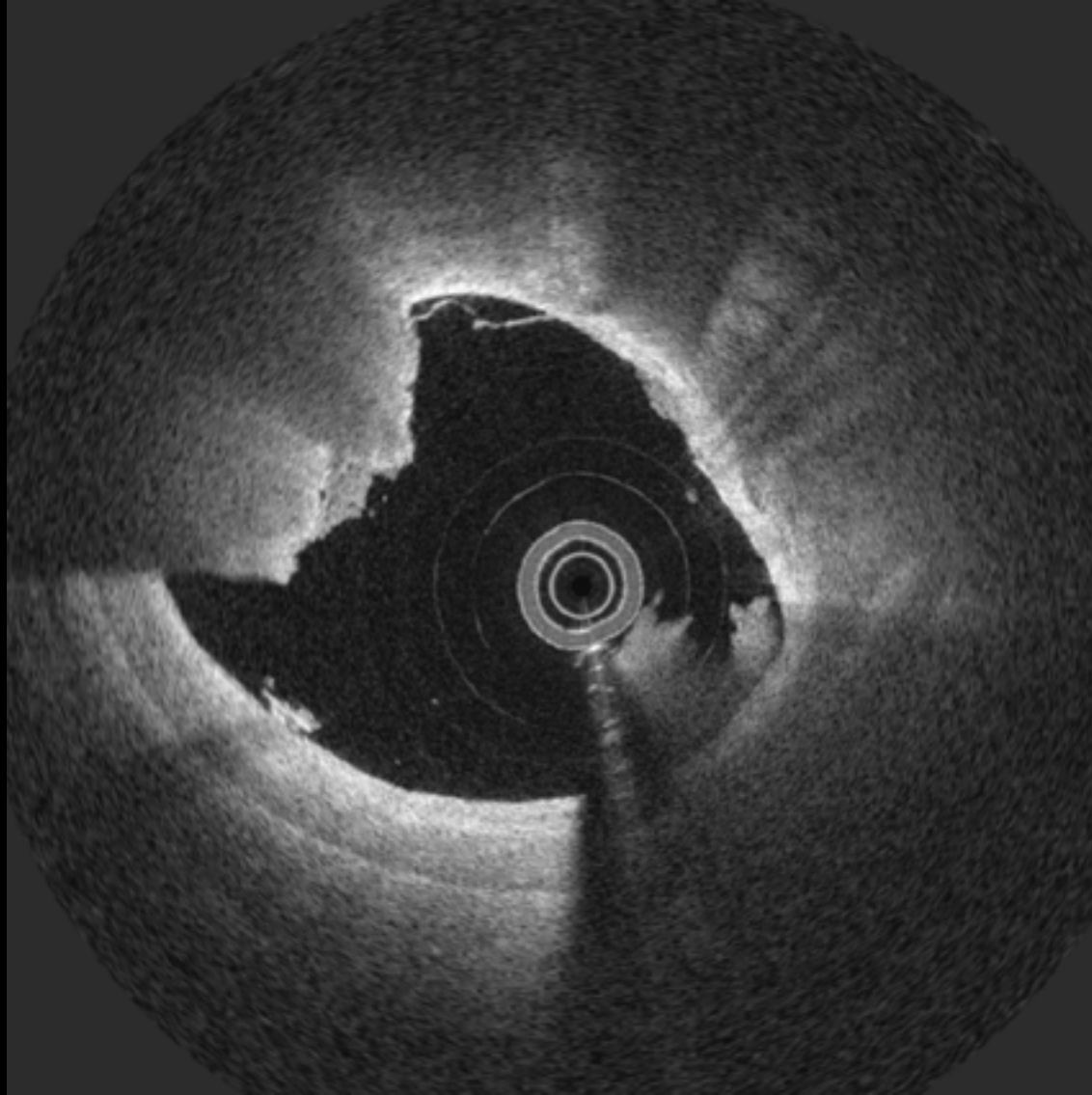
27



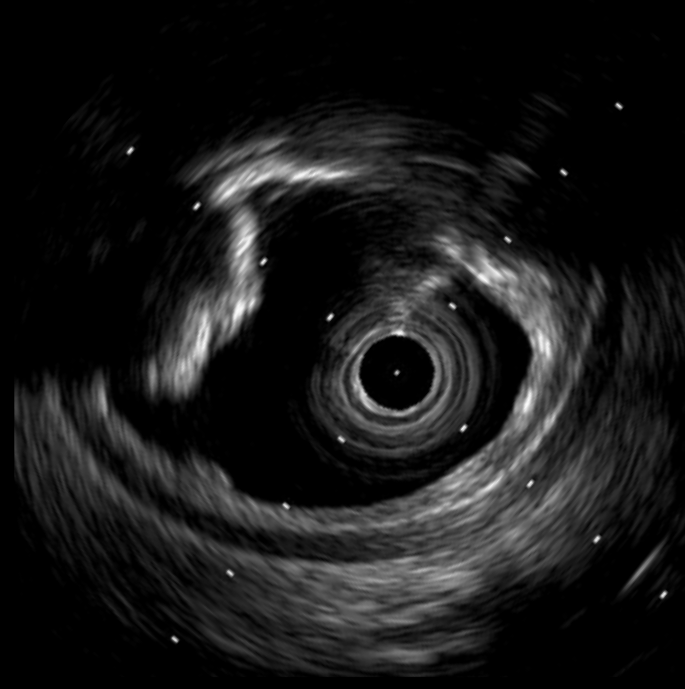
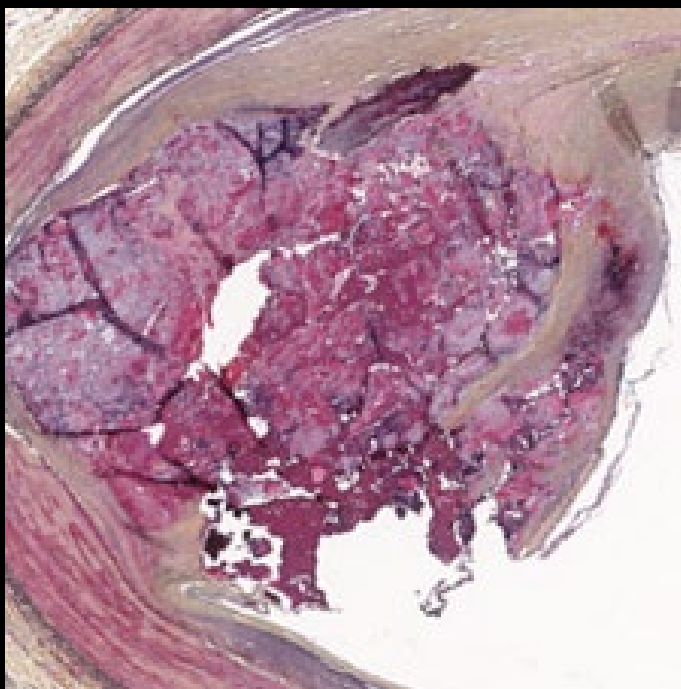
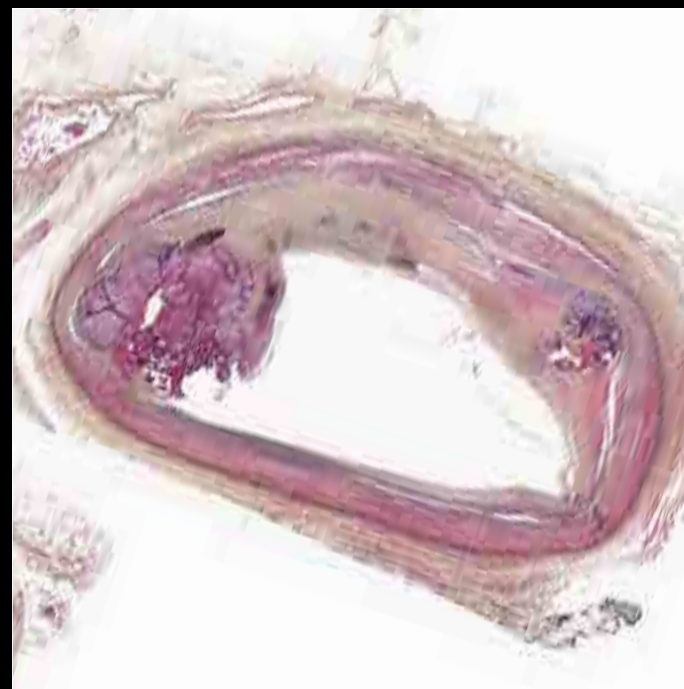
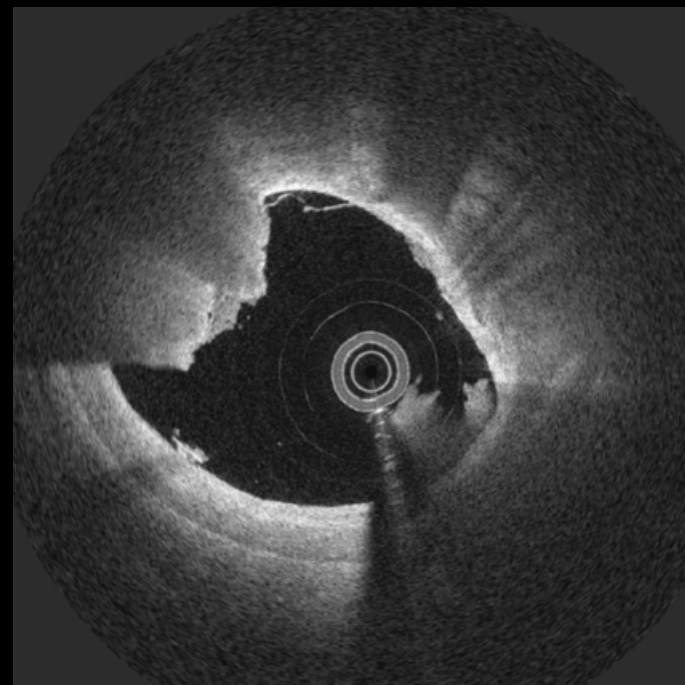
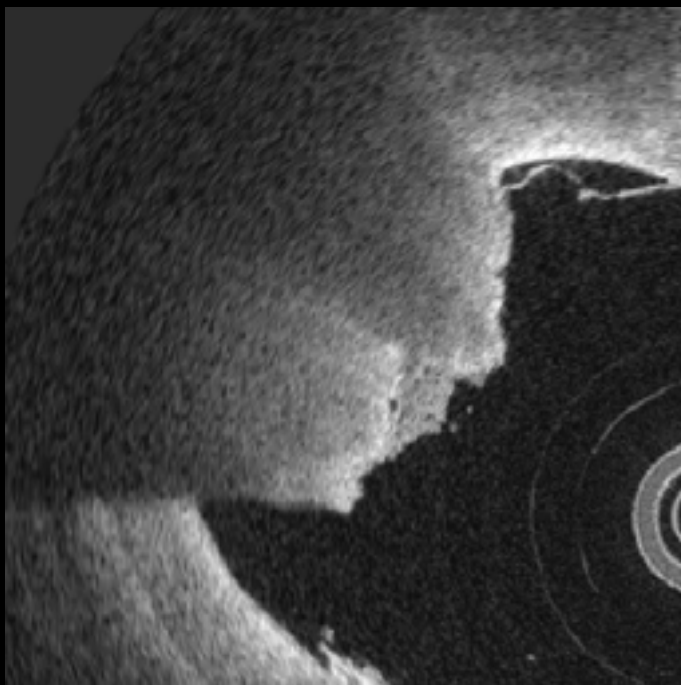
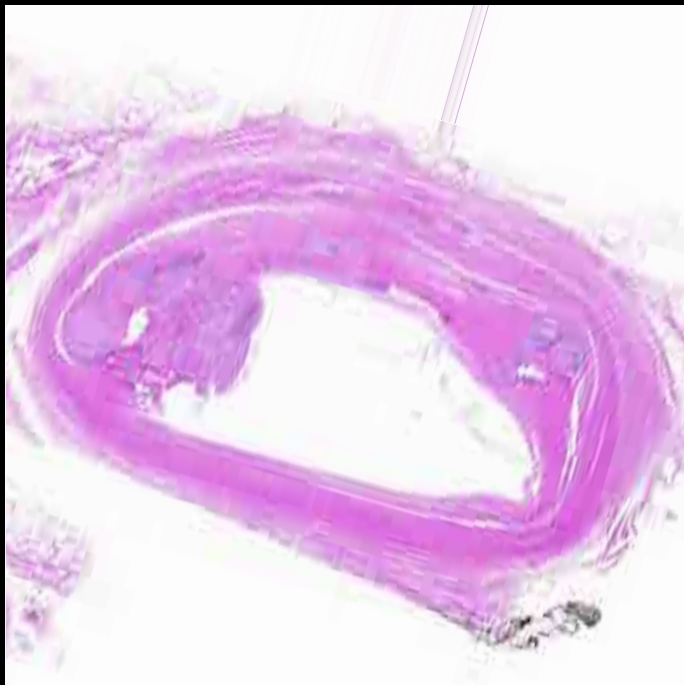27



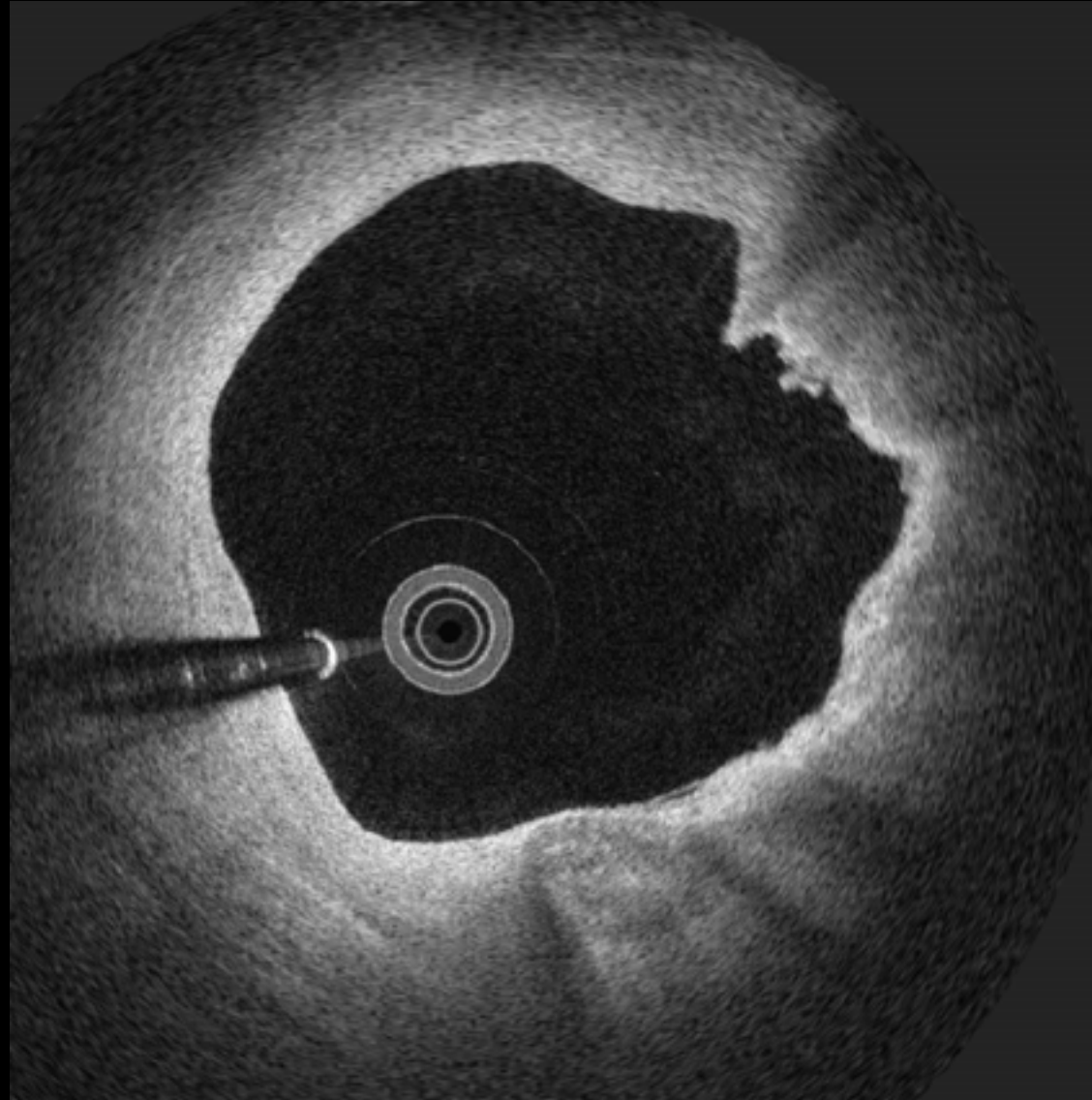
28



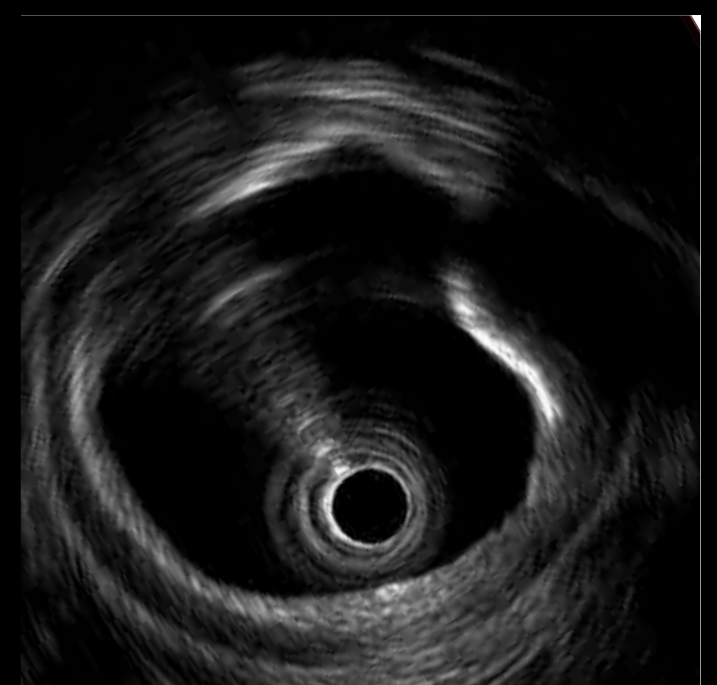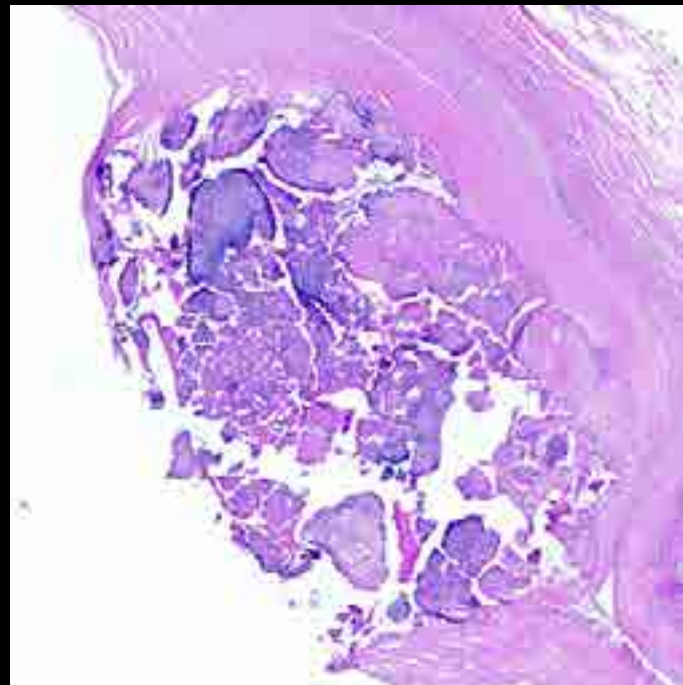
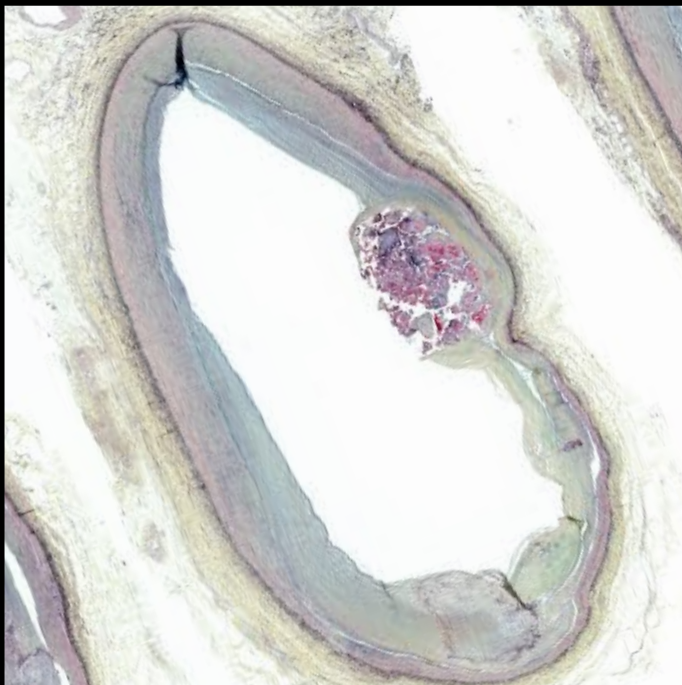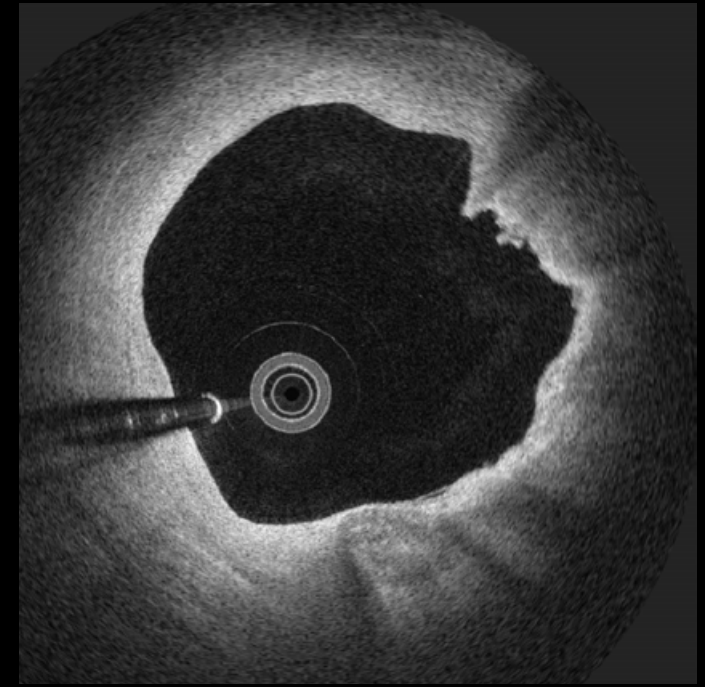
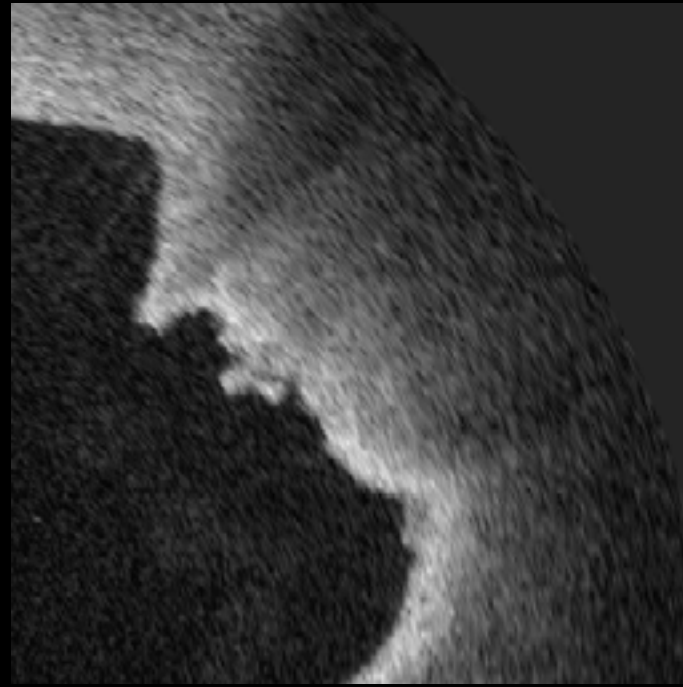
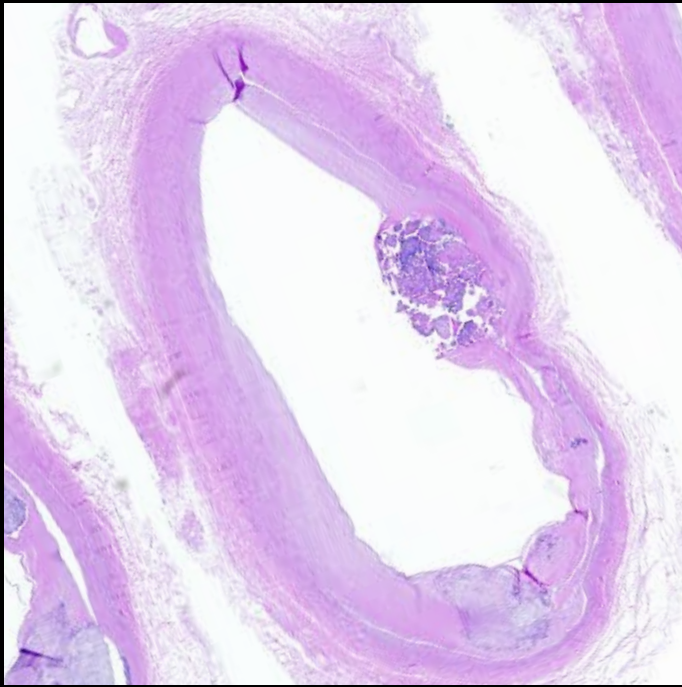
28



29

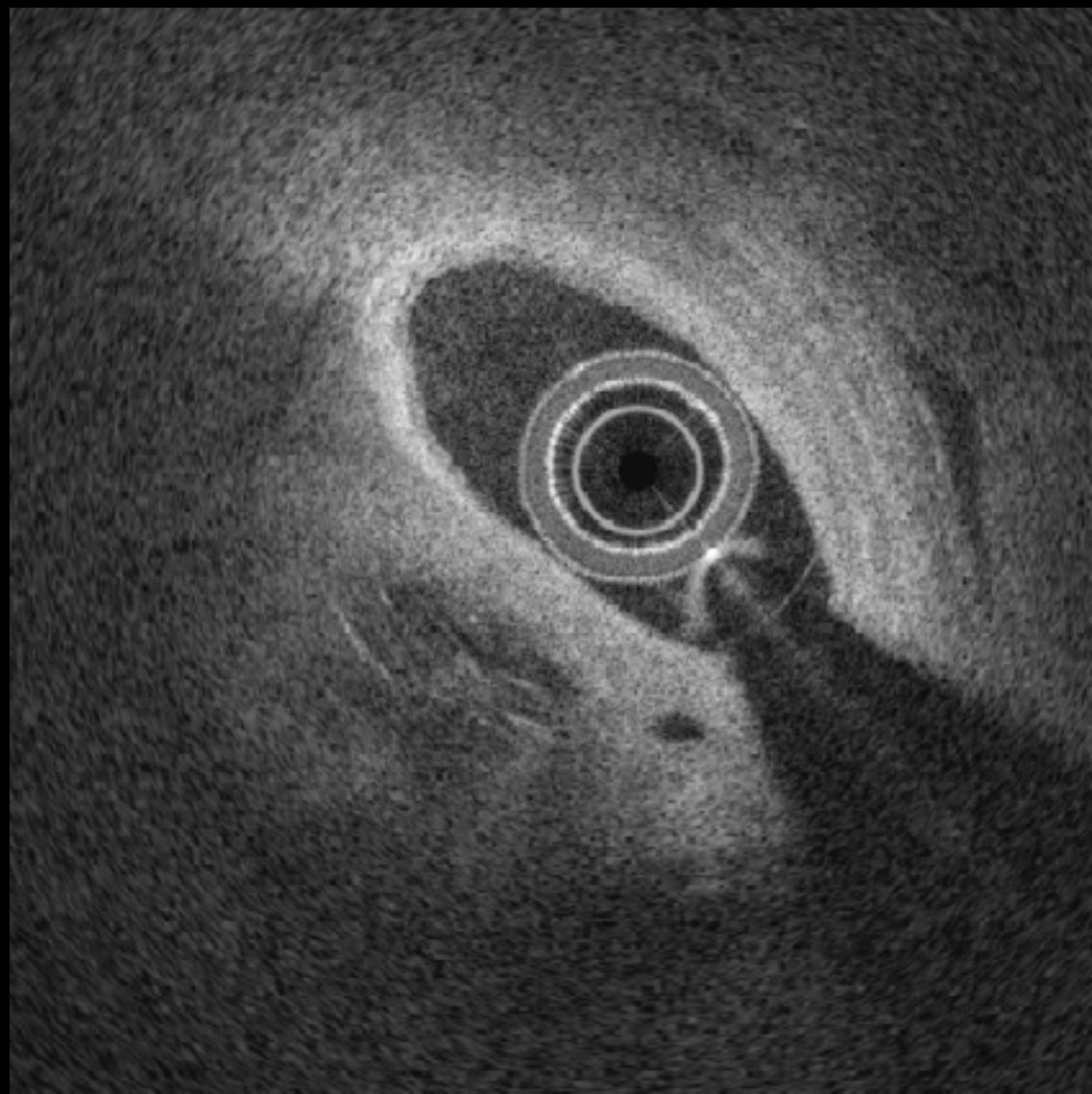


29

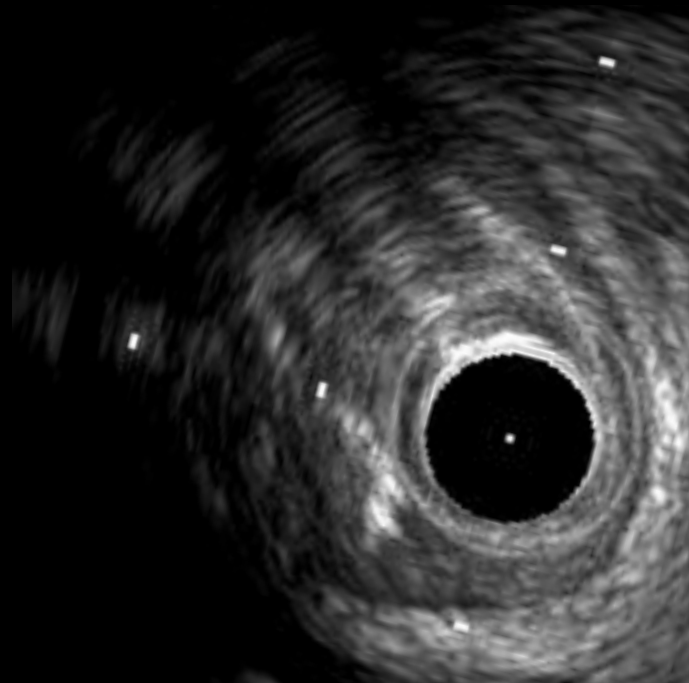
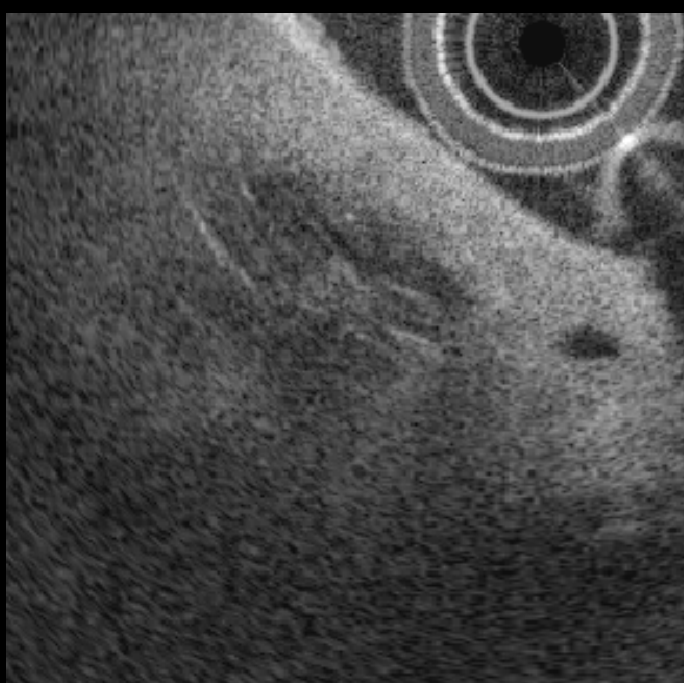
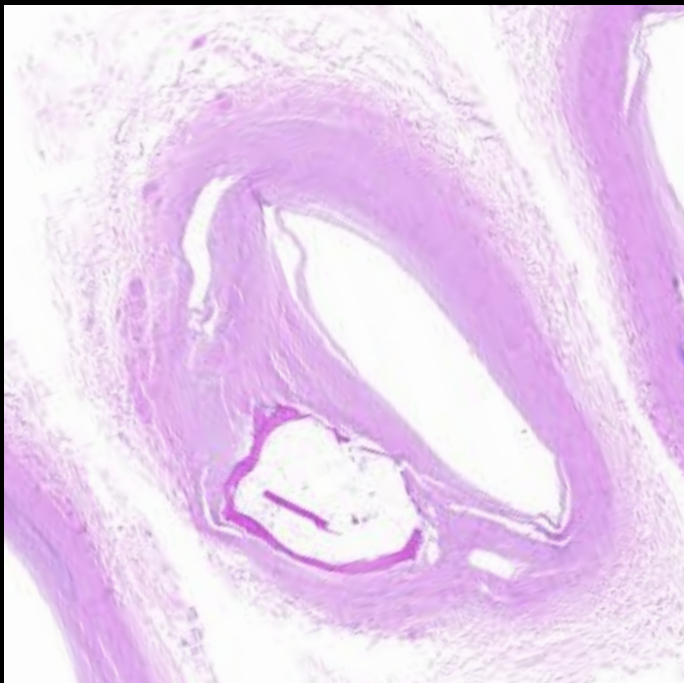
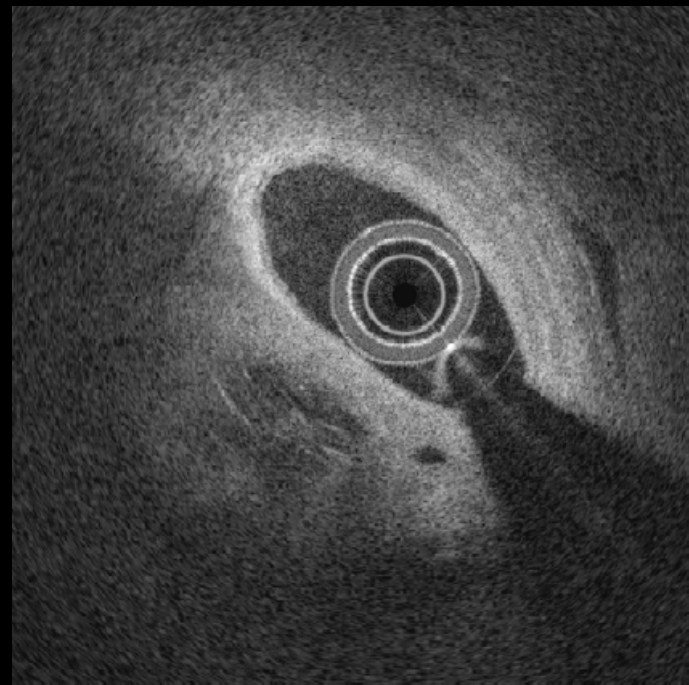
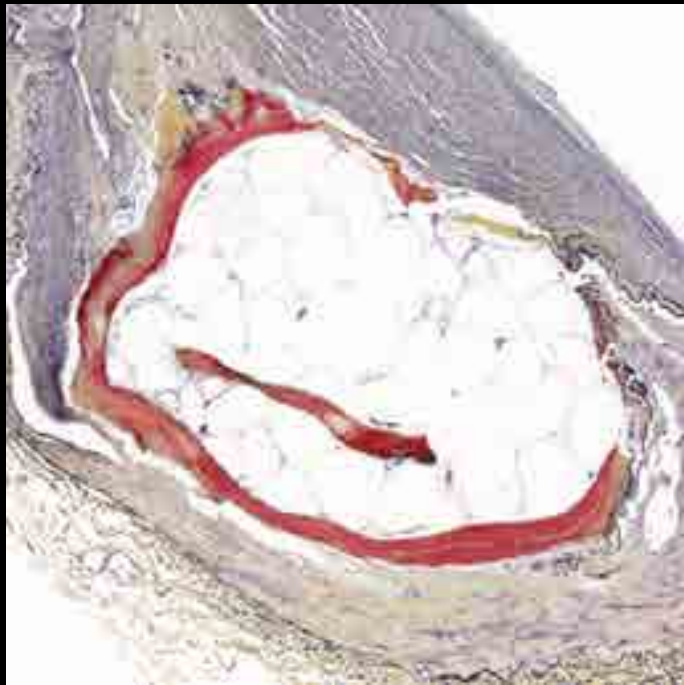
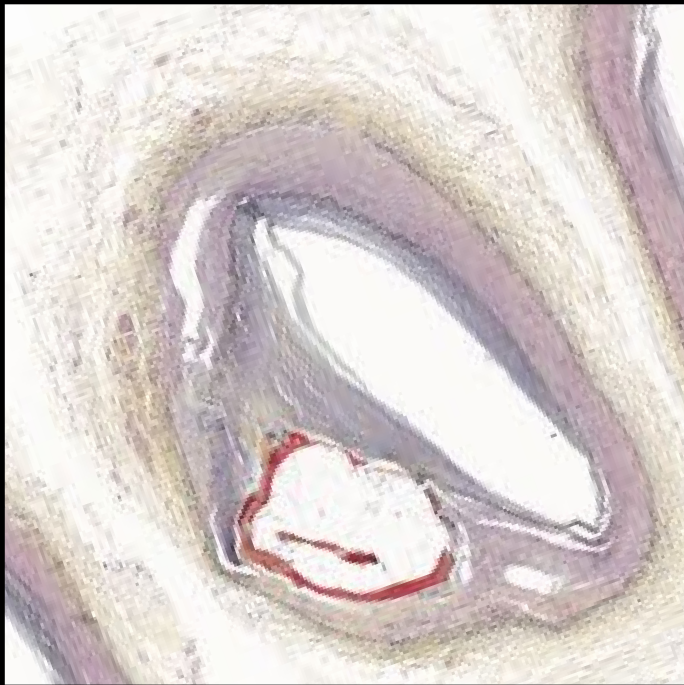


Bone formation

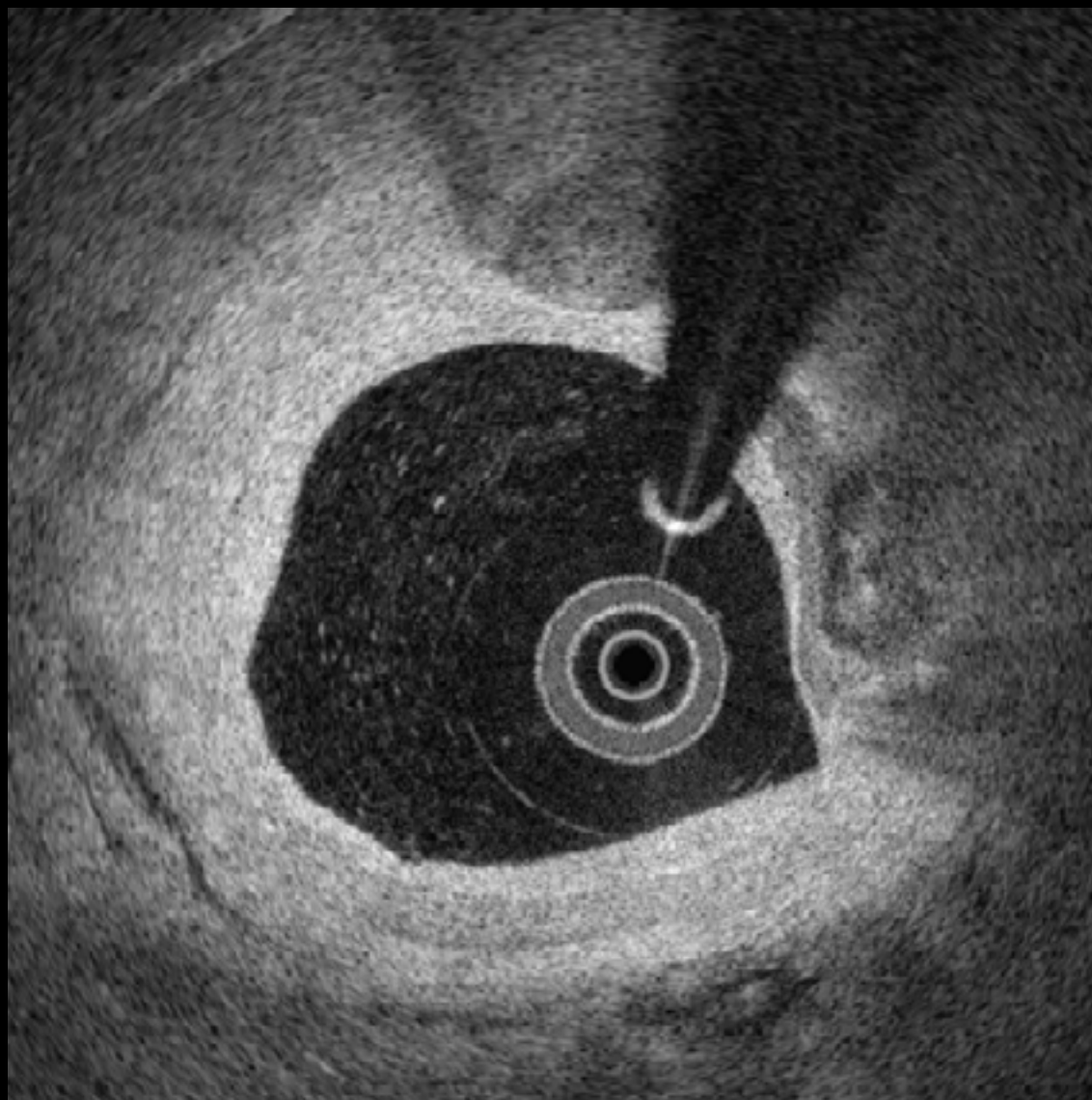
#30



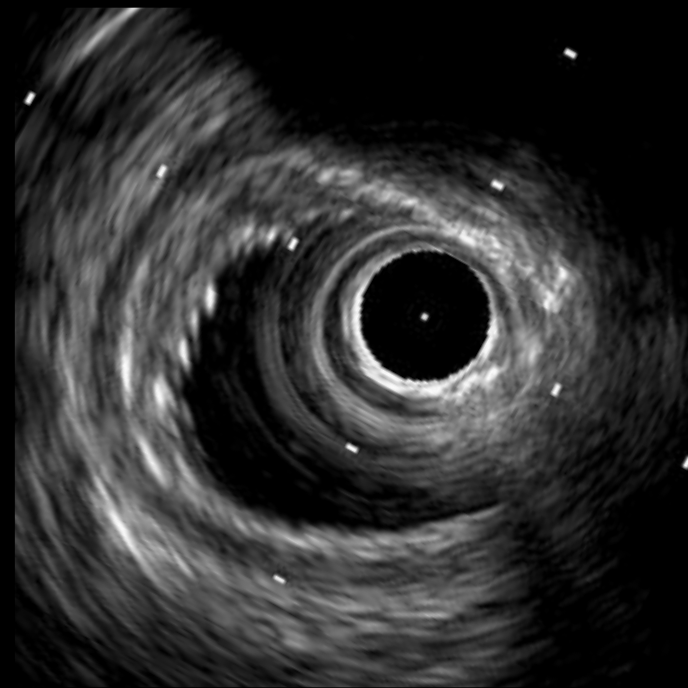
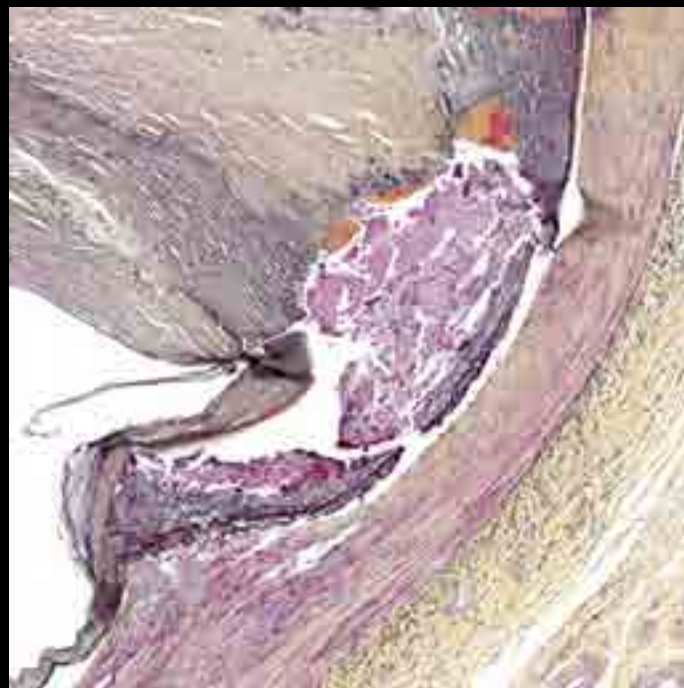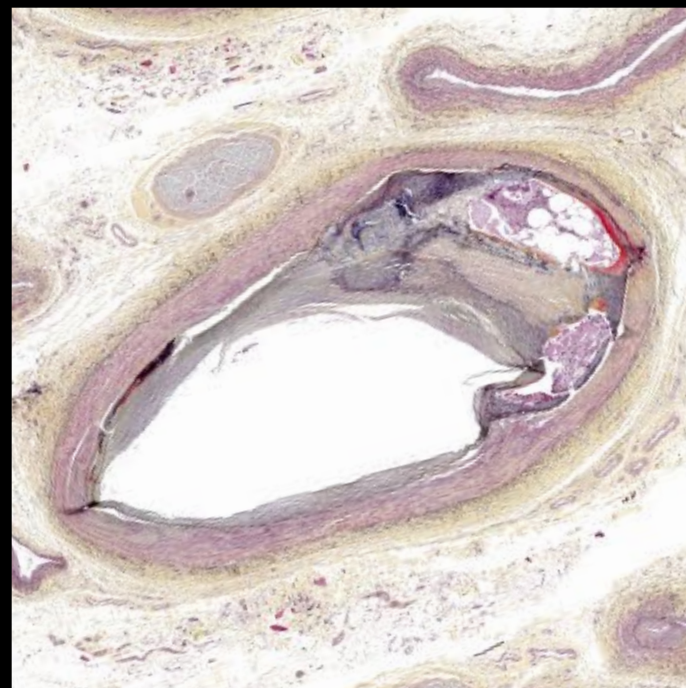
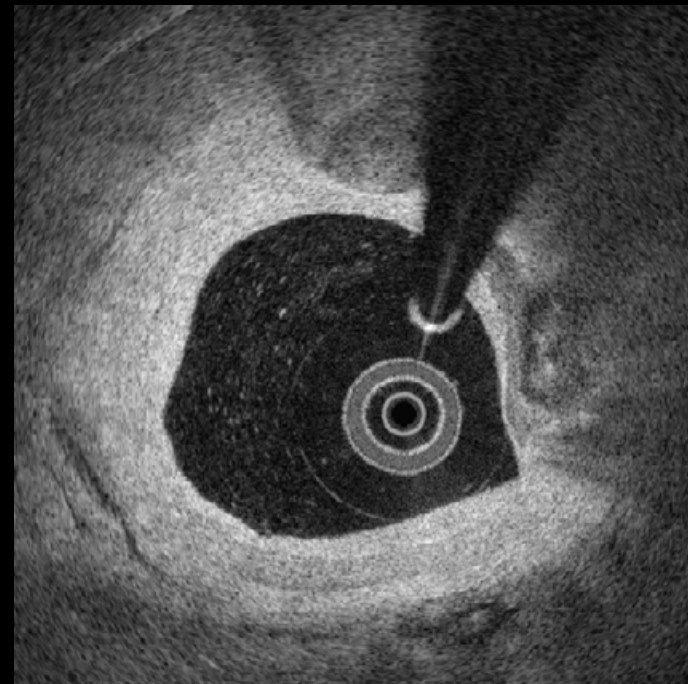
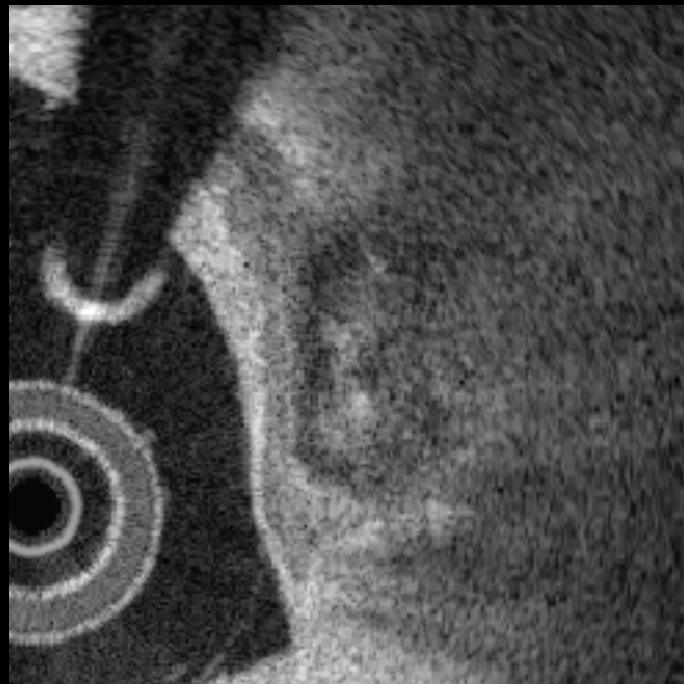
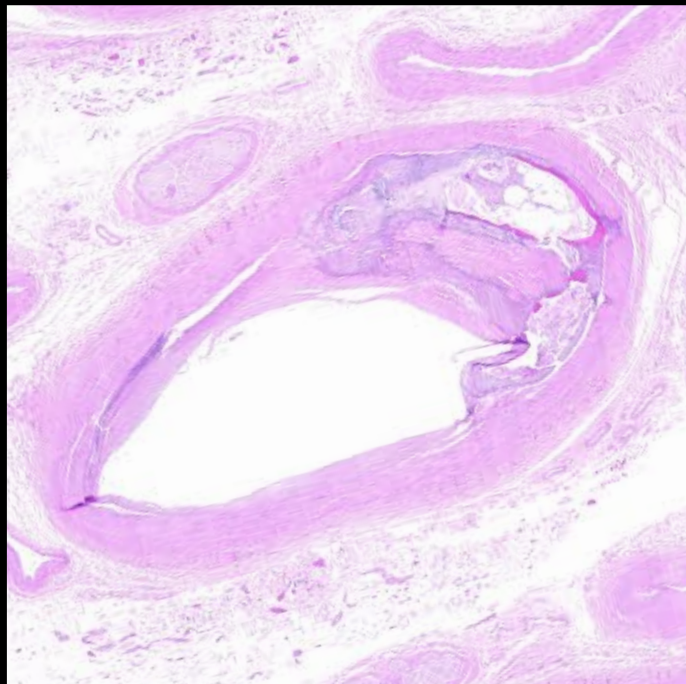
#30



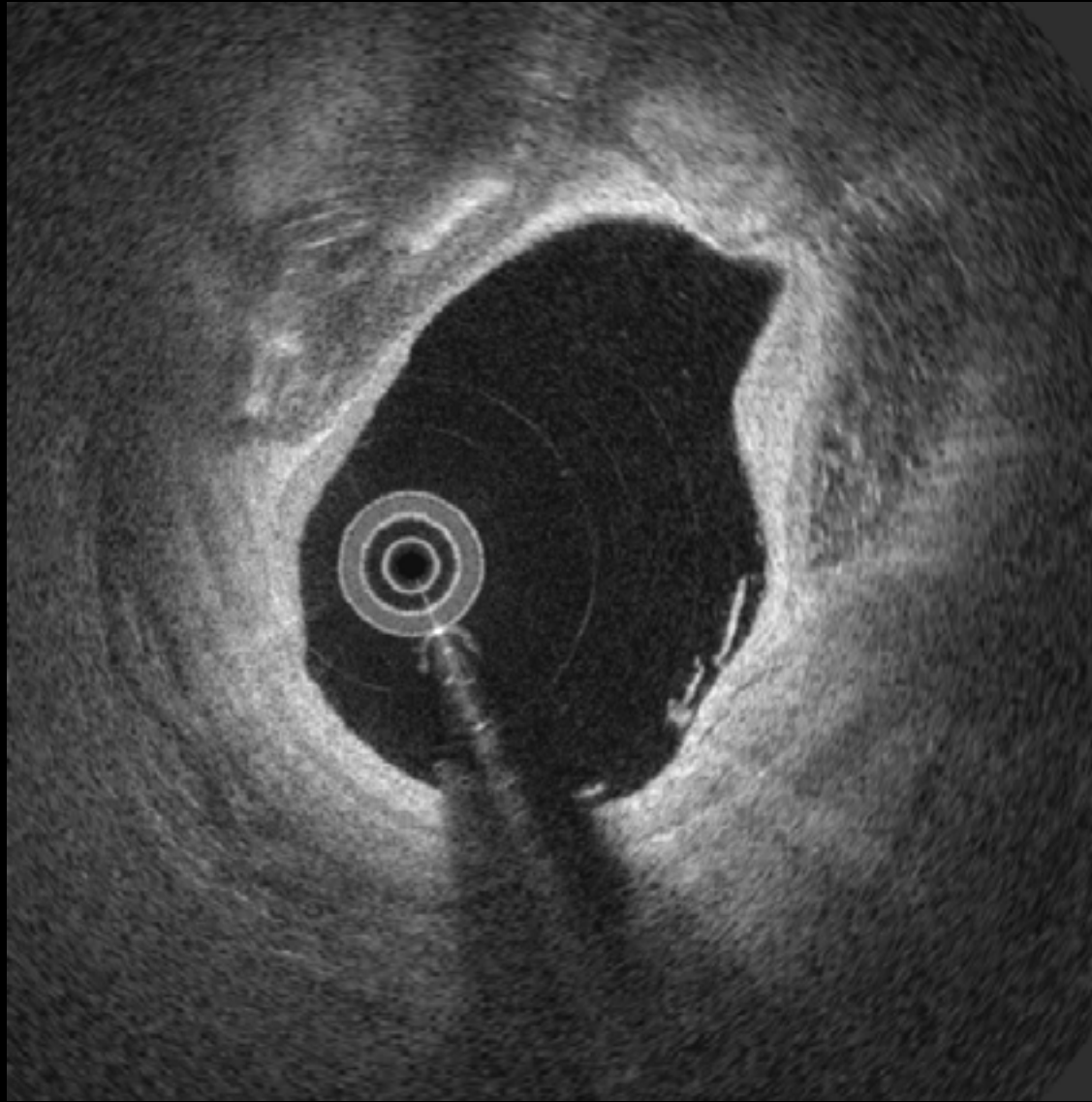
#31



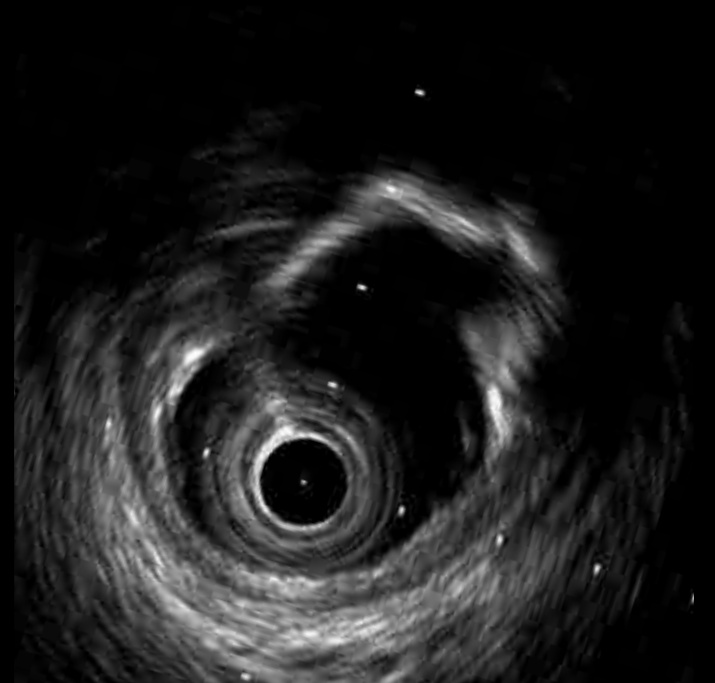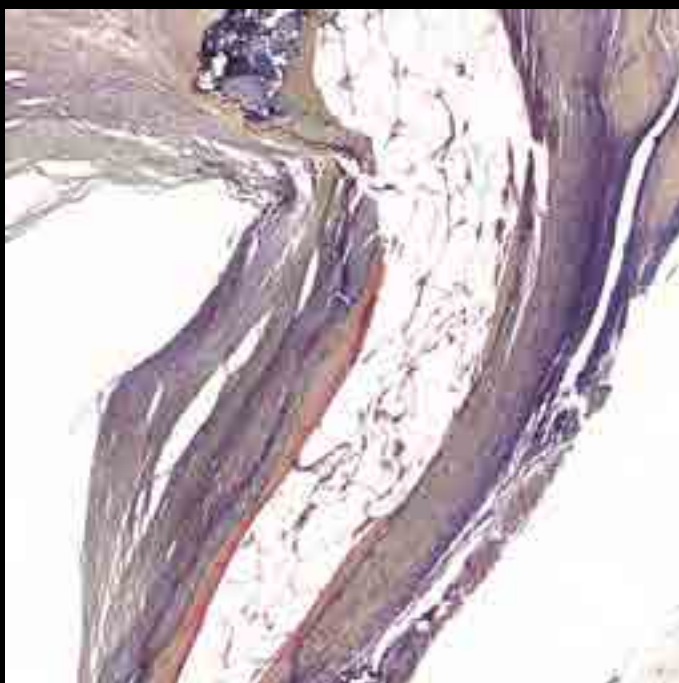
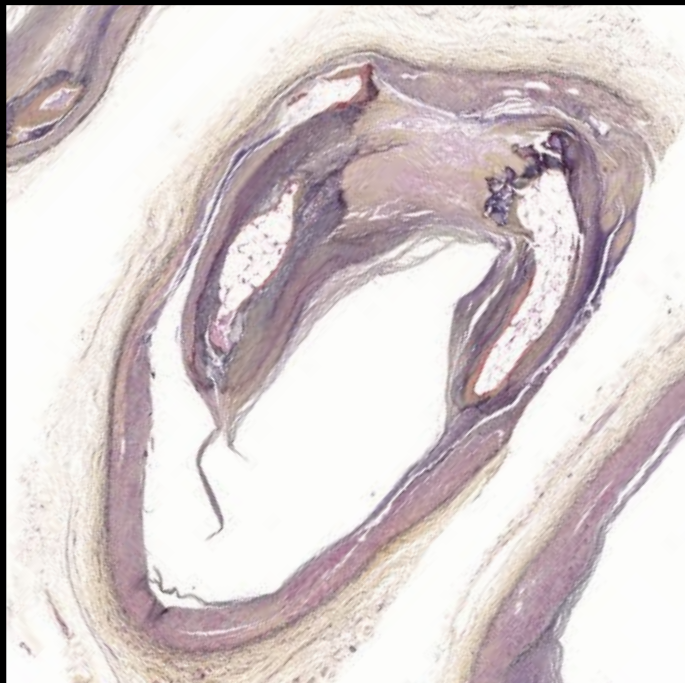
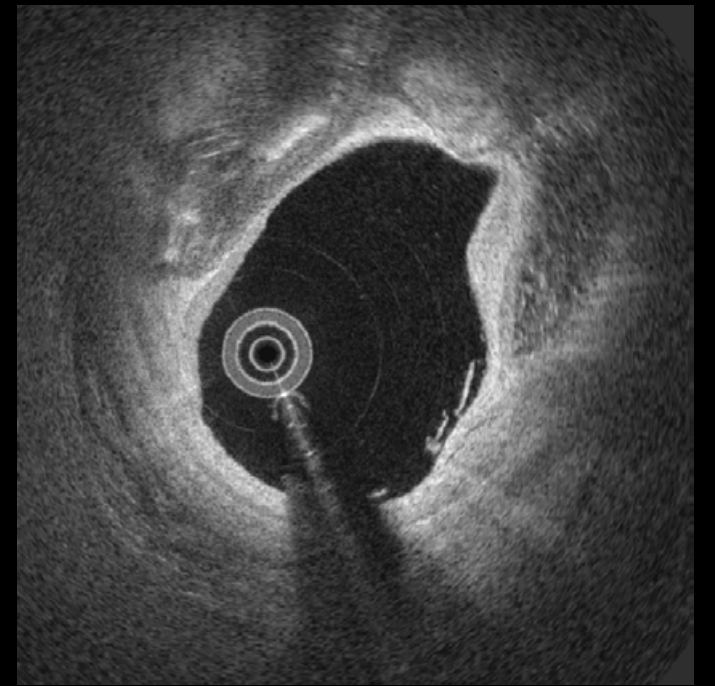
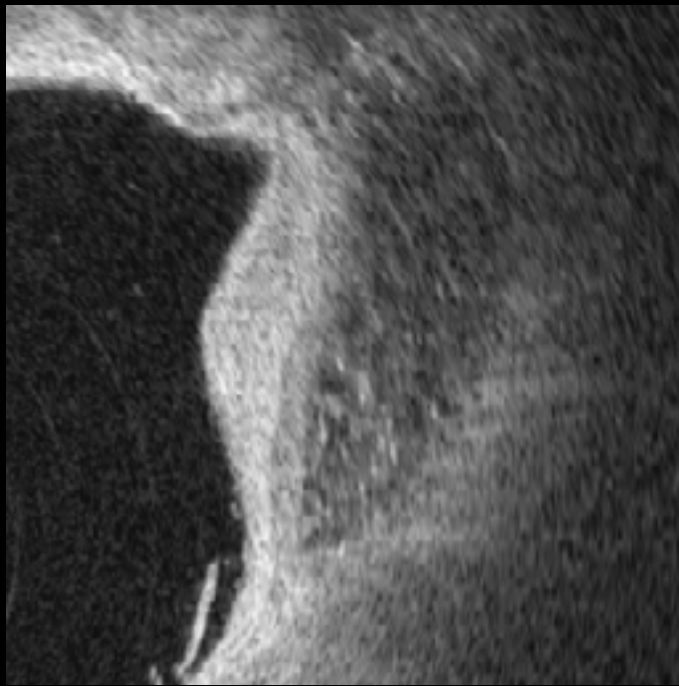
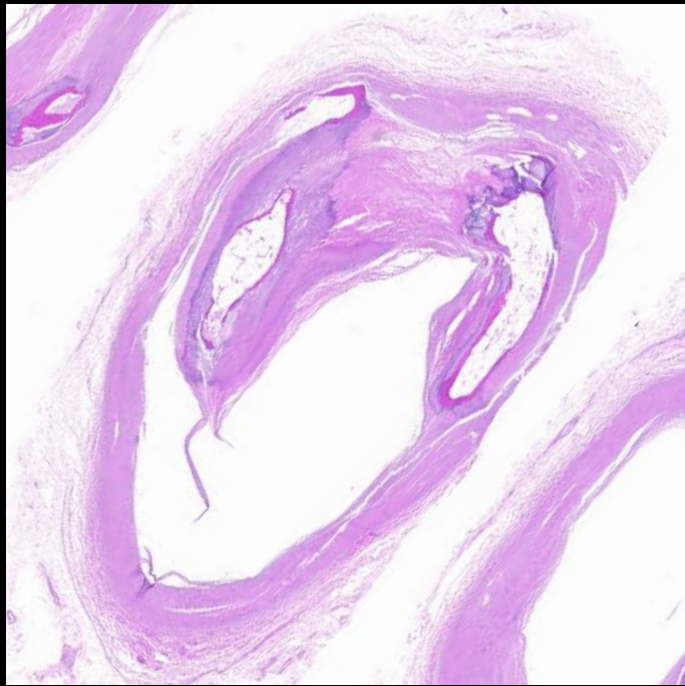
#31



#32

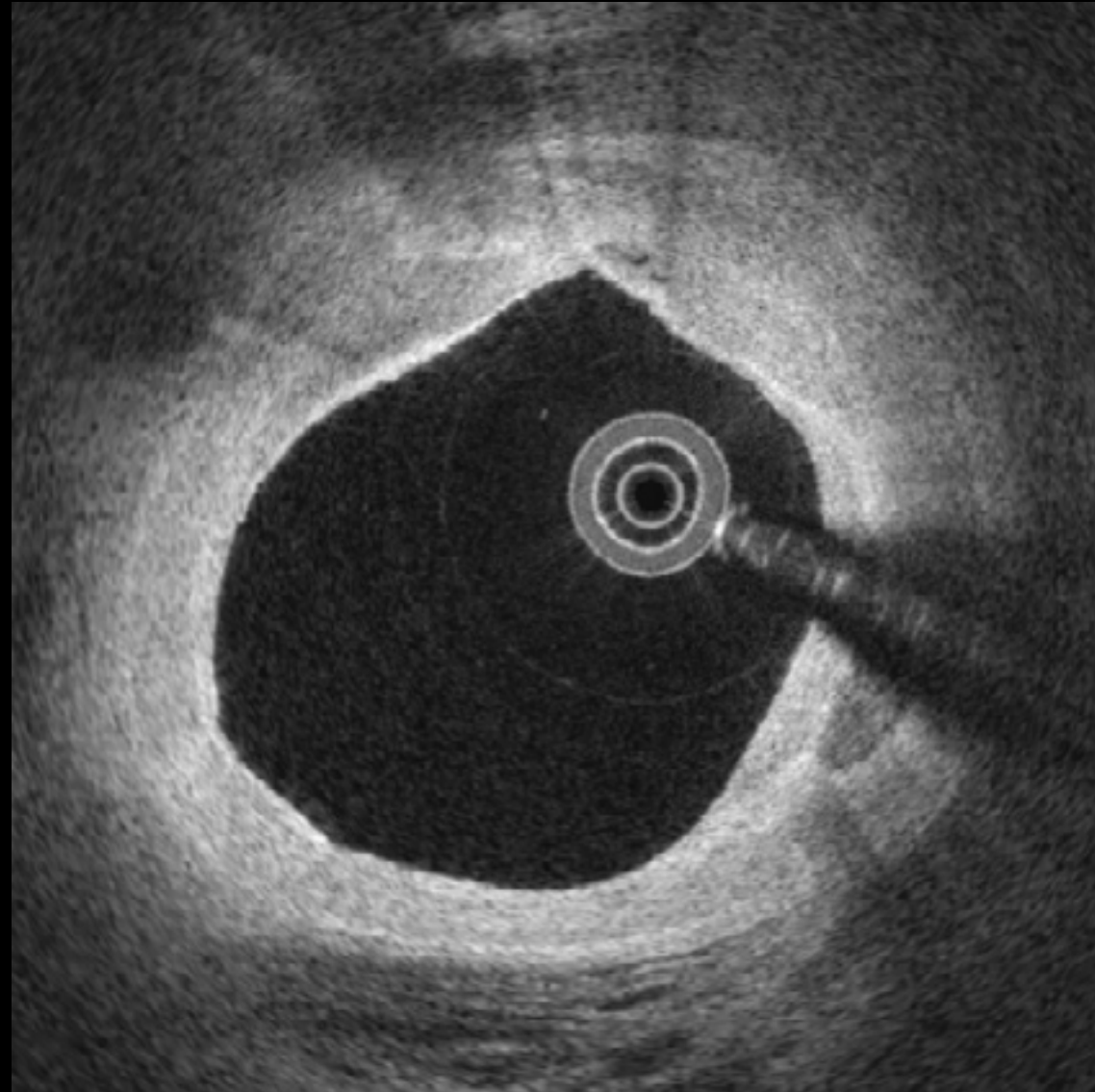


#32

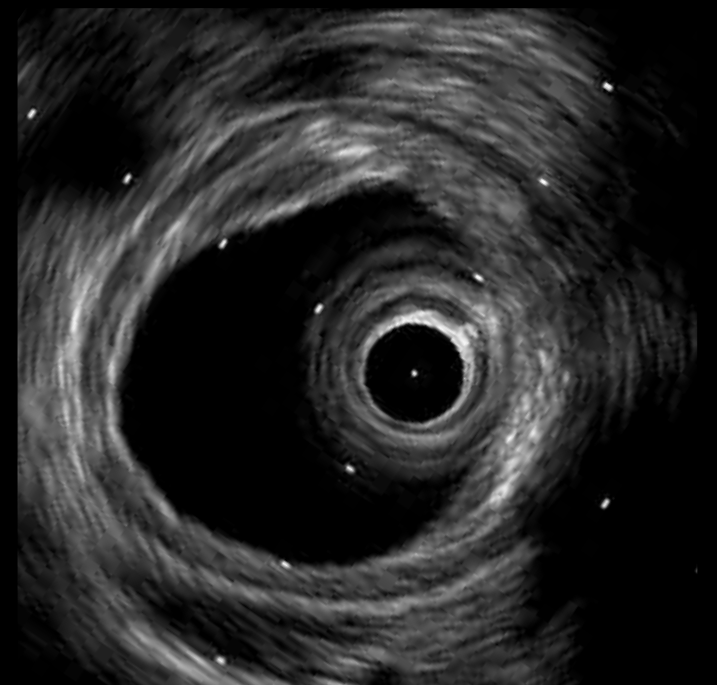
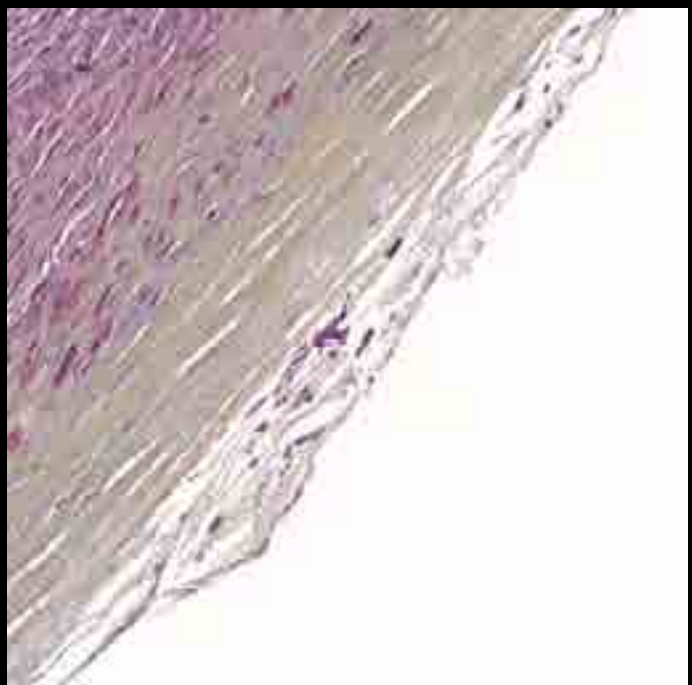
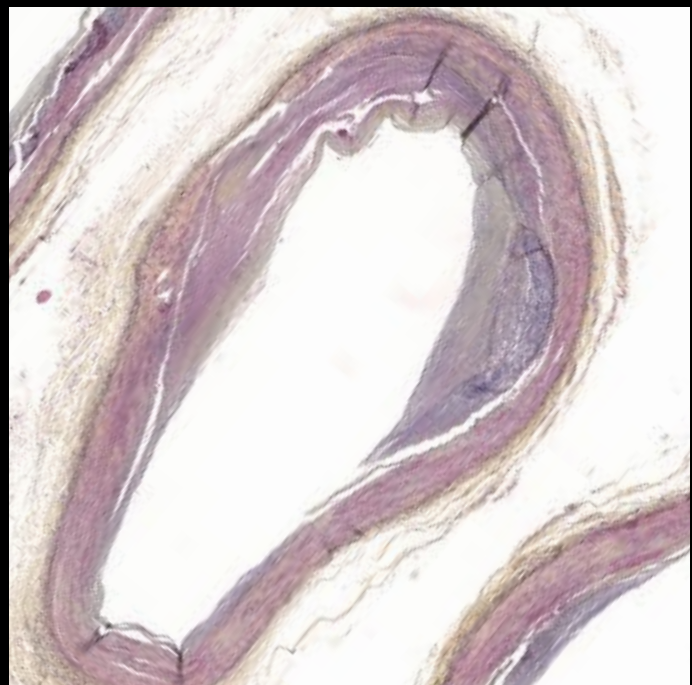
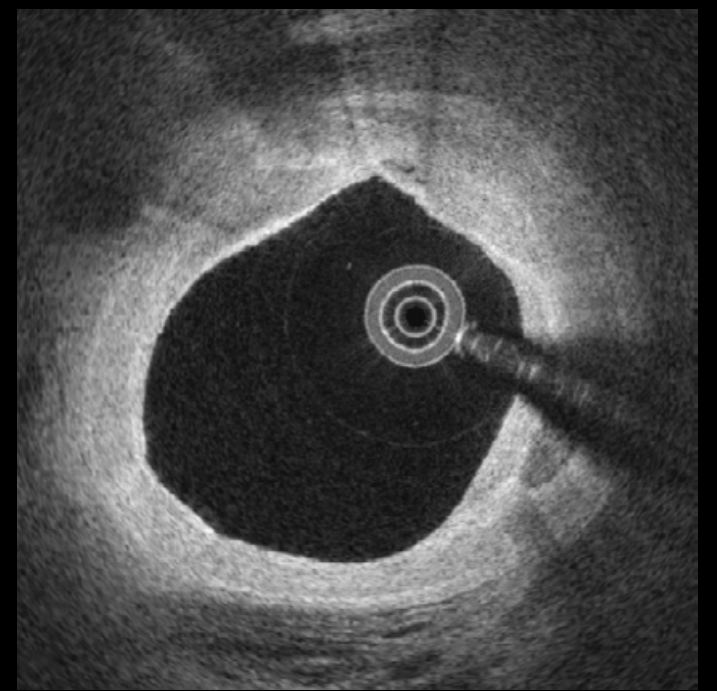
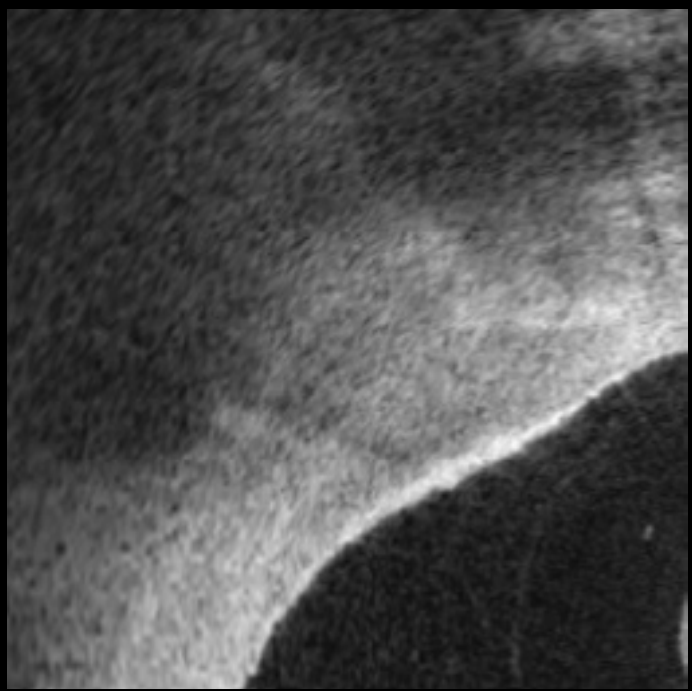
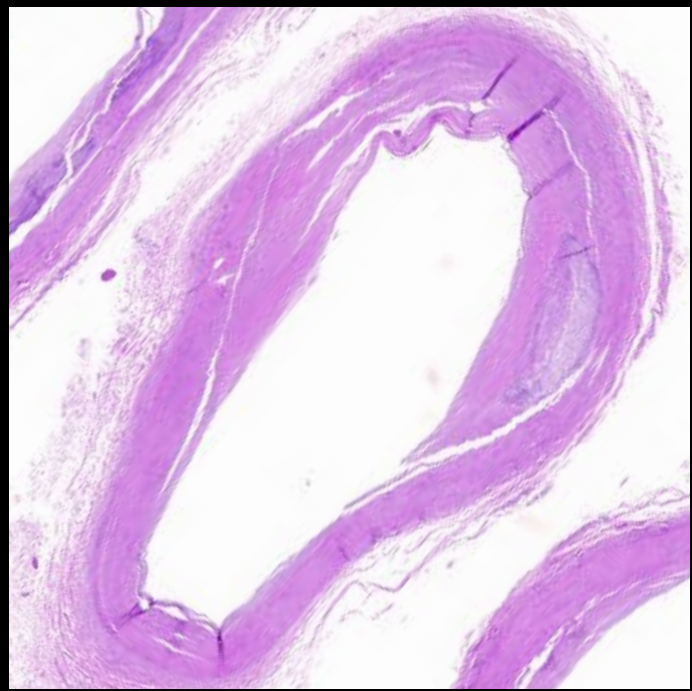


Foamy
Macrophage

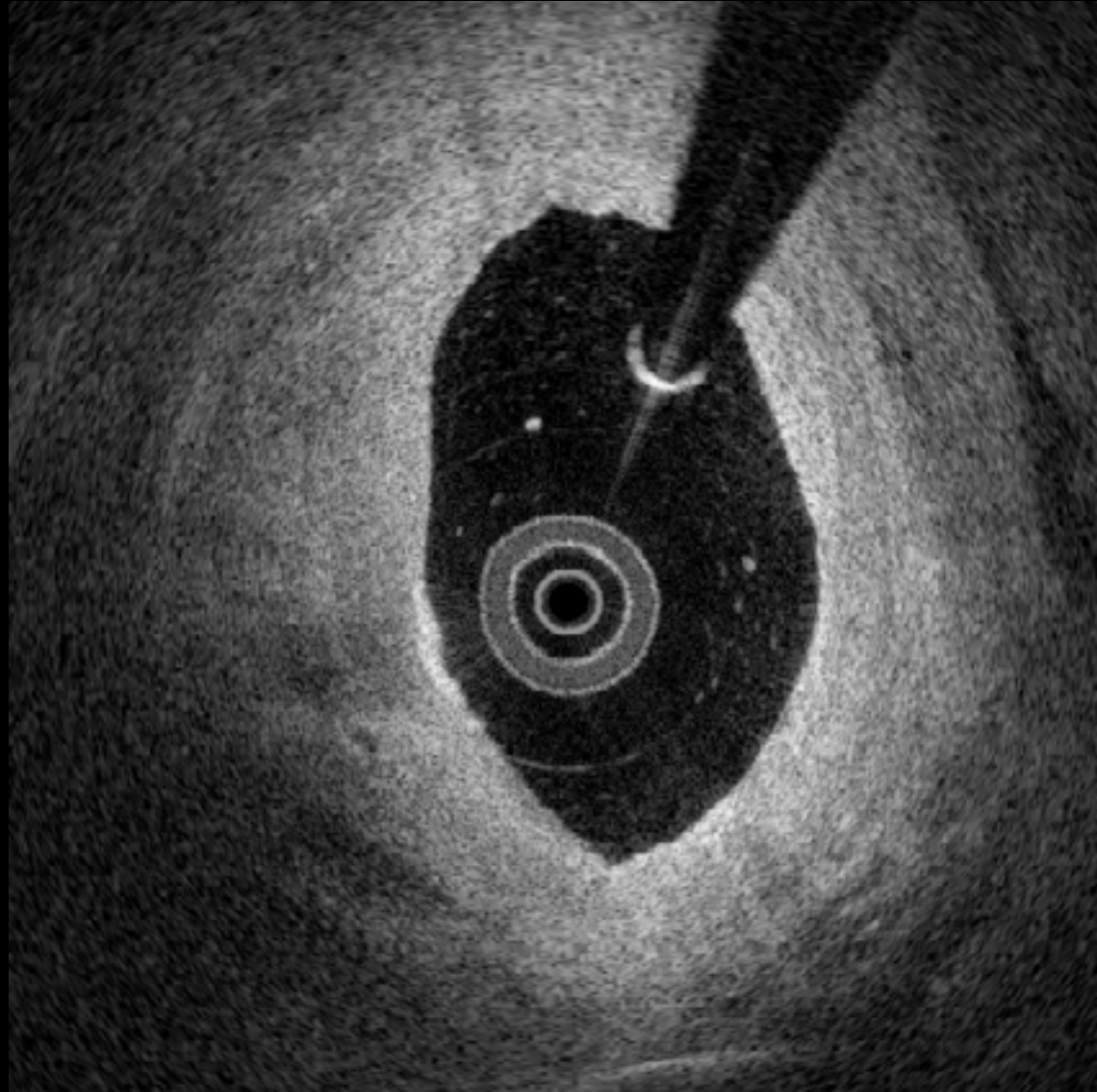
33



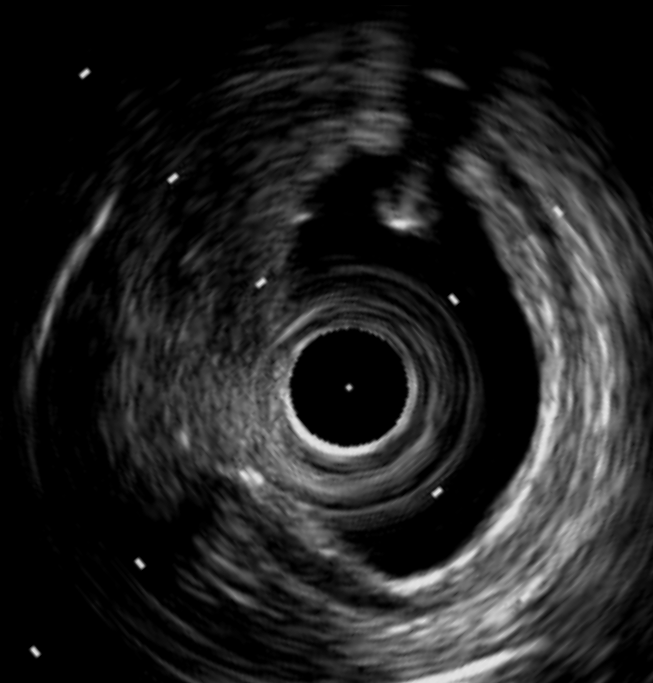
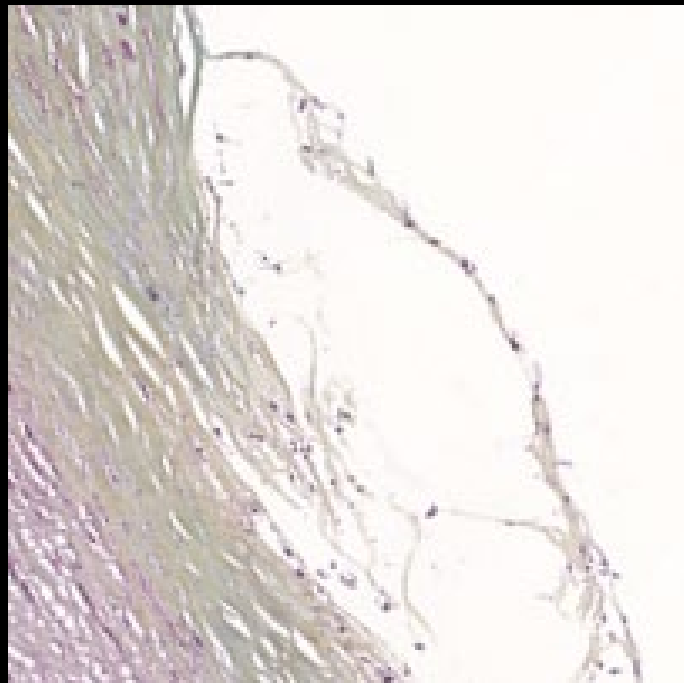
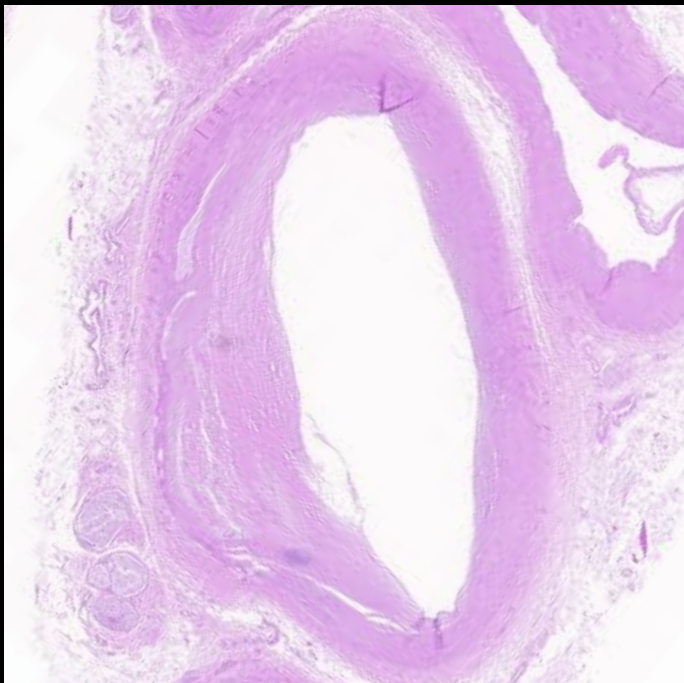
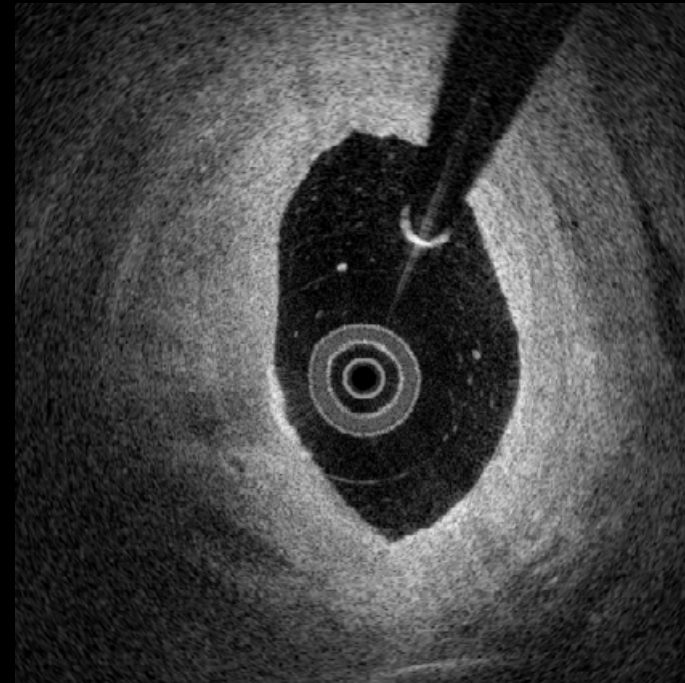
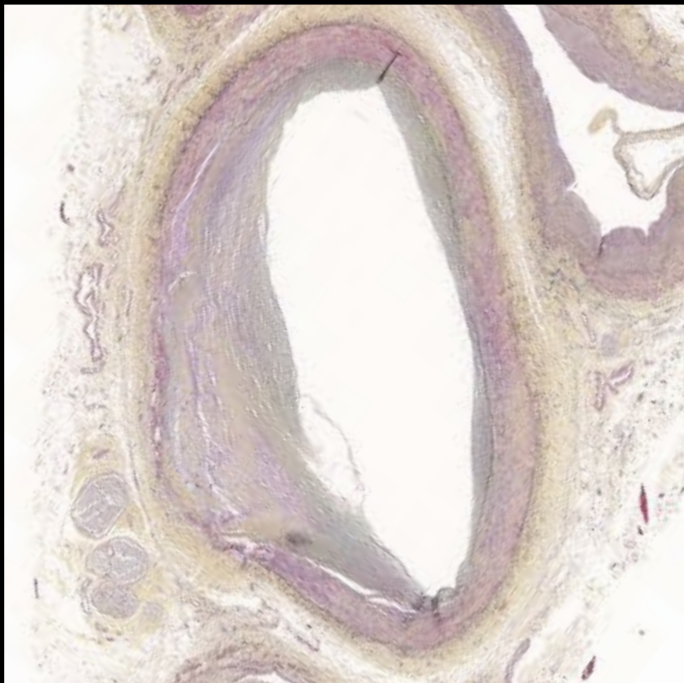
33



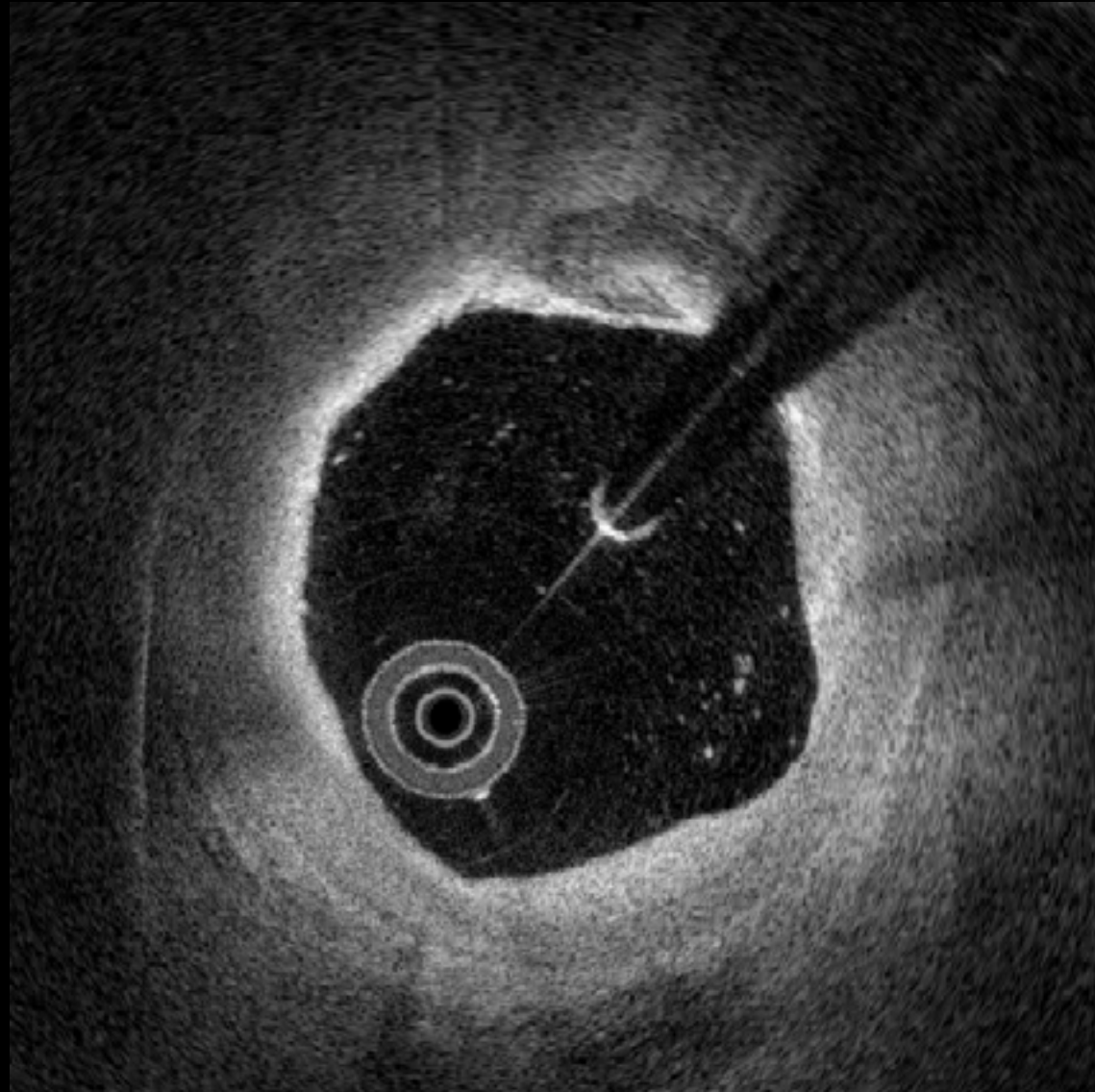
34



34



35



35

